Appendices

Appendix A: Literature citations resulting from the activities of the MMHSRP and our collaborators

Appendix B: A summary of recent MMHSRP research activities

Appendix C: Policies and Best Practices for Marine Mammal Stranding Response, Rehabilitation, and Release

Appendix D: NMFS Policy Directive 02-308 and Procedural Directives 02-308-01 and 02-308-02

Appendix E: Selected MMHSRP Protocols

Hazing

E-1: Supporting information for the Killer Whale Section of the Northwest Wildlife Response Plan, Chapter 9970 of the NWACP (available at: http://response.restoration.noaa.gov/sites/default/files/whale_response.pdf)

Disentanglement

E-2: Large Whale Disentanglement Network Advancement Policies

E-3: Alaska Department of Fish & Game Steller Sea Lion Disentanglement Response Protocol

Diagnostic Imaging

E-4: Monk seal Radiography Safety Requirements and Protocol

Sample Collection and Analysis

E-5: Marine Mammal Necropsy: An introductory guide for stranding responders and field biologists (available at: http://hdl.handle.net/1912/1823)

E-6: Odontocete Salvage, Necropsy, Ear Extraction, and Imaging Protocols (available at: http://csi.whoi.edu/download/file/fid/1616)

E-7: Step-by-step Protocol for Gas Sampling in Marine Mammals (available at: http://www.whoi.edu/cms/files/Gas_Sampling_step_by_step_protocol_172344.pdf)

E-8: Killer whale necropsy and disease testing protocol (available at: http://www.seadocsociety.org/wp-content/uploads/Orca-necropsy-protocol-FINAL-May-15-2014.pdf)

E-9: Handbook for recognizing, evaluating, and documenting human interaction in stranded cetaceans and pinnipeds (available at: http://swfsc.noaa.gov/publications/TM/SWFSC/NOAA-TM-NMFS-SWFSC-510.pdf)

Administration of Medications

E-10: Implementation Strategy for Emergency Vaccination of Hawaiian Monk Seals (DRAFT)

E-11: Right whale sedation protocol for EG 3311

Appendix F: Examples of UASs that have been used by NOAA

Appendix G: Draft Pinniped and Cetacean Oil Spill Response Guidelines (note: when final, this will be published as a NOAA Tech Memo and publicly available. This draft version is provided for PR1 and PR5's use)

Appendix H: MMHSRP Vaccination Plan

Appendix E: Selected MMHSRP Protocols

Sample Collection and Analysis

E-7: Step-by-step Protocol for Gas Sampling in Marine Mammals (available at: http://www.whoi.edu/cms/files/Gas_Sampling_step_by_step_protocol_172344.pdf)

STEP-BY-STEP PROTCOL FOR GAS SAMPLING IN MARINE MAMMALS

First considerations:

- The gas sampling and analysis **cannot** be done if you cut the head first.
- The analysis of the gas samples is time sensitive. Ideally we should run the samples within one week from sampling.
- Samples are affected by low pressure when shipped by aircraft. We have pressure resistant housing to transport the samples that we can ship to you. Please let us know as soon as you have a stranding and you decide to do gas analyses, since the transport of the housing to you, and then the transport of the samples to us is going to take a couple of days, and as explained before, gas samples are time sensitive!
- Gas analyses can be run at Woods Hole Oceanographic Institution, MA, USA, or at the University of Las Palmas de Gran Canaria, Canary Islands, Spain. We strongly recommend that you choose the closest location, so we can run the samples as soon as possible.
- Contact information:

Yara Bernaldo de Quirós Miranda, email: yarabdq@whoi.edu, ybernaldo@becarios.ulpgc.es; office phone number: (USA) +1 5082893651, (Spain) +34 928459711; emergency phone number: (USA) +1 5082745964, (Spain) +34 650485647
Michael J. Moore: mmoore@whoi.edu, +1 5082893228
Antonio Fernández: afernandez@dmor.ulpgc.es, +34 928459712

The following instructions are a summary of the "protocol for gas sampling and analysis in marine mammals" with some updated information. For further information please visit the link to this article:
http://www.nature.com/protocolexchange/protocols/2299

Material you need:

- 2-mL additive free glass tube (Kendall Monoject™ blood collection tube, ref: 301116)
- BD vacutainer® one use holder (ref: 364815)
- Double pointed needle with a rubber barrier on the tube puncture side (BD vacutainer® eclipse™ blood collection needle, ref: 368607).
- Disposable insulin syringes (BD Plastipak U-100 insulin ref: 329651).

PROCEDURE

Dissection

1. Carefully remove the skin and blubber minimizing damage to the major subcutaneous veins.
2. Examine the visible and larger subcutaneous veins for bubbles.
3. Score the amount of bubbles in the subcutaneous veins (see data sheet).
4. Take photos of veins with bubbles.
5. Sample bubbles*[1].

CRITICAL STEP: If pneumothorax is suspected, gas sampling could be done by using the vacutainer®, inserting the double pointed needle in between the ribs*[2]. Do not open thoracic cavity!

6. Open first the abdominal cavity carefully (try not to cut medium to large size vessels).
7. Examine the mesenteric and renal veins as well as the lumbo-caudal plexus for bubbles.
8. Score the amount of bubbles in the lumbo-caudal plexus (see data sheet).
9. Take photos of bubbles within vessels.
10. Sample bubble's content "*in situ*" using the insulin syringes*[1].
11. Look for subcapsular emphysema.
12. Sample the subcapsular (gas) emphysema *in situ* using the vacutainer®*[2] .
13. Sample intestinal gases using the vacutainer*[2]. Preferably take at least three samples from different locations.
14. Open thoracic cavity. If desired, ribs could be disarticulated except the first 3 or 4 cranial ones. These ribs should be cut at 1/3 from the vertebral articulation.
13. Examine the coronary vessels.
15. Take photos of vessels and bubbles.
16. Score the amount of bubbles in the coronary veins (see data sheet).
14. Sample bubbles*[1].
15. Follow up with routine necropsy protocol.

CRITICAL STEP: do not cut any systemic vein or sample organs until this step is reached.

21. Separate the head from the body.
22. You might disarticulate the mandible to have a better access to the pterygoid sacs.
23. Sample pterygoid sacs using the vacutainer®*[2].

CRITICAL STEP: do not open the sinuses before gas sampling.

*[1]**Gas sampling from bubbles in veins**

CRITICAL STEP: place the vein under water whenever possible to avoid atmospheric air contamination.

1. Sample each bubble with a new dispensable insulin syringe (BD Plastipak U-100 insulin)
2. Inject the content immediately into a new vacutainer® each time.
3. Label the vacutainer® with volume recovered and location of the bubble.

CRITICAL STEP: Use one new syringe and one new vacutainer for each bubble.

*[2] **Gas sampling from cavities (intestine, pterygoid air sacs) and gas associated lesions (pneumothorax and subcapsular emphysema)**

1. Couple the vatuainer® plastic holder to the double pointed needle
2. Insert the needle into the cavity
3. Push the vacutainer® against the other end of the needle
4. Leave for a few seconds
5. Remove the vacutainer®
6. Remove the needle

CRITICAL STEP: If any of these steps is not done following this sequence, atmospheric air contamination will occur.

CRITICAL STEP: If steps from 3-13 are not done carefully following this sequence, air contamination will occur.

Storage and transport

1. Store the samples at room temperature and atmospheric pressure.
2. Store blank tubes with the samples; one blank per sample or a minimum of 3 blanks per animal.
3. Samples should be ground transported (please remember that samples are time sensitive!), or shipped by plane inside our pressure resistant housing. Please contact us as soon as possible so we can ship you the housing.

Appendix E: Selected MMHSRP Protocols

Sample Collection and Analysis

E-8: Killer whale necropsy and disease testing protocol (available at: http://www.seadocsociety.org/wp-content/uploads/Orca-necropsy-protocol-FINAL-May-15-2014.pdf)

KILLER WHALE NECROPSY AND DISEASE TESTING PROTOCOL

Updated May 15, 2014

Stephen A. Raverty, DVM, MSc, PhD, Diplomate ACVP[1, 2], Joseph K. Gaydos, VMD, PhD[3] and Judy A. St. Leger, DVM, Diplomate ACVP[4]

[1]Animal Health Center, Ministry of Agriculture, Abbottsford, British Columbia, Canada

[2]Marine Mammal Research Unit, University of British Columbia, Vancouver, B.C. Canada

[3]SeaDoc Society, UC Davis Wildlife Health Center — Orcas Island Office, Eastsound, Washington State, USA

[4]SeaWorld Parks and Entertainment, San Diego, California, USA

NOTE: If you are heading to the field to necropsy a killer whale, please print Appendices XXII-XXVII (pages 66–82) and take them with you!

Live Stranded Killer Whale in Hawaii, Photo courtesy of Jessica Aschettino, NOAA/NMFS/PIRO Permit #932-1489-09

If tissues are not collected at the time of necropsy, the opportunity to appropriately sample the animal is lost.

This protocol is a guide for that collection.

Table of Contents

SIGNIFICANT PATHOGEN ALERT: 3
CETACEAN BRUCELLA: 3
CETACEAN MORBILLIVIRUS: 4
INFLUENZA: 5
SALMONELLA: 5
APICOMPLEXANS: 5
PREVIOUSLY REPORTED PATHOGENS: 6
INTRODUCTION: 7
EQUIPMENT CHECKLIST: 9
LOGISTICS AND NECROPSY RECOMMENDATIONS 10
SAFETY 10
NECROPSY TEAM ROLES 11
EXTERNAL EXAM AND PRE-DISSECTION SAMPLING 11
DECOMPOSITION TABLE: 12
IMAGING CONSIDERATIONS 12
SKELETAL EXAMINATION AND PREPARATION CONSIDERATIONS 13
ACKNOWLEDGMENTS 14
LITERATURE CITED: 14
KILLER WHALE NECROPSY PROTOCOL COMPREHENSIVE KILLER WHALE TISSUE SAMPLE CHECKLIST 18
APPENDIX I: Sample Priorities based on Tissue Condition 24
HIGH PRIORITY SAMPLES: 24
INTERMEDIATE PRIORITY SAMPLES: 25
LOW PRIORITY SAMPLES: 25
APPENDIX II: Pathogens reported in killer whales 27
Table 1: Pathogens detected directly or via serology in killer whales 27
Table 2: Endoparasites identified or suggested by serology in killer whales 28
APPENDIX III: The One Hour Necropsy Protocol 29
APPENDIX IV: Researchers requesting killer whale tissues 30
APPENDIX IVB: Request for marine mammal post-mortem samples 34
APPENDIX V: Permitting concerns and authorities 35
APPENDIX VI: Pathogen and tissue sample list for Polymerase Chain Reaction Studies 36
APPENDIX VII: Marine mammal blubber sampling protocol 38
APPENDIX VIII: Collection of samples for contaminant analysis 40
APPENDIX IX: Collection of samples for biotoxin analysis 41
APPENDIX X: Webpage resources for submission forms 43
APPENDIX XI: Photography instructions and considerations 44

APPENDIX XII: Ancillary imaging instructions 45
APPENDIX XIII: Oil spill concerns and sampling 46
APPENDIX XIV: Considerations and sampling for live stranded killer whales 48
APPENDIX XV: Cetacean ear extraction and fixation protocol 50
APPENDIX XVI: Barotrauma considerations and sampling protocol for gas bubbles 54
Appendix XVII: Dorsal fin measurement and collection request 56
APPENDIX XVIII: Archiving tissue samples 58
APPENDIX XIX: Lesion Description Form 59
APPENDIX XX: NOAA Fisheries NW Region Killer Whale Stranding Protocol 60
***For killer whale strandings in other parts of the world 64**
Appendix XXI: Protocol for examining killer whales for signs of human interaction 65
APPENDIX XXII: Fetal examination and sample management 66
APPENDIX XXIII: Morphometric analysis of stranded killer whales 68
APPENDIX XXIV: Gross pathology data recording form 69
APPENDIX XXV: Checklist - tissues to collect from a Code 2 or 3 killer whale carcass 77
APPENDIX XXVI: Checklist - tissues to collect from a Code 4 killer whale carcass 79
APPENDIX XXVII: Checklist - tissues to collect from a Code 5 killer whale carcass 81
Photo Identifier: 82

SIGNIFICANT PATHOGEN ALERT:

Pathogens acquire significance because they cause harm to humans or animals. Examination of deceased animals has inherent safety concerns. Certain pathogens such as *Brucella* sp., influenza, and arboviruses warrant elevated vigilance and care. Likewise, rapid detection of fatal, transmissible agents that may impact killer whale population health is critical to inform management activity. Chief among these pathogen of concern are *Brucella* spp., cetacean morbillivirus, influenza, *Salmonella* spp., and apicomplexans.

CETACEAN BRUCELLA:

Marine mammal associated *Brucella* spp. that differ from recognized named species within the genus have been increasingly detected in a number of pinnipeds and cetaceans in the United Kingdom, New Zealand, the United States and Canada (Ross et al., 1996; Foster et al., 1996; Nielsen et al., 2001; Van Bressem et al., 2001a). Antibodies to *Brucella* spp. have been identified in post mortem heart blood and in live captured (A73) killer whale with no attendant pathology or clinical disease (Jepson et al., 1997; Raverty et al., 2004).

Infection by *Brucella* has resulted in placentitis and abortion in captive bottlenose dolphins and

blubber abscesses and meningoencephalitis in wild striped dolphins (Ewalt et al., 1994; Gonzalez et al., 2002). There are no *Brucella* species-specific gross lesions. To further resolve the possible contribution of these bacteria to impaired reproductive function and microscopic lesions in stranded killer whales. Attempted *Brucella* species-specific culture and isolation as well as molecular screening should be routinely undertaken with each stranded animal. Tissue samples should include multiple levels of the reproductive tract, brain, lung, spleen, lymph nodes and any gross abnormalitieslesions. To ensure optimum bacterial recovery, samples obtained at the time of necropsy should be shipped overnight on wet ice to a reference laboratory or frozen at -70 C and forwarded for evaluation as soon as possible (Table 2). *Brucella* serology may be considered. However, there are currently no validated serologic tests for killer whales (Gall et al., 2000). If indicated by histopathology, immunohistochemistry with monoclonal or polyclonal antibodies specific to *Brucella* may prove a valuable adjunct to confirm infection and assess the disease processes.
Zoonosis Warning: Marine *Brucella* sp. has infected a laboratory worker after occupational exposure (Brew et al., 1999) and neurobrucellosis with granuloma formation has been documented in two additional individuals with no known history of exposure (Sohn et al., 2003). The virulence of these strains to humans is currently unknown and appropriate public health and safety precautions at the time of necropsy are warranted. The precautions can include gloves, goggles, and a face mask when potentially aerosolizing tissue (such as when using a reciprocating saw).

CETACEAN MORBILLIVIRUS:

Porpoise and dolphin morbilliviruses are antigenically and genetically similar and are now generally considered strains of the same viral species, cetacean morbillivirus (Kennedy, 1998). This virus has caused large-scale epizootics in several odontocetes species (Van Bressem et al., 1991; Duignan et al., 1995; Van Bressem et al., 2001b). Detection of antibodies in a subadult killer whale recently captured in the northwest Pacific Ocean that succumbed to bacterial pneumonia (A. Mironova, per comm.) suggests that killer whales have been exposed to cetacean morbillivirus. Although no morbillivirus antibodies or gene sequences have yet been detected in stranded cetaceans in the temperate northeastern Pacific Ocean, this virus is likely endemic in multiple small cetaceans from around the world (Van Bressem et al., 2001b). Because of the virulence of this virus and its potential to cause large-scale mortality in small populations, morbillivirus should be ruled out during all killer whale necropsies. Continued surveillance for antibodies to cetacean morbilliviruses in antemortem serum or post mortem heart blood samples by indirect enzyme linked immunosorbant assay (iELISA) or virus neutralization and attempted virus isolation are strongly recommended.

Cetacean morbillivirus is pantropic (infects a variety of cell types) and potential gross necropsy findings include skin ulcerations, stomatitis, pneumonia, and generalized signs of sepsis such as edema of internal organs and accumulation of serosanguinous fluid in the pleural and peritoneal cavities (Lipscomb et al., 1994). Gross lesions are not specific of morbillivirus infection but microscopic lesions are highly characteristic (Domingo et al., 2002). Microscopic lesions commonly seen with morbillivirus infection such as syncytia and acidophilic inclusions in cytoplasm and nuclei of epithelial cells can be widespread, focal, or obscured by severe necrosis caused by opportunistic bacterial and fungal infections. Microscopic examination and laboratory testing are essential to confirm morbillivirus infection. The tests used include immunohistochemistry, reverse transcriptase polymerase chain reaction (RT-PCR), and virus isolation on Vero cells or bovine fetal lung cells (Domingo et al., 1990; Van Bressem et al.,

1991; Barrett et al., 1993; Van Bressem et al., 1999; Saliki et al, 2002). Potential sequelae to cetacean morbillivirus infection include opportunistic bacterial and fungal infections, as well as toxoplasmosis (Lipscomb et al., 1994; Schulman and Lipscomb, 1999). These viruses are not likely a pathogen of concern for humans – but they represent a potentially significant health threat to killer whale populations.

INFLUENZA:

The detection of an influenza virus (H3N8) in the harbor seals stranded in the Northeastern United States in 2011 has renewed interest and concern regarding the potential risk of exposure and infection of other marine mammal species, terrestrial animals, birds and humans who may come into contact with carrier animals. To date, histopathology of stranded killer whales throughout the northeastern Pacific has not detected microscopic lesions consistent with infection by influenza and no virus has been identified by reverse transcriptase polymerase chain reaction in screened cases. However, the recent report of West Nile Virus in a display killer whale (St. Leger et al., 2012) suggests that orca may be susceptible to a broader array of viral pathogens than previously appreciated. Influenza from cetaceans could present a zoonotic concern and appropriate personal protective equipment (especially respiratory protection) should be utilized to reduce the likelihood of infection.

SALMONELLA:

Post mortem examination of an offshore neonate stranded in central California and an adult female killer whale in Hawaii did not reveal gross evidence of septicemia or localized bacterial infection. However, microscopic review of sampled tissues from the neonate disclosed inflammation of the umbilicus and multisystemic inflammation due to *Salmonella newport. Salmonella muenchen* was recovered from the adult female; the lack of associated inflammatory infiltrate within examined tissues suggested an asymptomatic carrier. There are over 2,200 recognized serovars of *Salmonella. Salmonella newport* is an emerging human health concern and is among the most common isolates from dairy cattle. It is important to note that these bacteria may directly infect people and can be carried on clothing, boots, or equipment to contaminate other areas. Thorough hand washing and disinfection of necropsy equipment should limit the risk of human and animal exposure.

APICOMPLEXANS:

The advent of molecular screening and gene sequencing has greatly enhanced our ability to detect a variety of disease agents, including tissue cyst forming protozoal parasites, such as those of the Apicomplexa. In marine mammals these include *Toxoplasma gondii*, *Sarcocystis neurona*, *Sarcocystis* spp, *Neospora caninum* and *Neospora* spp (Miller, 2008; Colgrove et al., 2010; Gibson et al., 2011). Representatives of this group of protozoa are of increasing concern due to potential land to sea transmission (Miller et al., 2004, etc.). Sexual reassortment has resulted in the emergence of hypervirulent clones. Although these pathogens have been implicated in sporadic mortality in near and off shore cetaceans, significant losses have been incurred historically in pinnipeds and otters. These parasites are associated with meningoencephalitis and transplacental infections or placentitis. Individual and dual parasite infections of *Toxoplasma gondii* and *Sarcocystis* spp. have been detected in a killer whale; however, the contribution of these parasites to strandings has not yet been resolved. Efforts are ongoing to screen stranded killer whales for possible infection. Subsequent genotyping is routinely undertaken to determine a potential source of exposure.

PREVIOUSLY REPORTED PATHOGENS:

Reported pathogens from free-ranging or captive killer whales (Gaydos et al., 2004) are growing in number. Implementation of comprehensive necropsies and ancillary diagnostics has significantly contributed to this (Barbieri et al., 2013). Increasing knowledge of recognized pathogens and the potential contribution to clinical disease greatly enhances our understanding of killer whale morbidity and mortality. Please see Appendix II for reported infectious disease pathogens (Table 1) and endoparasites (Table 2) identified in killer whales.

INTRODUCTION:

This protocol was first established in 2005 with goals to:

1. Provide guidelines for more comprehensive necropsies and disease testing to improve our knowledge about diseases of killer whales (*Orcinus* spp.)
2. Standardize screening to facilitate retrospective natural history and disease epidemiology studies.

In the past seven years, this protocol has greatly facilitated and enhanced killer whale examinations in the Northeast Pacific region, and we hope that this revised version will reflect scientific advancements in disease screening, heighten awareness of health concerns, and increase the number of complete postmortem standardized necropsies performed on killer whales.

The project was sponsored by the U.S. National Oceanic and Atmospheric Administration (NOAA Fisheries) in response to the limited information known about diseases of free-ranging killer whales. This information is critical to understanding how disease might impact the recovery of small declining killer whale populations, such as the southern resident killer whales. Historic estimates of this population were more than 200 whales until the mid- to late-1800's: the most recent census indicates 80 individuals. Since the start of killer whale photo-identification in 1974, the population has had several periods of growth and decline, including a 17% reduction (mean annual decline rate of 2.9%) between 1996 and 2001, prompting the petition and successful listing under the US Federal Endangered Species Act. Since 2001, the population grew to a high of 90 individuals in September 2006. The population has fluctuated. AS of September 2013, it totaled 81 individuals. The Recovery Plan for Southern Resident killer whales (NMFS 2008) recommends development of protocols for responding to stranded killer whales and investigations of dead killer whales to inform recovery, including necropsies following the 2005 protocol. This updated protocol contributes to implementation of these actions and will contribute to gathering important knowledge about the health of the whales and the threats they face.

A retrospective evaluation of stranded killer whales reported an average of seven to eight dead or beach cast killer whales around the world annually, making each killer whale stranding an important opportunity to learn more about the biology and health status of these animals (Barbieri et al., 2013). We hope killer whale researchers and responders around the world will use this protocol to increase information garnered from postmortem examinations.

The objectives of this revised standardized necropsy and disease testing protocol are:

- Facilitate more comprehensive and systematic killer whale post mortem examinations
- Prioritize morphometrics and tissue sampling when complete necropsies are not feasible or in cases of more advanced autolysis
- Establish baseline patterns of morbidity and mortality in killer whales to facilitate retrospective evaluation of temporal and geographic differences in killer whale health
- Ascertain the contribution of contaminant and heavy metal accumulation to killer whale health
- Improve reporting of human interactions (blunt force and sharp injury trauma)
- Introduce methods to investigate potential sonar or seismic related strandings
- Develop protocols to conduct neonatal killer whale examinations
- Enhance photo documentation of gross abnormalities or lesions
- Identify resources for information regarding climatic and oceanographic factors, which may contribute to and facilitate back tracking of environmental factors associated with strandings
  Provide contact information and shipping addresses for priority samples required for diagnostics and long term research efforts
- List protocols and contacts in the event of a catastrophic oil or other noxious chemical spill
- Through sampling requests, prioritize key organs to provide additional insights into the natural history and biology of wild stranded killer whales through sampling requests

A revised and expanded necropsy and sampling protocol is presented in the following text and relates specifically to North America. While the testing is focused on North American resources, the testing is universal and this protocol can be implemented globally. If resources are available, it is recommended that all killer whale necropsies follow this protocol. If your facility has appropriate tissue fixatives (formalin), a freezer and access to a microbiology laboratory, most of the listed tests should be readily accomplishable.

EQUIPMENT CHECKLIST:

Note: This equipment checklist represents an ideal situation. Post- mortem exams can be completed with less equipment.

1. Morphometrics data sheet, gross necropsy form, human interaction form, and sample collection checklist
2. Standard necropsy instruments: multiple scalpel handles, scalpel blades, scissors, forceps, knives (3-10), knife sharpener, and 1-3 cutting boards, if possible in secure pack
3. Flensing knives (1-3) and hooks with appropriate sharpening tools, chain saw, axe, or reciprocating saw to cut through the cranium, chest or vertebrae. Hammers, chisels and handsaws
4. Retractors and gaff hooks of various sizes and shapes. Self-retaining retractors with one or two movable arms mounted on a slide bar are most useful
5. Sterile instruments, propane torch/gas burner, and searing spatula for sterile culture collection
6. Isopropol alcohol for flaming instruments
7. Flashlights and/or head lamps with extra batteries and light bulbs
8. Generator and flood lights with extra bulbs and fuel/gasoline (for night time exams)
9. 10% neutral buffered formalin (1- 10L) in wide-mouth spill-proof containers with screw-on lids. Extra-large, wide-mouth plastic storage bags are useful to place formalin containers in them along with absorbent cloth to prevent/limit spills
10. 4% buffered glutaraldehyde or suitable EM fixative (10-20 mL in multiple small vials)
11. 20% DMSO/saturated saline solution for genetic analysis (5mL) in a screw cap tube.
12. RNA-later for samples for future molecular analysis (5-20 mL split in multiple small vials)
13. Covered sealable containers (from vials to garbage cans) for sample collection, including ice chest, dry ice and if possible liquid nitrogen
14. Culture swabs, sterile urine cups, large screw-cap vials, glass slides
15. Serum tubes for fluid, blood and urine collection
16. Aluminum foil, Teflon bags, and plastic bags/Whirl-paks for freezing tissues
17. Paper for notes, labels (e.g. laundry tags with metal clips) and waterproof (Sharpie®) marking pens and pencils (for labeling specimens that will be immersed in fixatives).
18. Tape measure (metric), at least 20 meters long and small 12-15cm or 30 cm plastic rulers
19. Hoist/crane (for heavy organs), g/kg scales (for small tissues) to record organ weights
20. Coveralls, aprons, boots, gloves, caps, masks, protective eye and head gear
21. Accessible water supply with a large hose (for wash down and clean up)
22. Digital camera, GoPro camera, extra batteries with additional memory cards
23. Labels to identify digital images
24. First aid kit
25. Multiple plastic tarps, 10 meters.
26. Strong chain or rope, at least 20 meters.
27. Plastic tape and pylons to cordon off necropsy site.
28. Ice chest or cooler with ice to hold fresh samples
29. Garbage bags, dish soap, disinfectant, scrub brushes, paper towels for clean-up
30. Signs: WARNING – PUBLIC HEALTH HAZARD – DO NOT ENTER!

LOGISTICS AND NECROPSY RECOMMENDATIONS

From a logistical perspective, advanced development of contingency plans will greatly facilitate identification, reporting, communication, recovery, necropsy and disposal of stranded animals. Key individuals for a killer whale stranding response should be identified and contact information provided to responsible government agencies, regional stranding coordinator, local aquarium facilities, and whale watching representatives and stranding networks. For example the West Coast Marine Mammal Stranding Network has a protocol for initial communications and considerations for killer whale stranding response, including identifying logistics for performing necropsies (Appendix XX).

If a killer whale strands in an inaccessible or remote site, or is identified floating in offshore areas, efforts to recover the animal and relocate by boat to a more accessible site are strongly recommended. If the animal can be re-floated, this may be accomplished by a large rope or chain secured around the peduncle or immediately behind the pectoral flippers and towed by a suitable vessel. To limit drag, the two front flippers should be tied together and maintained out of the water. To facilitate the post mortem examination, the animal should be positioned in lateral recumbency and secured ashore at high tide with exposure of the carcass attained with ebb flow. As tidal changes may limit the duration of the examination, use of heavy equipment (cranes, backhoes, hoists) and flatbed trucks to transport the animal to a more secure facility or a diagnostic laboratory may be considered. These animals may weigh up to 4000-6000 pounds and an appropriate vehicle should be employed. If the carcass is moved by truck, the vehicle should be weighed at a commercial weigh scale before and after transport to obtain the body mass of the carcass.

Should the animal require euthanasia, consultation with the regional stranding coordinator and a marine mammal veterinarian is required. Ante-mortem blood samples should be collected and appropriately stored for later clinical pathology (hematology and clinical chemistry), hormone analysis, serology, archiving, immune function and ancillary diagnostic and research investigations. With a fresh dead animal (code 2), post mortem blood may be collected from the tail flukes, dorsal fin, axillary artery, or heart. Even in animals with advanced states of decomposition, efforts to harvest tissues for histopathology, contaminants, genetics, parasitology, and molecular studies should be undertaken. Skeletal remains from animals in stages of severe decomposition (code 5) can also prove invaluable to ongoing studies in killer whale natural history.

SAFETY

Safety of the public and individuals involved with the post-mortem examination is a prime consideration. With any field necropsy, there is a risk of human exposure to potential zoonotic pathogens as well as interference with inappropriate public involvement. Use of face masks, protective eyewear and gloves is recommended. In areas with high public exposure, access should be restricted by pylons, tape or rope and use of law enforcement or fisheries officials may be warranted.

NECROPSY TEAM ROLES

To facilitate the flow of the post mortem examination, team members should be identified and assigned to specific tasks before the necropsy is initiated. A lead pathologist or prosector should be designated and individuals appointed to complete data entry, process research samples (Appendix IV), label and record diagnostic material (Appendix I), document lesions and observations with photographs, liaise with the media or undertake additional tasks as necessary. Appropriate measurements (Appendix XXIII) should be recorded by designated team members and photographs of the dorsal fin and saddle patch, eye patches, and any other potential identifying features obtained before the necropsy is initiated (Appendix XXIV). A digital still camera or GoPro® should be used to record details of the post-mortem examination.

Consider forming two teams to increase data and tissue collections. One team can collect morphometrics while another team collects external photos and documents external lesions. If you have 2 lead prosectors, there can be a head and abdomen team until they meet in the middle.

Consider organizing a single sampling station just away from the necropsy. ALL tissues are harvested and then sent to sampling table for subsampling. The data sheets and sampling team leader are stationed there making sure ALL protocols are filled. In this way a single block of liver harvested from the whale is delivered to the sampling table and is subsampled to fill all protocols and requests. Specific sample vials (usually fluids) are brought to the carcass to be filled before the organs are excised.

EXTERNAL EXAM AND PRE-DISSECTION SAMPLING

In the case of live strandings, ante-mortem blood samples should be collected and appropriately stored for later clinical pathology (hematology and clinical chemistry), hormone analysis, serology, archiving, immune function and ancillary diagnostic and research investigations. With a fresh dead animal, post mortem blood may be collected from the tail flukes, dorsal fin, axillary artery, or heart. Even in animals with advanced states of decomposition, efforts to harvest tissues for histopathology, contaminants, genetics, parasitology, and molecular studies may be undertaken. Skeletal remains from animals in stages of severe decomposition can also prove invaluable to ongoing studies in killer whale natural history.

External examination and photo documentation of the eyes, mouth, blowhole, skin, mammary glands, genital slits and anus should be performed prior to cutting the animal. The dorsal fin and area immediately around the base of the fin should be examined for evidence of any prior attachment of LIMPET satellite tags (Andrews et al. 2009). Signs of human interaction should be recorded (Appendix XXI). Once the external examination and tissue sampling (swabs, cytology and tissues) has been completed and lesions documented (i.e. by photography and description), proceed with the dissection.

DECOMPOSITION TABLE:

Code 1	Live stranded	Self-evident
Code 2	Fresh dead	Skin firm, organs fresh
Code 3	Moderate decomposition	Body swelling, skin deterioration, often advanced scavenging, organs red and soft but discernible
Code 4	Advanced decomposition	Organs difficult to clearly discern, skin sloughing, often swollen and expelled GI tract or repro organs
Code 5	Severe decomposition	Skeletal remains with associated soft tissue remnants

The post mortem approach will be determined to some extent on the animal's position, accessibility, lesions and other factors. Although cosmetic necropsy may be requested to preserve the skeleton intact, this procedure should not compromise or impede appropriate tissue collection.

IMAGING CONSIDERATIONS

Prior to the dissection, ancillary imaging such as radiographs, Computed Tomography (CT) examination, and Magnetic Resonance Imaging (MRI) should be performed if feasible (Appendix XII). In general, code 2 specimens weighing less than 225 kg (500 pounds) are candidates for whole body imaging. Animals up to 1000 kg (2200 pounds) are candidates for partial (head, spine, flipper) body imaging. Decomposition will lead to gas production associated with bacterial putrefaction. However, even carcasses with advanced decomposition are good candidates for CT to evaluate skeletal condition and document complex bone changes. CT imaging of carcasses or heads is the preferred manner of examining for bones fractures, barotrauma and bullets. **If gunshot is a concern, MRI evaluation is strongly contraindicated.** Consultation with local radiology specialty veterinary clinics or human hospitals prior to imaging studies is recommended.

If the animal is too large for standard imaging, the head can be removed following morphometrics and the external examination. The head can then be transported quickly to a local facility for imaging. NOTE: do not freeze the head without first harvesting the brain and eyes.

DISSECTION

With the animal in lateral recumbency(laying on its side), a curvilinear full blubber thickness incision may be made from the caudal limit of the anus, along the dorsolateral aspect of the abdominal and thoracic cavities, terminating at the level of the rostral limit of the mandibular ramus. Perpendicular cuts from the dorsum to the mid-abdominal region will facilitate reflection and removal of the skin and blubber and exposure of the underlying tissues. The lateral skin and blubber can then be reflected with metal retractors from the underlying musculature *en masse*, or divided into suitable 0.5-1.0 m portions and removed. Excised tissues should be removed from the dissection area and placed on a plastic tarp to facilitate clean up and limit environmental contamination. Tissue lists for diagnostic and research evaluation are listed in appendices (I and II).

The abdominal musculature may be incised along the costochondral arch and dorsal limit of the abdominal cavity, then reflected laterally or ventrally to expose the abdominal viscera. The

diaphragm should be assessed, and if intact, incised and deflated to exclude pneumothorax. If a cosmetic post-mortem is requested, the ribs may be detached at the costosternal junction and reflected, or alternatively a chain or reciprocating saw may be employed to remove the thoracic wall. It is important that protective eye wear or face shields be employed by the operator and prosectors. The tongue may be exteriorized by incision of the blubber and skeletal musculature along the entire length of the medial aspect of the mandibles and then reflected ventrally. If feasible, the lung, heart, larynx, trachea and esophagus, and tongue (pluck) should be removed to a tarp for thorough evaluation. With larger animals, dissection of thoracic viscera *in situ* may be warranted. The head may be detached by dissection of the atlanto-occipital articulation and the skin overlying the dorsolateral aspect of the nape and cranium removed. This exposure will facilitate removal of the dorsal aspect of the skull by either chain or reciprocating saw and exposure of the brain. It is important to evaluate the entire length of the vertebral column to assess possible vertebral fractures or subluxations associated with boat strikes or other trauma; a representative portion of spinal cord should be recovered from the cervical, mid- thoracic, thoracolumbar and lumbar regions.

Due to the importance of the reproductive organs in disease screening and assessment of reproductive status, recover and completely excise the reproductive tract for evaluation. As with other organ systems, decomposition and physical characteristics will determine the best sampling plan for this system.

The mesenteric stalk should then be identified, evaluated for lesions, then transected to facilitate removal and evaluation of the abdominal viscera. The viscera should be placed on a separate tarp to that of the thoracic contents to limit cross contamination. The entire length of bowel should be detached from the mesenteric attachment and opened for visual inspection by incising along one side of the mesenteric border. The stomach should then be incised along the greater curvature and the gastric contents recovered and appropriately packaged and labeled. Samples will be partitioned for a variety of ancillary investigations (Appendix I). The remaining internal viscera should be evaluated by routine or conventional diagnostic protocols and appropriate research and diagnostic samples harvested and labeled.

With suspect sonar related strandings, arrangements should be made for CT scan of the entire head or ears and close evaluation of the larynx should be undertaken for evidence of submucosal hemorrhage. If the CT is not conducted prior to the necropsy, the head and ears can be collected and scanned at a later time. EARs can also be extracted and fixed for analysis (Appendix XV). Samples of peribullar adipose tissue should be collected into 10% neutral buffered formalin for histopathologic evaluation. Note: decomposition to code 3 can produce intravascular and parenchymal gas bubbles. These are distinguished from bubbles associated with acoustic trauma based on tissue freshness and associated lesions such as pulmonary and peribullar fat hemorrhage and damage to the ear bones. Appendix XVI provide guidance for gas bubble sampling.

SKELETAL EXAMINATION AND PREPARATION CONSIDERATIONS

Postmortem investigations should involve review of both soft and hard tissues. Examination of bones for malformations, degenerative changes, fractures, inflammation and masses is critical to a thorough understanding of the health issues affecting an individual killer whale. Bones are most commonly evaluated through diagnostic imaging (radiographs and CT exams) and at the gross exam with bone exposure by flensing. Due to the large size of killer whales and the

difficulty in soft tissue removal, a thorough examination typically requires either maceration of tissue, or soft tissue removal via beetles or decomposition through burying. This step is often critical to evaluate the skeleton and obtain a clear diagnosis.

Bone fissures, cracks and fractures can occur ante- or postmortem. Because of this, presence or absence of associated hemorrhage, reactive change along bone margins or muscle damage in the vicinity of breaks should be specifically noted. Boat strike can occur post-mortem. Bone scrapes likewise, can occur as the direct result of trauma or on exposed bones tossed against rocks and sand postmortem. Again, ancillary findings help to determine the significance. Lastly, fracture patterning and the morphology of fractured edges, e.g. presence of blood clots may substantially contribute to the diagnosis of ante-mortem trauma.

Cleaned skeletons also have value to museums, researchers, and educational institutions. Once the examination is completed, please contact Dr. Brad Hanson or Dr. John Ford (see Appendix IIB) for options for long-term curation.

APPENDICES, CONTACTS, AUTHORIZATION AND PERMITS

An equipment list is attached (page 10) and diagnostic, as well as research, tissue lists are provided in Appendices I and II. With oil spill and forensic cases, chain of custody forms should be appropriately completed and forwarded with tissue samples (Appendix XIII).When tissues samples are forwarded to a reference lab or contact individual outside the country of origin, appropriate authorization and permits from the lead agency such as US Fish and Wildlife (for CITES) and NOAA/NMFS (for MMPA) are required (see Appendix V).

ACKNOWLEDGMENTS

We wish to thank the numerous people who contributed content to this document. We offer special thanks to stranding coordinators, stranding responders, and First Nations peoples who have made and continue to make the enactment of these investigations a reality. Funding for this project was provided by the U.S. Department of Commerce National Oceanic & Atmospheric Administration. In-kind support also was provided by the SeaDoc Society, a program of the Wildlife Health Center, School of Veterinary Medicine, University of California, Davis, Sea World Parks and Entertainment, and the Animal Health Center, British Columbia Ministry of Agriculture. Specific thanks are due to Lynne Barre, Kathy Burek, John Ford, Sal Frasca, Justin Greenman, Michael Grigg, Frances Gulland, Brad Hanson, Aleria Jensen, Linda Lowenstine, Bill McClelland, Michael Moore, Erika Nilson, Hendrick Nollens, Ann Pabst, Lisa Spavin, Justin Viezbicke, and Gina Ylitalo for reviewing this document prior to the 2014 release. Killer whale drawings on gross pathology recording form by Lee Harrison/©Free Morgan Foundation.

LITERATURE CITED:

Barbieri, M. M., S. A. Raverty, M. B. Hanson, and S. Venn-Watson, J. K. B. Ford and J. K. Gaydos. 2013. Spatial and temporal analysis of killer whale strandings in the North Pacific Ocean and the benefits of a coordinated stranding response protocol. Marine Mammal Science DOI: 10.1111/mms.12044, 15 pages.

Barrett, T., I. K. G., L. Mamaev, L Goatley, M-F. Van Bressem, and A.D.M.E. Osterhaus. 1993.

Dolphin and porpoise morbilliviruses are genetically distinct to phocine distemper virus. Virology 200: 10101012.

Bossart, G. D., and E. Eimstad. 1988. *Erysipelothrix* vesicular glossitis in a killer whale (*Orcinus orca*). Journal of Zoo Animal Medicine 19:42-47.

Bossart, G. D., T. A. Brawner, C. Cabal, M. Kuhns, E. A. Eimstad, J. Caron, M. Trimm, and P. Bradley. 1990. Hepatitis B-like infection in a Pacific white-sided dolphin. Journal of the American Veterinary Medical Association 196:127-130.

Bossart, G. D., C. Cray, J. L. Solorazano, S. J. Decker, L. H. Cornell, and N. H. Altman. 1996. Cutaneous papillomaviral-like papillomatosis in a killer whale (*Orcinus orca*). Marine Mammal Science 12:274-281

Brew, S.D., L. L. Perrett, J. A. Stack, A. P. MacMillan, and N.J. Staunton. 1999. Human exposure to *Brucella* recovered from a sea mammal. Veterinary Record 144:483

Cloeckaert A., M. Grayon, O. Grepinet, and K.S. Boumedine. 2003. Classification of *Brucella* spp. Isolated from marine mammals by DNA polymorphism at the omp-2 locus. Microbes and Infections 5(7):593-602

Dailey, M. D., 2001. Parasitic Diseases. *In* CRC Handbook of Marine Mammal Medicine, 2nd Edition L. A. Dierauf and F. M. D. Gulland (eds.). CRC Press, Boca Raton, Florida. Pp. 357-379.

Daily, M. D. and R. L. Brownell. 1972. A checklist of marine mammal parasites. *In* Mammals of the Sea, Biology and Medicine. S. Ridgway (ed.). Charles C. Thompson, Springfield, Illinois. Pp. 528-589.

Domingo, M, L. Ferrer, M. Pumarola, A. Marco, J. Plana, S. Kennedy, M. McAlisky, and B.K. Rima. 1990. Morbillivirus in dolphins. Nature 348:21.

Domingo, M., Kennedy, S. and M-F. Van Bressem. 2002. Marine Mammal Mass Mortalities. *In* Marine Mammals Biology and Conservation P.J.G.H. Evans and A.J. Raga (eds.). Kluwer Academic / Plenum Publishers, New York, Pp. 425-456.

Duignan, P. J., C. House, J. R. Geraci, N. Duffy, B. K. Rima, M. T. Walsh, G. Early, D. J. St Aubin, S. Sadove, H. Koopman, and H. Rhinehart. 1995. Morbillivirus infection in cetaceans of the western Atlantic. Veterinary Microbiology. 44:241-249.

Dunn, J. L., J. D. Buck, and T. R. Robeck. 2001. Bacterial Diseases of Cetaceans and Pinnipeds. *In* CRC Handbook of Marine Mammal Medicine, 2nd Edition. L. A. Dierauf and F. M. D. Gulland (eds.). CRC Press, Boca Raton, FL. Pp. 309-335.

Ewalt, D. R., D. R. Payeur, B. M. Martin, D. R. Cummins, and W.G. Miller. 1994. Characteristics of a *Brucella* species isolated from bottlenose dolphins (*Tursiops truncatus*). Journal of Veterinary Diagnostic Investigation 6:448-452.

Ford, J. K. B., G. M. Ellis, K. C. Balcomb. 2000. *Killer whales: The natural history and geneology of Orcinus orca in British Columbia and Washington*. University of British Columbia Press, Vancouver.

Foster, G., K. L. Jahans, R. J. Reid, and H. M. Ross. 1996. Isolation of *Brucella* species from cetaceans, seals and an otter. Veterinary Record. 138:583-586.

Gall, D, K. Nielsen, L. Forbes, D. Davis, P. Elzer, S. Olsen, S. Balsevicius, L. Kelly, P. Smith, S. Tan, and D. Joly. 2000. Validation of the fluorescent polarization assay and comparison to other serologic assays for the detection of serum antibodies to *Brucella abortus* in Bison. Journal of Wildlife Diseases. 36:469-476.

Gaydos, J.K., K. C. Balcomb, III, R. Osborne, and L Dierauf. 2004. Evaluating potential infectious disease threats for southern resident killer whales, *Orcinus orca*: a model for endangered species. Biological Conservation. 117:253-262.

Geraci, J. R, J. Harwood, and V. J. Lounsbury. 1999. Marine mammal die-offs. Causes,

investigations and issues. In Conservation and Management of Marine Mammals. J. R. Twiss and R. R. Reeves (eds.). Smithsonian Institution Press, Washington, D.C. Pp. 367-396.

Gibson, D. I. and R. A. Bray. 1997. *Oschmarinella albamarina* (Treschev, 1968) n. comb., a liver fluke from the killer whale *Orcinus orca* (L.) off the British coast. Systematic Parasitology. 36:39-45.

Gibson, D.I., E. A. Harris, R. A. Bray, P. D. Jepson, T. Kuiken, J. R. Baker, and V.R. Simpson. 1998. A survey of the helminth parasites of cetaceans stranded on the coast of England and Wales during the period 1990-1994. Journal of Zoology, London. 244:563-574.

Gonzalez L, I. A. Patterson, R. J. Reid, G. Foster, M. Barberan, J. M. Blasco, S. Kennedy, F. E. Howie, J. Godfroid, A. P. MacMillan, A. Schock, and D. Buxton. 2002. Chronic meningoencephalitis associated with *Brucella* sp. infection in live-stranded striped dolphins (*Stenella coeruleoalba*). Journal of Comparative Pathology. 126:147-152.

Greenwood, A. G., and D. C. Taylor. 1985. Captive Killer Whales in Europe. Aquatic Mammals 1:10-12.

Gulland, F. M., L. A. Dierauf, and T. K. Rowles. 2001. Marine mammal stranding networks. In CRC Handbook of Marine Mammal Medicine 2nd Edition. L. A. Dierauf and F. M. Gulland (eds.). CRC Press, New York, New York. Pp. 45-67.

Harms, C.A., W. A. McLellan, M. J. Moore, S. G. Barco, E. O. Clarke EO, V. G. Thayer and T. K. Rowles. 2014. Low residue euthanasia of stranded mysticetes. Journal of Wildlife Diseases 50:63-73.

Heptner, V.G., K. K. Chapskii, V. A. Arsen'ev., and V. E. Sokolov. 1976. Mammals of the Soviet Union. Volume II, part 3. Pinnipedia and Odontoceti. Vysshaya Shkola Publishers, Moscow, Soview Union. (English translation, 1996, Science Publishers, Lebanon, New Hampshire).

Hicks, C. L., R. Kinoshita, and P. W. Ladds. 2000. Pathology of meliodosis in captive marine mammals. Australian Veterinary Journal 78:193-195.

Jepson, P. D., S. Brew, A. P. MacMillan, J. R. Baker, J. Barnett, J. K. Kirkwood, T. Kuiken, I. R. Robinson, and V. R. Simpson. 1997. Antibodies to *Brucella* in marine mammals around the coast of England and Wales. The Veterinary Record 141:513-515.

Kennedy S. Morbillivirus infection in aquatic mammals. 1998. Journal of Comparative Pathology. 119:201-225.

Lipscomb T.P., Kennedy S., Moffett D., and B.K. Ford. 1994. Morbilliviral disease in an Atlantic bottlenose dolphin (*Tursiops truncatus*) from the Gulf of Mexico. Journal of Wildlife Diseases. 30:572-576.

Nielsen, O., R. E. Stewart, K. Nielsen, L. Measures, and P. Duignan. 2001. Serologic survey of *Brucella* spp. antibodies in some marine mammals of North America. Journal of Wildlife Diseases. 37:89-100.

NMFS. 2008. Recovery plan for Southern Resident killer whales (Orcinus orca). National Marine Fisheries Service, Northwest Region, Seattle, Washington.

Raverty, S., K. Nielsen, O. Nielsen, B. Hanson, and J. K. Gaydos. 2004. Detection of *Brucella* spp. antibodies in post mortem heart blood and antemortem serum of killer whales (*Orcinus orca*) in the Pacific Northwest. Proceedings of the 35th International Association for Aquatic Medicine Conference, Galveston, Texas. Pp 114-115.

Reidarson, T. H., J. F. McBain, L. M. Dalton, and M. G. Rinaldi. 1999. Diagnosis and treatment of fungal infections in marine mammals. In Zoo and Wild Animal Medicine Current Therapy 4th Edition. M. E. Fowler and R. E Miller (eds.). W.B. Saunders Company, Philadelphia, Pennsylvania. Pp. 478-485.

Ridgway, S.H. 1979. Reported causes of death of captive killer whales (*Orcinus orca*). Journal of Wildlife Diseases 15: 99-104. Ross, H.M., K. L. Jahans, A. P. MacMillian, R. J. Reid, P. M. Thompson, and G. Foster. 1996. *Brucella* species infection in North Sea seal and cetacean populations. Veterinary Record 138:647-648.

Rowles, T. K., F. Van Dolah, and A. A. Hohn. 2001. Gross necropsy and specimen collection protocols. In CRC Handbook of Marine Mammal Medicine 2nd Edition. L. A. Dierauf and F. M. Gulland (eds.). CRC Press, New York, New York. Pp. 449-470.

Saliki J. T., E. J. Cooper, and J. P. Gustavson. 2002. Emerging morbillivirus infections of marine mammals: development of two diagnostic approaches. Annals of the New York Academy of Science. 969:51-59.

Schulman, Y.S and T. Lipscomb. 1999. Dermatitis and invasive ciliated protozoa in dolphins that died during the 1987-1988 Atlantic bottlenose dolphin morbillivirus epizootic. Veterinary Pathology 36:171-174.

Sneizek, J.H., D. W. Coates, and E.B. Small. 1995. *Kyaroikeus cetarius* n.g., n. sp., a parasitic ciliate from the respiratory tract of odontocete cetacea. Journal of Eukaryotic Microbiology. 42:260-268.

Sohn, A.H., W. S. Probert, C. A. Glaser, N. Gupta, A. W. Bollen, J. D. Wong, E. M. Grace, and W.C. McDonald. 2003. Human neurobrucellosis with intracerebral granuloma caused by a marine mammal *Brucella* spp. Emerging Infectious Diseases. 9(4): 485-8.

St. Leger, J.A., G. Wu, M. Anderson, L. Dalton, E. Nilson, and D. Wang. West Nile Virus Infection in Killer Whale, Texas, USA, 2007. Emerging Infectious Diseases. 17:1531-1533.

Sweeney, J. C., G. Miyaki, P. M. Vainik, and R. H. Conklin. 1976. Systemic mycoses in marine mammals. Journal of the American Veterinary Medical Association 169:946-948.

US Federal Register. 2005. Endangered and threatened wildlife and planes: Endangered status for southern resident killer whales. 70(222):69903-69912.

Van Bressem, M. F., K. Van Waerebeek, and J. A. Raga.1999. A review of virus infections of cetaceans and the potential impact of morbilliviruses, poxviruses, and papillomaviruses on host population dynamics. Diseases of Aquatic Organisms 38:53-65.

Van Bressem, M. F., K. Van Waerebeek, J. A. Raga, J. Godfroid, S. D. Brew, and A. P. MacMillan, 2001a. Serological evidence of *Brucella* species infection in odontocetes from the south Pacific and the Mediterranean. Veterinary Record, 148:657-661.

Van Bressem, M. F., K Van Waerebeek, P. Jepson, J. A. Raga, P. J. Duignan, O. Nielsen, A. P. Di Beneditto, S. Siciliano, R. Remos, W. Kant, V. Peddemors, R Kinoshita, P. S. Ross, A. Lopez-Fernandez, K. Evans, E. Crespo, and T Barrett. 2001b. An insight into the epidemiology of dolphin morbillivirus worldwide. Veterinary Microbiology 81:287-304.

Van Bressem, M.-F., I. K. G. Visser, M. W. G. Van De Bildt, J. S. Teppema, J. A. Raga, and A. D. M. E. Osterhaus. 1991. Morbillivirus infection in Mediterranean striped dolphins (*Stenella coeruleoalba*). Veterinary Record. 129:471-472.

Young, S. J., R. L. Lewis, J. K. B Ford, and G. Ellis. 1997. First case report – mortality of a wild resident killer whale (*Orcinus orca*) from *Erysiplothrix rhusopathiae*. Proceedings of the International Association for Aquatic Animal Medicine, Baltimore Maryland, pp. 64-68.

KILLER WHALE NECROPSY PROTOCOL COMPREHENSIVE KILLER WHALE TISSUE SAMPLE CHECKLIST

Tissue	Test	Sample	Preservation
Blowhole	Bacteriology	Swab	Transport media
Genital slit	Bacteriology	Swab	Culture swab
Vagina	Bacteriology	Swab	Culture swab
Uterus	Bacteriology	Swab	Culture swab
Ovary	Bacteriology	Swab	Culture swab
Penis/testes	Bacteriology	Swab	Culture swab
Lung	Bacteriology	Swab	Culture swab
Trachea	Bacteriology	Swab	Culture swab
Lymph node, multiple sites	Bacteriology	Swab	Culture swab
Thymus	Bacteriology	1-2 cm^3 tissue sample	Plastic bag and freeze
Spleen	Bacteriology	1-2 cm^3 tissue sample	Plastic bag and freeze
Heart	Bacteriology	5 ml post mortem heart blood	Red toped tube or plastic bag and chill
Stomach	Bacteriology	Stomach	Culture swab
Small intestine, ileum and jejunum	Bacteriology	Swab	Culture swab
Colon	Bacteriology	Swab	Culture swab
Conjunctiva	Bacteriology	Swab	Culture swab
Teeth	Aging	1-2 intact	Plastic bag
Dorsal fin	Anatomy	Excise intact	Seal in plastic and freeze
Head	Anatomy	Intact	Plastic bag and freeze
Thymus	Archive	Multiple, 1-2 cm portions	Plastic bag and freeze
Spleen	Archive	Multiple, 1-2 cm^3 portions	Plastic bag and freeze
Thyroid gland	Archive	Multiple, 1-2 cm^3 portions	Plastic bag and freeze
Parathyroid gland	Archive	Multiple, 1-2 cm^3 portions	Plastic bag and freeze
Brain - cerebrum	Archive	Multiple, 1-2 cm^3 portions	Plastic bag and freeze
Brain - cerebellum	Archive	Multiple, 1-2 cm^3 portions	Plastic bag and freeze

Brain - brainstem	Archive	Multiple, 1-2 cm^3 portions	Plastic bag and freeze
Spinal cord (thoracic)	Archive	Multiple, 1-2 cm^3 portions	Plastic bag and freeze
Liver	Archive	Multiple, 1-2 cm^3 portions	Plastic bag and freeze
Kidney	Archive	Multiple, 1-2 cm^3 portions	Plastic bag and freeze
Adrenals	Archive	Multiple, 1-2 cm^3 portions	Plastic bag and freeze
Ureter	Archive	Multiple, 1-2 cm^3 portions	Plastic bag and freeze
Urinary bladder	Archive	5-10 ml urine and bladder wall	Plastic bag and freeze
Rib/Bone marrow	Archive	1-2 cm^3	Plastic bag and freeze
Diaphragm	Archive	2x2 cm	Plastic bag and freeze
Milk	Archive	Aspirate	Plastic bag and freeze
Uterus	Archive	Tissue samples	Plastic bag and freeze
Ovary	Archive	If possible, retain corpora intact	Histopathology
Oviduct	Archive	Tissue samples	Plastic bag and freeze
Trachea	Archive	Tissue samples	Plastic bag and freeze
Lymph node, multiple sites	Archive	Whole or partial nodes	Plastic bag and freeze
Pituitary gland	Archive	Half	Plastic bag and freeze
Heart	Archive	Tissue samples	Plastic bag and freeze
Bile	Archive	5-10 ml	Plastic bag and freeze
Pancreas	Archive	5-10 gm	Plastic bag - freeze
Small intestine, multiple levels	Archive	Ligated bowel	Plastic bag and freeze
Colon	Archive	Ligated bowel	Plastic bag and freeze
Skeletal muscle	Archive	5x5 cm	Plastic bag and freeze
Oropharynx/tonsil	Bacteriology	Swab	Culture swab
Umbilicus	Bacteriology	Swab	Culture swab
Mammary gland	Bacteriology	Swab	Culture swab
Joint fluid	Bacteriology	Swab	Culture swab

Urinary bladder	Biotoxin assay, cytology/culture	5-10 ml	Sterile plastic bag and freeze
Stomach	Biotoxin assay, prey selection	Entire or portion of ingesta	Place in plastic bag and freeze
Eye	Clinical chemistry	Aspirate 3-5 ml of vitreous	Red top tube and chill
Small intestine, ileum and jejunum	Contents	Ligated bowel	Place in plastic bag and chill
Ears	CT scan	Intact	Plastic bag and freeze
Blowhole	Cytology	Scraping	Air dry and stain
Mammary gland	Cytology	Aspirate	Plastic bag and chill
Joint fluid	Cytology	5 ml	Red top tube
Rib/Bone marrow	Cytology	Smear	Air fix/alcohol
Pericardial fluid	Cytology and serology	10 ml	Red top tube or plastic bag and freeze
Conjunctiva	Electron microscopy	Dry swab	Place in Whirl-pak® bag and chill
Skin	Genetics	1 cm^3	DMSO or freeze
Skin, multiple sites, including lesioned and non-lesioned	Histopathology	See Guidelines (*)	Formalin
Oral mucosa	Histopathology	See Guidelines (*)	Formalin
Oropharynx	Histopathology	See Guidelines (*)	Formalin
Blowhole and air sacs	Histopathology	See Guidelines (*)	Formalin
Tonsil	Histopathology	See Guidelines (*)	Formalin
Conjunctiva	Histopathology	See Guidelines (*)	Formalin
Umbilicus	Histopathology	See Guidelines (*)	Formalin
Mammary gland	Histopathology	See Guidelines (*)	Formalin
Tongue	Histopathology	See Guidelines (*)	Formalin
Eye	Histopathology	Intact, inject with 1-2 cc of formalin	Formalin
Genital slit	Histopathology	See Guidelines (*)	Formalin
Vagina	Histopathology	See Guidelines (*)	Formalin
Uterus	Histopathology	1x2 cm	Formalin
Ovary	Histopathology	See Guidelines (*)	Formalin
Oviduct	Histopathology	See Guidelines (*)	Formalin
Penis/testes	Histopathology	See Guidelines (*)	Formalin
Accessory sex glands	Histopathology	See Guidelines (*)	Formalin
Lung	Histopathology	See Guidelines (*)	Formalin
Trachea	Histopathology	See Guidelines (*)	Formalin
Lymph node, multiple sites	Histopathology	See Guidelines (*)	Formalin
Thymus	Histopathology	See Guidelines (*)	Formalin

Spleen	Histopathology	See Guidelines (*)	Formalin
Thyroid gland	Histopathology	See Guidelines (*)	Formalin
Parathyroid gland	Histopathology	See Guidelines (*)	Formalin
Brain - cerebrum	Histopathology	See Guidelines (*)	Formalin
Brain - cerebellum	Histopathology	See Guidelines (*)	Formalin
Brain – brainstem, pons, medulla, colliculus	Histopathology	See Guidelines (*)	Formalin
Ears	Histopathology	Peribullar fat	Formalin
Pituitary gland	Histopathology	Half	Formalin
Spinal cord (thoracic)	Histopathology	See Guidelines (*)	Formalin
Brachial plexus	Histopathology	1-2 cm^3	Formalin
Heart, interventricular septa, ventricles, atria, papillary muscle and valve	Histopathology	See Guidelines (*)	Formalin
Aorta and vena cava, multiple levels	Histopathology	Aorta and vena cava, multiple levels	Histopathology
Liver	Histopathology	See Guidelines (*)	Formalin
Pancreas	Histopathology	See Guidelines (*)	Formalin
Stomach	Histopathology	See Guidelines (*)	Formalin
Small intestine, ileum and jejunum	Histopathology	See Guidelines (*)	Formalin
Colon	Histopathology	See Guidelines (*)	Formalin
Kidney	Histopathology	See Guidelines (*)	Formalin
Adrenals	Histopathology	See Guidelines (*)	Formalin
Ureter	Histopathology	See Guidelines (*)	Formalin
Urinary bladder	Histopathology	See Guidelines (*)	Formalin
Skeletal muscle	Histopathology	See Guidelines (*)	Formalin
Rib/Bone marrow	Histopathology	See Guidelines (*)	Formalin
Peripheral nerve	Histopathology	See Guidelines (*)	Formalin
Diaphragm	Histopathology	See Guidelines (*)	Formalin
Blubber	Lipid analysis	10 cm^3	Aluminum foil and freeze
Oropharynx	Molecular studies	Dry swab	Place in plastic bag and chill
Blowhole	Molecular studies	Dry swab	Place in plastic bag and chill
Tonsil	Molecular studies	1-2 cm^3	Plastic bag and freeze
Conjunctiva	Molecular studies	Swab	Place in whirlpak bag and chill
Genital slit	Molecular studies	Dry swab	Place in plastic bag and chill
Vagina	Molecular studies	Dry swab	Place in plastic bag and chill

Uterus	Molecular studies	Dry swab	Place in plastic bag and chill
Ovary	Molecular studies	Dry swab or 1-2 cm tissue sample	Place in plastic bag and chill
Penis/testes	Molecular studies	Dry swab	Place in plastic bag and chill
Lung	Molecular studies	1x1 cm tissue	Place in plastic bag and chill
Lymph node, multiple sites	Molecular studies	Dry swab	Place in plastic bag and chill
Thymus	Molecular studies	1-2 cm^3 tissue sample	Place in plastic bag and chill
Spleen	Molecular studies	1-2 cm^3 tissue sample	Place in plastic bag and chill
Water sample	Molecular studies	10 ml	Plastic bag and freeze
Mandible	Morphometric study	Intact	Plastic bag and freeze
Blowhole	Mycology	Swab	Transport media
Genital slit	Mycology	Swab	Culture swab
Vagina	Mycology	Swab	Culture swab
Uterus	Mycology	Swab	Culture swab
Penis/testes	Mycology	Swab	Culture swab
Lung	Mycology	Swab	Culture swab
Lymph node, multiple sites	Mycology	Swab	Culture swab
Small intestine	Mycology	Swab	Culture swab
Colon	Mycology	Swab	Culture swab
Blowhole	*Mycoplasma* culture	Swab	Culture swab
Lung	*Mycoplasma* culture	Swab	Culture swab
Genital slit/Urogenital canal	*Mycoplasma* culture	Swab	Culture swab
Middle ear	*Mycoplasma* culture	Swab	Culture swab
Blowhole	Parasitology	Swab	Preserve in Bouin's
Tongue	Parasitology	3x3 cm	Plastic bag and freeze
Stomach	Parasitology	Ingesta	Plastic bag and chill
Colon	Salmonella culture	Swab	Culture swab
Mandible	Sonar related injury	Internal mandibular fat	Histopathology
Pericardium	Tissue culture	Pericardium	Tissue culture

Blubber	Toxicology Contaminant	3x3 cm	Aluminum foil and freeze
Liver	Toxicology Contaminant	3x3 cm	Aluminum foil and freeze
Kidney	Toxicology Contaminant	3x3 cm	Aluminum foil and freeze
Bile	Toxicology Contaminant	1-2 mL	Glass vial and freeze
Feces	Toxicology Contaminant	2- 5g	Glass jar and freeze
Kidney	Trace mineral analysis	5x5 cm	Plastic bag and freeze
Liver	Trace mineral and vitamin analysis	5x5 cm	Plastic bag and freeze
Urinary bladder	Urinalysis	5-10 ml	Red top tube
Tonsil	Virus Isolation	5 gm	Plastic bag and chill or freeze
Lung	Virus Isolation	5 gm	Plastic bag and chill or freeze
Lymph node, multiple sites	Virus Isolation	5 gm	Plastic bag and chill or freeze
Spleen	Virus Isolation	5 gm	Plastic bag and chill or freeze
Brain - cerebrum	Virus Isolation	5 gm	Plastic bag and chill or freeze
Kidney	Virus Isolation	5 gm	Plastic bag and chill or freeze
Thyroid gland	Weight	Intact gland	Fresh
Pituitary gland	Weight	Intact	Fresh
Kidney	Weights	Intact	Fresh

APPENDIX I: Sample Priorities based on Tissue Condition

Circumstances associated with killer whale stranding and resources available at the time of post mortem examination will vary considerably and some flexibility and discretion must be afforded to the necropsy team. In those situations were autolysis, location, equipment, personnel or other factors may restrict access or limit the ability to expedite a thorough necropsy, the tissue sampling and ranking below should facilitate prioritization of sample collection for diagnostic evaluation. Within reason, every effort should be made to collect the high priority samples with each stranding. The ultimate disposition of tissues will be the responsibility of the lead government agency or regional marine mammal coordinator within the respective area.

ALL requests must be cleared by the regional coordinator prior to shipping to researchers.

HIGH PRIORITY SAMPLES:

For all killer whales that strand, attempt tissue collection of the samples listed below regardless of post mortem condition of carcass.

Tissue	Test	Sample	Preservation	√
As many representative tissues as possible	Histopathology	See Guidelines (*)	Formalin	
Blubber and skin/Liver/Kidney	Toxicology Contaminants	3 cm^3	Aluminum foil and freeze	
Skin	Genetics	1 cm^3	Freeze or DMSO	
Oropharynx/tonsil/ blowhole	Molecular studies and culture	Dry swabs and with transport media	Place in plastic bag and chill	
Mammary gland	Bacteriology/cytology	3 cm^3 tissue	Place in plastic bag and chill	
Eye	Clinical chemistry	Aspirate 3-5 ml of vitreous	Red top tube and chill	
Genital slit/ Urogenital canal	Molecular studies and culture	Dry swabs and with transport media	Place in plastic bag and chill	
Ovary	Reproductive and molecular studies	Dry swab and intact ovary	Place in plastic bag and chill	
Morphometrics and photographs	Identification	Digital or slide film	Disc	
Lung/regional lymph nodes/spleen	Molecular studies and bacteriology	2x2 cm tissue	Place in plastic bag and chill	
Post mortem blood sample	Serology and bacterial culture	10-20 ml	Collect in red top tubes and chill	
Stomach and small intestine	Biotoxin assay, stomach content analysis	Ligated	Place in plastic bag and freeze	
Urinary bladder/bile	Biotoxin assay, cytology/culture/urinalysis	5-10 ml	Sterile plastic bag and freeze	

INTERMEDIATE PRIORITY SAMPLES:

Collect tissues below if sufficient time and carcass is reasonably fresh (code 1-3).

Tissue	Test	Sample	Preservation	√
Small intestine	Parasitology	Ingesta	Plastic bag and chill	
Tonsil	Histopathology	See Guidelines (*)	Formalin	
Tonsil	Molecular studies	5 gm	Plastic bag and chill or freeze	
Mandible	Sonar related injury	Internal mandibular fat	Histopathology	
Head	Anatomy	Intact	Plastic bag and freeze	
Uterus	Molecular studies	Dry swab	Place in plastic bag and chill	
Brain, liver, kidney, spleen, lymph nodes and lung	Virus Isolation	5 gm	Individual plastic bags and chill or freeze	
Ears	Histopathology	Peribullar fat	Formalin	
Ears	CT scan	Intact	Plastic bag and freeze	
Bile	Toxicology Contaminant	1-2 mL	Glass vial and freeze	
Feces	Toxicology Contaminant	4-5 g	Solvent rinsed glass jar and freeze	
Liver	Trace mineral and vitamin analysis	5 cm^3	Plastic bag and freeze	

LOW PRIORITY SAMPLES:

If there is sufficient time and resources available, the following samples and morphometrics should be collected.

Tissue	Test	Sample	Preservation	√
Dorsal fin	Anatomy	Excise intact	Seal in plastic and freeze	
Teeth	Aging	1-2 intact	Plastic bag	
Organs	Weight	Intact	Fresh	
Mandible	Morphometric study	Intact	Plastic bag and freeze	
Blubber measurement	Morphometric study	Collect and document	Record information	

At the time of necropsy, the tissue sampling checklist (Appendix I) and request lists (Appendices IV) should be consulted and tissues from all major organs and lesions collected for histopathology and representative samples frozen for ancillary studies.

The tissue checklist is designed to follow the sequential post mortem examination of the whale. As organs are excised and appropriate tissues collected and preserved, please mark off the right hand column with an “x”.

TISSUE SAMPLE SIZE AND PRESERVATION

*Guidelines for fixation of tissues for histopathologic evaluation: preserve all lesions and as many of the tissues listed below as possible in 10% buffered formalin. Tissue samples should be between 3-5 cm^2 in area and up to 0.5 to 1.0 cm in width and immersed in a ratio of 1 part tissue to 10-15 parts formalin. If electron microscopy (EM) fixative such as glutaraldehyde is available, preserve minced (1-2 mm^3) pieces of kidney, liver, spleen and lung.

Representative 3-5 cm blocks of tissue from lesions and major organs (e.g., lung, liver, kidney, spleen) should be placed in individually labeled small (preferably Whirl-pak®) plastic bags and placed on dry or wet ice for initial storage and transportation. Also, collect post-mortem serum (from heart blood), urine, eye fluid, bile, ingesta, and any abnormal fluid accumulations. Heart blood should be spun as soon as possible to limit the degree of hemolysis. Upon arrival to a diagnostic or reference laboratory, samples should be frozen at -70 degrees Celsius. If this is unavailable, temporary storage in conventional freezer without automatic defrost cycle is acceptable. A 1-2 cm block of skin, muscle or flipper for genetic analysis should be excised and foil-wrapped and frozen. The sample can be placed in DMSO/saline solution if there is likelihood that the samples cannot remain frozen until they reach their final destination, but freezing without preservative is preferred.

For each lesion, up to 2-3 swabs may be obtained and samples should be chilled for transport to a diagnostic facility. In addition to routine TSA and blood agar cultures, special media for isolation of halophilic bacteria should also be inoculated.

APPENDIX II: Pathogens reported in killer whales

Table 1: Pathogens detected directly or via serology in killer whales

Agent	Reference	Location
Bacteria		
Brucella spp.	Jepson et al., 1997; Raverty et al., 2004	Northeastern Atlantic and Pacific
Edwardsiella tarda	Ford et al., 2000	Northeastern Pacific
Salmonella spp.	Ridgway, 1979; Colegrove et al., 2010	Northeastern Pacific and captive
Burkholderia pseudomallei	Hicks et al., 2000	Captive
Clostridium perfringens	Walsh et al., 1994	Captive
Erysipelothrix rhusiopathiae	Young et al., 2002; Bossart et al., 1988	Northeastern Pacific and Captive
Nocardia asteroides	Sweeney et al., 1976	Captive
Nocardia farcinica	St. Leger et al, 2009	Captive
Nocardia otitidiscaviarum	Dunn et al., 2001	Captive
Pseudomonas aeruginosa	Rozanova et al., 2003	Avacha Gulf (Kamchatka)
Streptococcus sp., beta-hemolytic	Greenwood and Taylor, 1985	Captive
Staphylococcus aureus	Power and Murphy 2002	Atlantic
Viruses		
Cetacean pox like virus (Orthopoxvirus)	Van Bressem et al., 1999	Not Reported
Hepatitis-B like virus	Bossart et al., 1990	Captive
Influenza (suspected)	Ridgway, 1979	Captive
Cutaneous papilloma-like virus	Bossart et al., 1996	Captive
West Nile Virus	St. Leger et al, 2011	Captive
Fungi		
Aspergillus fumigatus	Reidarson et al., 1999	Captive
Candida albicans	Greenwood and Taylor, 1985; Ridgway, 1979; Sweeney et al., 1976	Captive
Cunninghamella bertholletiae	Kakizoe et al., 2012	Captive
Saksenaea vasiformis	Reidarson et al., 1999	Captive

Table 2: Endoparasites identified or suggested by serology in killer whales

Parasite	Reference
Acanthocephala	
Bolbosoma niponicum	Heptner et al., 1976
Bolbosoma physeteris	Heptner et al,. 1976
Cestoda	
Phyllobothrium sp.	Dailey and Brownell, 1972
Trigonocotyle spasskyi	Dailey and Brownell, 1972
Nematoda	
Anasakis simplex	Dailey and Brownell, 1972
Anasakis pacificus	Heptner et al., 1976
Amphipods	
Cymus orcini	Leung, 1970
Trematoda	
Campula sp.	Gibson et al., 1998
Fasciola skrjabini	Dailey and Brownell, 1972
Leucasiella subtilla	Heptner et al., 1976
Oschmarinella albamarina	Gibson and Bray, 1997
Protozoa	
Kyaroikeus cetarius	Sneizek et al, 1995; Schulman and Lipscomb, 1999
Toxoplasma gondii and Sarcocystis spp.	Gibson et al., 2011

APPENDIX III: The One Hour Necropsy Protocol

Time and tides can work against any investigation. Occasionally, the time allowable for an investigation is extremely limited. When this is the case, efficient data and sample collection are critical for safety and maximum learning. To facilitate this, the following check list can be performed in order. In all cases, tissues should be collected as large samples and then subsampled per Appendix I. This will maximize data and sample collection and can be concluded at any time.

- Capture Level A data – location, date, age class, sex (if possible to determine)
- Collect photos from all sides and of all surfaces visible. Turn the animal if at all possible to facilitate image capture.
- Collect basic morphometrics – length (critical measurement), girth (1/2 times 2 often works best), dorsal fin height and base length.
- Examine the dorsal fin for evidence of a tracking device or scar from such a device. If found, collect device or measure and photograph the scar.
- Flense blubber and look specifically for indications of hemorrhage, bruising, or broken bones. These could include ribs, vertebrae, or the skull so try to examine as widely as feasible.
- Collect skin/blubber from the dorsum if feasible.
- Collect skeletal muscle
- Open the abdomen
- Collect abdominal fluid, liver, kidney, spleen, lymph nodes, gonads, uterus (if applicable), and urine
- Open the thorax – an incision in the diaphragm will facilitate quick access but limited visualization
- Collect heart, lung, trachea, thymus (if present), larynx, and tonsils
- Collect stomach content (or whole stomach – as feasible), intestinal content and intestinal sections
- Collect esophagus
- Remove 2-3 teeth from the middle of the arcade on the most accessible mandible side
- Disarticulate the head, open the skull, remove and collect the brain.

APPENDIX IV: Researchers requesting killer whale tissues

Test	Sample	Investigator	Contact information
Algal toxin	Ingesta (stomach) , Liver/Bile /Feces/urine	Dr. LeFebvre	206-302-2454
Anatomy	Mandible	Dr. Barrett-Lennard	604-659-3428
Anatomy	Head	Dr. Barrett-Lennard	604-659-3428
Anatomy (US)	Dorsal fin	Dr. Hanson Dr. Andrews	206-860-3220
Anatomy (US)	Whole skeleton	Dr. Hanson	206-860-3220
Bacteriology (Canada)	Multiple tissues	Dr. Raverty	604-556-3003
Bacteriology (US)	Multiple Tissues	Dr. Goldstein	530-754-7953
Brucella culture	Lung, brain, CSF, uterus/testes, and lymph nodes	Dr. Byrne, UC Davis	
CT scan	Ears/Head	Dr. Hanson Dr. Dennison	206-860-3220
Cell culture	Representative fresh tissues	Dr. Wise	207-228-8050
Clinical chemistry	Serum sample	Dr. St. Leger	619-225-4259
Fatty acid analysis	Blubber and skin	Ms. Ylitalo	206-860-3325
Genetics	Skin biopsy	Dr. Barrett-Lennard Dr. Parsons Dr.Morin	604-659-3428 206-302-2428 858-546-7165
Hematology (US)	Blood (fresh/unfrozen)	Dr. St. Leger	619-225-4259
Histopathology	Formalin fixed tissues	Dr. St. Leger Dr. Raverty Dr. Rotstein	619-225-4259 604-556-3003 240-238-1165
Hormone analysis	Serum and feces	Dr. St. Leger	619-225-4259
Molecular studies/ PCR	Multiple tissues	Dr. Raverty	604-556-3003
Mycoplasma culture (US)	Swabs of respiratory tract, middle ear and genital slit/urogenital canal	Dr. Frasca	860 486-1138
Parasitology	Ingesta and parasites	Dr. Kinsella	415-289-7346
Prey analysis (US)	Stomach contents	Dr. Hanson	206-860-3220
Prey analysis (Canada)	Stomach contents	Dr. Ford	250-756-7245
Radionucleotides	Skeletal muscle	Dr. Dasher	907-474-6840
Reproductive	Formalin, intact	Dr. Hanson	206-860-3220
Serology	Heart blood	Dr. Saliki/O. Nielsen	405-744-6623/204-983-5126
Toxicology - POPs	Blubber, liver and kidney	Ms. Ylitalo	206-860-3325
Trace mineral and vitamin A analysis	Liver and kidney	CAHFS Lab	530-752-8700
Viral hunting (molecular techniques)	Brain, trachea, lung, liver, spleen, skin, lymph node, and feces	Dr. Anthony	760-500-4639
Virology	Multiple tissues: EDTA blood	Dr. Saliki/Dr. Raverty	405-744-6623/604-556-3003

APPENDIX IVA: Specific research / case evaluation requests

Below are currently approved requests and protocols (as of March, 2014).

1. Dr. Lance Barrett-Lennard, Vancouver Aquarium Marine Science Centre 845 Avison Way Vancouver, British Columbia V6G 3E2 Phone: 604-659-3428, Email: barrett@zoology.ubc.ca

    - **Intact skull or lower jaw (mandible) for morphometric studies.** Please contact Dr Barrett-Lennard before conducting the post mortem.
    - **Skin samples.** Punch biopsy or excised skin, including epidermis and hypodermis. Placed in either DMSO/saline solution and refrigerate or wrap in aluminum foil and freeze.

2. Dr. Rebecca Pugh, NIST 219 Fort Johnson Road Charleston, South Carolina 29412 Work: 843-762-8952 Email: Rebecca.pugh@nist.gov

    - **Fresh dead tissue** samples for ongoing efforts to collect and appropriately archive harvested tissue samples from multiple indicator species. Please call before conducting necropsy for additional details.

3. Dr. Mike Kinsella, HelmWest Laboratory, 2108 Hilda Avenue, Missoula, Montana 59801, USA. Wormdwb@aol.com
    - **Preservation of parasite samples for ongoing speciation studies**. Samples of stomach worms, frozen in Whirl-pak® bags at -70, alternatively, freeze in standard freezer, ship overnight on dry ice. All other parasites, preserve in 90% ethanol in Whirl-pak® bags. If possible, let flatworms relax in tap water in cooler overnight before fixation.

4. Mycobacteria and Brucella Section Diagnostic Bacteriology Laboratory National Veterinary Services Laboratories 1800 Dayton Road Ames, IA 50010 Phone: 515-663-7347 Fax: 515-663-7904
    - **Frozen tissue samples for *Brucella* culture.**

5. Dr. Bradley Hanson, NOAA/NMFS/Northwest Fisheries Science Center 2725 Montlake Blvd. E Seattle, WA 98112 Work: 206-860-3220 Fax: 206-860-3475, Cell Phone: 206-300-0282 Email: Brad.Hanson@noaa.gov

    - **Stomach content, head, and dorsal fin for anatomic analysis**. Please either ligate the esophagus and duodenum or remove all the stomach contents, then freeze for analysis. Dorsal fin, remove 10 cm below insertion, place in plastic bag and freeze. Head may be disarticulated, then placed in plastic bag and frozen.
    - **Ovaries.** Please preserve intact in formalin.

6. Dr. John Ford, Fisheries and Oceans Canada Pacific Biological Station 3109 Hammond Bay Road, Nanaimo, BC, Canada V9T 6N7 Work: 729-8375 Fax: 250-756-7053 Email: john.k.ford@dfo-mpo.gc.ca

7. Dr. Stephen Raverty, Animal Health Center 1767 Angus Campbell Road Abbotsford, BC, Canada V3M 2G3 Phone, work: 604-556-3003 Phone (work): 800-661-9903, Email: Stephen.Raverty@gems3.gov.bc.ca

    - **Fresh and fixed tissue samples for ongoing investigation into mortality of stranded killer whales.** Please call before conducting necropsy for additional details. Please also send frozen samples of tongue and masseter muscle as well as diaphragm for *Apicomplexa* testing, frozen stomach contents and bile for algal toxin testing, multiple frozen tissues for bacteriology, and frozen samples of kidney and liver (wrapped in foil) for trace mineral analysis.

    - **Samples of liver, kidney, brain and blubber (toxicologic investigation) from stranded killer whales.** Please record species, age, location and date. Wrap 30-50 gm of tissue in aluminum foil then freeze at -20C, ship on dry ice.

8. Dr. Jeremiah Saliki, University of Georgia Athens Diagnostic lab 0149 Athens Vet Med Diagnostic Lab. Athens, GA 30602 Phone 706- 542-5906, jsaliki@uga.edu

    - **Post-mortem heart blood and frozen tissue samples**. Serology, molecular studies and attempted virus isolation on marine mammal specific cell lines. Remove serum from blood sample and freeze at -80C. Various tissues (tonsil, spleen, lymph nodes, kidney, lung, kidney) for virus isolation. If possible, ship chilled same day for overnight delivery; if not, store frozen until shipped.

9. Dr. J. L. Stott, Marine Mammal Immunology Laboratory, Veterinary Medicine PMI VM3A Rm 4206, One Shields Avenue, University of California Davis, CA 95616, Phone: 530-752-2543 Cell: 530-902-3971, E-mail: jlstott@ucdavis.edu

    - **Blood samples for immune function testing of <u>live animals</u>.** Only for code 1 (live stranded) cases. The appropriate vacutainers and instructions for use are listed in Appendix IVa. Prior arrangements MUST be made. Leave messages on **both** lab and cell phones and also send e-mail.

10. Dr. Phil Morin, NOAA/NMFS/Southwest Fisheries Science Center Population Identification Program, 8604 La Jolla Shores Drive La Jolla, CA 92037-1508 Phone: 858-546-5620, E-mail: Phil.morin@noaa.gov and Dr. Kim Parsons National Marine Mammal Laboratory Alaska Fisheries Science Center/NOAA, 7600 Sand Point Way N.E. Seattle, WA 98115-6349, Phone: (206)-526-4041 E-mail: Kim.Parsons@noaa.gov

    - **Skin samples for genetics.** Punch biopsy or excised skin, including epidermis and hypodermis. Placed in either DMSO/saline solution and refrigerate or wrap in aluminum foil and freeze.

11. Dr. Sal Frasca, Connecticut Veterinary Medical Diagnostic Laboratory, Department of Pathobiology and Veterinary Science, University of Connecticut, 61 North Eagleville Road, Storrs, CT 06269-3089
    Phone: 860-486-1138. salvatore.frasca@uconn.edu

- **Tissue samples for attempted *Mycoplasma* spp isolation.** Swabs or fresh tissue should be aseptically collected from representative levels of the respiratory system, including the blowhole, larynx, trachea, tracheal bifurcation, lungs, mediastinal lymph nodes, middle ear, and genital slit/urogenital tract. Swabs should be chilled and forwarded by courier.

12. John Pierce Wise, Sr., Ph.D. Director, Center for Integrated and Applied Environmental Toxicology Associate Professor of Toxicology and Molecular Epidemiology Bioscience Research Institute University of Southern Maine 178 Science Building 96 Falmouth Street Portland, ME 04103 Phone: 207-228-8047 Email: WiseLab@usm.maine.edu

    - **Fresh tissue samples to be cultured and stabilized ("immortalized") for subsequent toxicological studies and for placement in the marine mammal cell repository for other permitted researchers**. Please collect skin (w/dermis), kidney, liver, bronchus, testes/ovaries, brain from all young animals and call for storage and shipping recommendations.

13. Ms. Gina Ylitalo, NOAA Fisheries / Northwest Science Center 2725 Montlake Boulevard East Seattle, WA 98112 Phone: 206-860-3325, E-mail: Gina.Ylitalo@noaa.gov

    - **Samples of liver, kidney blubber with skin, skeletal muscle, bile, and feces. (Contaminant toxicologic investigation).** Please record species, age, location and date. Wrap 30-50 gm of tissue in aluminum foil or place in appropriate glass containers, then freeze at -20C, ship on dry ice (Appendix IX).

14. Dr. Doug Dasher, University of Alaska Fairbanks 905 N. Koyukuk 245 O'Neill Building P.O. Box 757220 Fairbanks, AK 99775-7220 Phone: 907-474-6840, E-mail: dhdasher@alaska.edu

    - **Samples of skeletal muscle for detection of Cs 137 and Cs 134 radionucleotides.** Please collect **1kg** of dorsal skeletal muscular and freeze (-20 is fine) in a plastic Ziploc or Whirl-pak® bag. Use clean gloves and keep sand or sediments off of the sample. Ship frozen for testing.

15. Dr. Dawn Noren, Research Fishery Biologist, NOAA NMFS Northwest Fisheries Science Center, Seattle, WA Phones: Office: 206-302-2439/ Cell: 206-423-0215, E-mail: dawn.noren@noaa.gov

    - **Samples of skeletal muscle to measure muscle myoglobin content and acid buffering capacity** (to assess variability in muscle biochemistry and diving capability with development and across ecotypes). Collect muscle samples from all age carcasses that are in fresh condition (Code 2). Samples are to be collected from the mid-belly of the primary locomotor muscle (*m. longissimus dorsi*). The location of the sampling site is below the anterior insertion site of the dorsal fin. Samples (3X3 inch block) should be completely wrapped in foil, placed in a Ziploc bag, and frozen immediately after collection.

APPENDIX IVB: Request for marine mammal post-mortem samples

Name_____
Date of request _____
Affiliation_____
Address
_____
Work phone (____)_____
Cell phone (____)_____
Fax (____) _____
Email_____

All sample requests should have a two to five page description of the study to be performed including specifics on related background, the sample(s) required, optimal collection and storage, shipping directions, timeline for sample analysis and plans for integration into larger ecological investigations. This material along with permits, investigator CVs, and shipping account numbers should be provided to Drs. Hanson and Ford (Contact info on the next page).

Sample(s) requested
_____
Purpose of study

_____
Duration of study (start and stop dates)

_____
Instructions for sample preparation

_____

Shipping instructions (Permits? Dry ice? Overnight? Will you pay for shipping?)

Special instructions

Dr. Brad Hanson, NOAA/NMFS/Northwest Fisheries Science Center, 2725 Montlake Blvd. E, Seattle, WA 98112, Office phone: 206-860-3220, Fax: 206-860-3475, Cell phone: 206-300-0282, Email: **Brad.Hanson@noaa.gov**

Dr. John Ford Fisheries and Oceans Canada Pacific Biological Station 3109 Hammond Bay Road, Nanaimo, BC, Canada V9T 6N7 Work: 729-8375 Fax: 250-756-7053 Email: **john.k.ford@dfo-mpo.gc.ca**

APPENDIX V: Permitting concerns and authorities

Marine mammals are protected internationally under a variety of treaties and acts. All stranding response should begin with contacting the proper authorities.
In the USA, marine mammals are protected under the Marine Mammal Protection Act and the Endangered Species Act. In Canada, killer whales are covered by the Species at Risk Act (SARA).

International shipment of samples and materials must comply with the Convention on International Trade of Endangered Species (CITES) as well as US Department of Agriculture/ Animal and Plant Health Inspection Service (USDA/APHIS). Permits are required for international exchanges.

USA: NOAA Office of Protected Resources (OPR) http://www.nmfs.noaa.gov/pr/
Dr. Teri Rowles. Teri.Rowles@noaa.gov (301) 713-2322 x-178 Stranding network hotlines: http://www.nmfs.noaa.gov/pr/health/networks.htm

CITES: http://www.cites.org/common/cop/15/doc/E15-30-01T.pdf
USDA/APHIS: http://www.aphis.usda.gov/
US Fish and Wildlife Service: http://www.fws.gov/

CANADA: Fisheries and Oceans Canada, http://www.pac.dfo-mpo.gc.ca/fm-gp/species-especes/mammals-mammiferes/index-eng.html
Paul Cottrell, DFO Marine Mammal Coordinator (604) 666-9965

SARA: http://www.sararegistry.gc.ca/default_e.cfm
CITES : http://www.dfo-mpo.gc.ca/acts-lois/cites-eng.htm
DFO Marine Mammal Response Hotline (British Columbia): (800) 465-4336

APPENDIX VI: Pathogen and tissue sample list for Polymerase Chain Reaction Studies

Current list of pathogens that may be screened by polymerase chain reaction. These tests may be conducted on tissues harvested from animals recovered in code 1 and 2 and *in select cases,* code 3. Various laboratories perform these tests.

Pathogen	Tissues
Adenovirus	Lymph node, spleen, lung, liver
Apicomplexa	Diaphragm, skeletal muscle, tongue, brain, lymph node, liver, heart
Bartonella sp	Lymph node, spleen, lung, liver, brain
Brucella spp, marine mammal variant	Lymph node, spleen, lung, brain, CSF, uterus/testes, amnionic fluid
Canine distemper virus	Lymph node, spleen, lung, brain
Cetacean pox (orthopox virus)	Skin, lung, spleen
Dolphin morbillivirus	Lymph node, spleen, lung, brain
Calicivirus, marine	Feces, small intestine, skin lesions
Chlamydophila psittaci-Avian	Lymph node, spleen, lung, brain
Chlamydophila abortus –Ovine	Lymph node, spleen, lung, brain
Circovirus	Lymph node, spleen, lung, brain
Clostridium genotyping (toxin)	Small and large intestine, bacterial isolate
Clostridium piliforme -Tyzzer's disease	Intestine or liver
Coronavirus consensus	Intestine, liver, lung
Coxiella burnetii	Lymph node, spleen, lung, brain, placenta
Cryptococcus gattii	Isolate, genotyping
Cryptosporidium parvum	Small intestine, feces
Enterovirus	Small intestine, heart, lung, brain
Erysipelothrix rhusiopathiae	Lymph node, spleen, lung, brain, ascites
Escherichia coli genotyping - Bovine/Porcine	Bacterial isolate
Filovirus consensus	Brain, lung, spleen, lymph nodes
Flavivirus	Brain, lung, spleen, lymph nodes
Fungus - Universal	Fungal isolate
Giardia lamblia	Feces, small intestine
Helicobacter spp	Stomach, glandular compartment
Hepatitis A,B, and C	Liver
Hepatovirus	Liver
Herpesvirus – Universal (consensus)	Lymph node, spleen, lung, brain, liver, adrenal gland
Influenza Virus – Universal	Lymph node, spleen, lung, brain
Leptospira (multivalent)	Liver, kidney
Listeria monocytogenes	Brain, lymph node, spleen, lung
Morbillivirus - Universal	Lymph node, spleen, lung, brain
Mycobacterium - Universal	Lymph node, spleen, lung, brain
Mycobacterium avium	Intestine, mesenteric lymph nodes, feces
Mycobacterium paratuberculosis	Intestine, mesenteric lymph nodes, feces
Mycoplasma (Mollicutes) - Universal	Lymph node, spleen, lung, nares, oviduct, placenta
Neospora caninum	Lymph node, spleen, lung, brain

Nocardia - Universal	Skin, lung, lymph node, spleen
Papillomavirus- universal	Skin, prepuce, vulva, gingiva, tongue
Parainfluenza virus	Lung, lymph node, spleen
Paramyxovirus	Lung, brain, lymph node and spleen
Parapoxvirus-consensus	Lung, skin, genitalia
Picornavirus	Pancreas, small intestine
Poxvirus	Skin, prepuce, vulva, gingiva, tongue
Reovirus	Lung, small intestine, liver, and lymph nodes
Retroviruses-consensus	Lymph nodes, whole blood, spleen, lung
Rhabdovirus	Brain, lymph node, spleen, lung
Rotavirus	Small intestine
Sarcocystis spp	Lymph node, spleen, lung, brain, skeletal muscle, diaphragm, tongue
Sarcocystis neurona	Lymph node, spleen, lung, brain, skeletal muscle, diaphragm, tongue
Salmonella	Intestines, feces, isolate
Streptococcus	Isolate
Toxoplasma gondii	Lymph node, tongue, liver, lung, brain
Trichinella spp consensus	Tongue, diaphragm
West Nile virus	Brain, lung, lymph node, spleen
Western Equine Encephalitis virus	Brain, lymph node, spleen, lung,

APPENDIX VII: Marine mammal blubber sampling protocol

Tissue Sampling for Chemical Contaminant Analyses

Supplies for sampling will include:

- Four 12" x 13" solvent-rinsed Teflon sheets, solvent-rinsed 17-mL Teflon screw top vials for blood, and 4-mL amber vials for bile.
- Four 18 oz. Whirl-pak® bags (4.5" x 8.5") or Zip-Lock bags
- Ballpoint and marking pens

Sampling Protocol:

- Priority for collection of samples is: full-thickness blubber with skin, liver, muscle, blood (when possible), and bile.

Blubber collection procedures: It is important to use standardized sampling procedures so that, even when there are low levels of contaminants present, the differences may be attributed to biological processes and contaminant exposure and not to variation in the collection process. The following procedures are essential to prevent cross-contamination of tissues within an animal and ensure uniformity of samples among animals.

1. Collect full-thickness blubber with skin attached, if possible. This reduces variation caused by possible composition differences within tissues of the same animal. It also provides us with uniform samples and information from all participating organizations which can be directly compared based on the demographics of the animals. Sample size: blubber 10 – 20 g. NOTE: please collect full thickness blubber from the dorsal region (behind the dorsal fin).

2. If possible, rinse all instruments with isopropyl alcohol before each blubber sample is sampled. This will minimize cross-contamination of tissues.

3. Keep samples as cold as possible after collection. Some of the organic contaminants are volatile or are degraded by compounds released during cell death. In addition, lipids may be lost (e.g., leaching may occur) if the samples are not kept as cold as possible. To decrease changes in contaminant levels and lipid due to these processes, keep the samples on ice following the necropsy and freeze as soon as possible in a –20°C freezer or colder freezer (e.g., –80°C freezer). For fatty acid analyses, the samples should be stored in a –80°C freezer.

For tissue collection, use a stainless steel knife and clean and rinse the knife with alcohol between necropsies of each animal. Wrap each tissue sample in a pre-rinsed Teflon sheet

or in a pre-rinsed vial and then place sample into a labeled Whirl-pak® or a Ziploc bag.

Label each bag with:

- Animal ID Number
- Species
- Tissue Type
- Date Collected

Remove as much of the air as possible from the bag before it is sealed.
Place samples on ice. As soon as possible, freeze at lowest temperature available.
Please provide copy of full necropsy report.

Shipment of Samples:

Ship frozen samples on blue ice or ~5 lbs dry ice, early in the week via FedEx overnight to: Gina Ylitalo/Jennie Bolton, NWFSC, ECD, 2725 Montlake Blvd. E., Seattle, WA 98112-2097.

Call Gina (206-860-3325) or Jennie (206-860-3359) the day the samples are shipped with the invoice number for tracking, if necessary:

Marine Mammal Tissue Contaminant Analyses Environmental Conservation Division, Northwest Fisheries Science Center
National Marine Fisheries Service, National Oceanic and Atmospheric Administration
2725 Montlake Blvd. East, Seattle, WA 98112-2097
Phone: (206) 860-3325, FAX (206) 860-3335

APPENDIX VIII: Collection of samples for contaminant analysis

OBJECTIVES: To obtain relatively fresh tissues to determine concentrations of various contaminants.

APPROPRIATE SAMPLE SOURCES

All code 2 (fresh dead) animals and necropsy material.

SAMPLING PROTOCOL

1. Obtain 50- 75 grams (an absolute minimum of 10 grams is required for the basic analysis) of the following tissues:

Skin	Kidney	Heart
Blubber	Liver	Brain
Muscle	Lung	Testes/Ovaries

2. For metals analysis: Place in plastic collection bags, Whirl-pak® bags or conical tubes (NO ALUMINUM FOIL CONTACT).
3. For organics analysis: Place in brown amber hexane washed vials (NO PLASTICS CONTACT)
4. Label with animal ID and tissue type.
5. Samples should be frozen immediately (-80°C if possible).

Additional sampling

For genetic analysis: place about 2 g of tissue in a 2 ml plastic vial. Label appropriately. Freeze at -20 deg.

SHIPPING PROTOCOL

1. Ship with dry ice (preferred method) in a Styrofoam box as soon as possible via the fastest method, overnight is best. Please call as soon as possible to let us know that samples are on their way. (See contact info.) We will accept weekend deliveries; however call to get the weekend address.
2. Enclose a copy of official documentation (i.e. NMFS Level A in the case of stranders, Subsistence Harvest Data Forms, or other appropriate official documentation) detailing collector, location, circumstances, and animal information. (Our NMFS permit requires that we keep track of the origins of all of our tissues and document who obtained samples for us.)
3. If using FedEx, our Account number is 2546-3232-5.
4. Send samples to: Wise Lab, 476 Science Bldg,96 Falmouth St, Portland, ME 04103

CONTACT INFO

See our website at http://www.usm.maine.edu/toxicology/research/nmcl.html

Sandy Wise
Phone: 207-228-8047 E-mail: swise@usm.maine.edu

APPENDIX IX: Collection of samples for biotoxin analysis

Supplies

* Normal sized samples: 50-mL plastic centrifuge tubes or other plastic tubes
* Large samples: sealable/Ziploc plastic bags or bottles

Prey Fish

If possible, the species should be identified before freezing. Small fish should be collected and frozen, then shipped whole. For large species, stomach contents (whole stomach), liver and flesh should be sampled and stored separately. Minimum of 5 g (up to 50 g) flesh should be obtained. All tissues can be stored frozen (-20°C) in Ziploc bags until shipment on dry ice.

Mammals

Sampling of code 1 or 2 animals is preferred although code 3 animals and later are still useful for toxin analysis.

The most useful tissues/fluids for confirming biotoxin exposure are generally feces, urine liver, and stomach contents. However, samples from additional compartments (intestinal contents, kidney, lung, brain, whole blood, serum) are also valuable depending on the toxins of interest, and are useful for metabolism and body burden studies. All samples should be immediately placed in a cooler on ice and frozen (-20°C or -80°C) as soon as possible after collection. Samples should be shipped on dry ice to the laboratory for analysis. Prior to shipping samples, please contact receiving laboratory to ensure proper receipt of the samples and sample data.

All sample containers must be labeled with the animal ID and sample type in indelible ink (include date and species if space permits), such that labels remain legible when wet. When this is not possible, a small tag containing sample information inserted inside the sample container may be useful. A copy of the NOAA level A datasheet for each animal must accompany each shipment. If this datasheet is not available, please include the following data with the sample shipment: species and common name, stranding date (typically date of initial observation), stranding location (latitude/longitude in decimal degrees), animal length, weight, condition code, sex, and any additional relevant information. In addition, also send a digital version of data sheets and sample logs to your contact at the laboratory. Please include alternate animal IDs when multiple field ID numbers exist. Animal IDs should be consistent with those submitted to the national stranding database. Sample containers and volumes listed below are recommended but not required.

Urine - Collect a minimum of 1 ml urine, more if available (up to 50 ml). Store frozen (-20°C) in capped plastic centrifuge tubes.

Feces – Collect a minimum of 5 g (up to 50 g). Store frozen (-20°C) in capped plastic centrifuge tubes or other container suitable for freezer storage.

Intestinal contents - Collect a minimum of 5 g (up to 50 g). Store frozen (-20°C) in capped plastic centrifuge tubes or other container suitable for freezer storage.

Indicate which portion of the intestine was sampled (e.g. upper, mid-, lower intestine). Bile is also useful for analysis of lipophilic toxins.

Stomach contents – Collect a minimum of 5 g (up to 50 g) of solid or semi-solid contents if available. Store frozen (-20°C) in capped plastic centrifuge tubes or other container suitable for freezer storage. If stomach fluid only is available, collect at least 5ml in a plastic tube or vial. Indicate which portion of the stomach was sampled if applicable (e.g. pyloric, fundic, etc.). If stomachs contain undigested or partially digested prey or food items, please collect separately from gastric fluid. Any indication of prey species or identification of contents are very valuable to interpretation of analyses.

Liver, kidney, lung, spleen, brain – collect a minimum of 5 g (up to 50 g). Store frozen (-20°C) in plastic tubes, Ziploc bags or other leak-proof containers.

Serum – obtain serum by centrifugation (1500-3000 x g; 5 minutes) of whole, heparinized blood. The top layer is the serum. Collect >0.5 ml of serum and store frozen (-20°C) in a plastic tube.

Whole blood - Heparinized whole blood can be spotted directly onto blood collection cards and stored at room temperature in the presence of desiccant pouches. Blood cards with detailed instructions can be obtained from your contact at the Marine Biotoxins Program laboratory. If blood cards are not available, liquid whole blood may still be useful.

**Please note, if samples are to be analyzed for multiple algal toxins, a larger amount of sample is needed in order to perform multiple toxin extractions.*

APPENDIX X: Webpage resources for submission forms

NVSL: http://www.aphis.usda.gov/library/forms/pdf/VS_Form10_4.pdf

CAHFS Lab:
http://cahfs.ucdavis.edu/local-assets/pdfs/StandardSubmissionForm_6-13.pdf

UC Davis Marine Mammal Diagnostic Lab: http://www.vetmed.ucdavis.edu/whc/mehds/

Connecticut Diagnostic Lab:
http://cvmdl.uconn.edu/forms/CVMDL%20Submission%20Form.pdf

APPENDIX XI: Photography instructions and considerations

Capturing gross images allows the prosector to share what they saw after the fact. Once the carcass is left or cut, the images from the examination are lost unless captured for further review. Digital images are an easy way to quickly document lesions and changes for later discussion and consultation. In a worse-case scenario, almost everyone has access to a phone with camera abilities. The preferred method of image capture is a dedicated camera with 1-3 memory cards to facilitate capture of numerous large image files. If all else fails, use your cell phone!

General rules:

1. Photograph the dorsal fin, saddle patch, eye patch, and any other identifiable features (scars, coloration, etc) so the animal can be traced back to life history images.
2. Be sure to start with a **case identifier** in at least the first images so that the case can later be associated with the images
3. Take a **series of external images** to note carcass condition and location prior to initiating the examination
4. Put in **items for scale** – preferably a ruler but a pen, coin, or even a gloved hand will do to demonstrate how big something is.
5. Put scale items to the side rather than the center of the image – they are for scale. They should not obstruct the lesion.
6. Take **overall (wide angle) and close-up images** so that the lesions are easy to see and can be put into context.
7. Take **images *before* collecting samples** – but if you forget, getting an image after collecting samples is better than not getting an image.
8. **Remove blood/sand/debris** as best as possible to obtain a clean, distraction free photo
9. Make sure the **image is in focus** before moving on
10. Take images of the external surfaces, the mouth, the genitalia, the thorax, the abdomen, gastric contents, and anything that appears unusual or abnormal.
11. Download and label the images within 24 hours of the completion of the gross necropsy examination. Do not consider the exam completed until this is done.
12. Photo adjustments to consider post exam:
    - Adjusting brightness or contrast
    - Cropping the image
    - Modify background colors
    - Remove excess glare

Note: A photo identifier is attached at the end of this protocol for you to cut out and use as a scale and to identify the samples. You may want to print and laminate this or place in a plastic bag to facilitate cleaning.

APPENDIX XII: Ancillary imaging instructions

CT imaging

CT imaging of dead animals is indicated to evaluate for evidence of bone trauma, for evidence of thoracic injury or abnormal gas accumulations, and to a lesser degree to evaluate the soft tissues. The code of the cadaver is important and any evidence of autolysis/decomposition (including histological) means caution must be applied to any gas accumulations observed.

CT gantries have limitations. Table weight limitations are typically around 300lb, although modified tables are available at some veterinary schools that can accommodate far greater weight. The gantry size will also be a potential limitation. Gantry diameter for CT is typically 80-90cm in width (although some larger gantries do exist) but height is less than width because of the table, which can reduce size to 60cm in some cases. The cadaver cannot touch the gantry during scanning (there must be a small amount of air between the cadaver and the gantry for successful scanning). Knowledge of weight and size limitations prior to organizing scanning is strongly recommended. In smaller cadavers removal of the dorsal fin prior to scanning may permit whole body evaluation. In larger animals decapitation may be required in order to scan the head.

Imaging protocol multislice scanner:

- 0.5mm slice thickness through each individual ear, axial scan mode, bone reconstruction algorithm only
- 3mm slice thickness through the head and 3-5mm slice thickness through the thorax and abdomen using soft tissue and bone reconstruction algorithms. Helical scan mode can be used (pitch equivalent to single slice pitch of 1.4-1.7)

Imaging protocol single slice scanner:

- 1mm slice thickness through each individual ear (if possible) or both ears simultaneously, bone reconstruction algorithm only
- 3mm slice thickness through the head and 3-5mm slice thickness through the thorax and abdomen using soft tissue and bone reconstruction algorithms. Helical scan mode can be used with pitch 1.4-1.7

APPENDIX XIII: Oil spill concerns and sampling

Oil spill events can involve a variety of marine species. Killer whales are no exception. While killer whales have the ability to swim away from specific areas, oil events with wide dispersal can impact both water and prey quality and condition. The duration of effects may be long-lasting. Thus, if killer whales strand in areas where oil contamination is, was, or could be a concern specific determinations for the effects of oil are indicated. Oil spill response is generally overseen by specialists focused in this arena. Event reporting as well as response assistance is available 24/7 via:

http://www.vetmed.ucdavis.edu/owcn/

This web site provides information on contact personnel as well as forms for data collection and chain of custody reporting. It is an invaluable resource for oil spill events in the United States.

IMPORTANT: DO NOT enter an oiled area without proper training and personal protection

Oil spill response is considered an investigative action and all efforts should be conducted:

1. By personnel with knowledge of safety concerns and actions relative to oil and oil spills
2. By persons with knowledge and abilities relative to evidence collection
3. As a team effort with folks interested in investigating oiling events, the effects of oil, and the general health of killer whales in a specific area.

Measuring the effects of oil and petroleum-based products as well as dispersants may involve measuring for metabolic as well as toxic products. When such conditions are a consideration, collection of numerous tissues in Teflon-coated bags or within aluminum foil as dictated by the analysis to be performed will facilitate further evaluations. Photo documentation of lesions and conditions is especially important.

Chain of custody (COC) rules are an important element in oil spill sample management. Before logging any samples be sure you have discussed this effort with the event manager.

While they are still in draft form, NOAA's marine mammal oil spill response guidelines, which include an evidence collection protocol and a petroleum hydrocarbon tissue sampling protocol among other things, are available at:

http://www.nmfs.noaa.gov/pr/pdfs/health/eis_appendixl.pdf

Oiled Marine Mammal

Gross Necropsy Report

Spill Name:	
Animal Log #	
Level A Field #	**Tag #**
Species:	
Sex:	**Age:**
Weight:	kg. (estimate/actual)
SON:	emaciated 1 2 3 4 5 6 7 obese

Measurements:		Blubber depth	mm
SL cm	AG cm	UG cm	XG cm

Form completed by:	Date:	
Enforcemnent Officer:		
Strand/Capture location:		
Collecters Name:		
Intake date:		Euthanasia
Death date:	Time:	☐ yes
Post mortem date:	Time:	☐ no
Carcass Classification:	**Frozen**: ☐ yes ☐ no	
2- fresh, 3-fair (organs intact), 4-poor, 5- mummified		
Photographs: ☐		
Radiographs: ☐		

Clinical signs/diagnosis	
Antibiotics given	
Pertinent lab results	

GROSS NECROPSY ABNORMALITIES:

HYDROCARBON ANALYSIS SAMPLES		
bile	kidney	blubber/fat
blood	muscle	other:
urine	lung	
liver	intestine	

MICROBIOLOGY	**SWABS: other**
Lung ☐	
Liver ☐	
other ☐	

HISTOLOGY SAMPLES

lung	thyroid	ileum	kidney	mammary gland	muscle
trachea	tonsil	colon	ureter	adrenal	gonad
heart	tongue	pancreas	urinary bladder	skin	prostate
aorta	esophagus	spleen	urethra	eye (L/R)	uterus
pulmonary artery	stomach	liver	blubber	fat--site:	vagina
thymus	duodenum	gall bladder	bone marrow		cervix
salivary gland	jejunum	brain	spinal cord	whole repro	penis
other:					

LYMPH NODES:	
colonic	gastric
sublumbar	hepatic
inguinal	mediastinal
axillary	submandibular
mesenteric	tracheobronchial

Cause of death (preliminary diagnosis):

Examiner: Examiner's signature: Date:

APPENDIX XIV: Considerations and sampling for live stranded killer whales

Killer whales can and do strand live. When this happens, the events can be single strandings or associated with mass stranding events. In either situation, steps should be taken to assure:

1. Safety of humans in the area
2. Safety and humane care for the whales
3. Collection of scientific samples/data as feasible
4. Protection of wild populations

Management of live stranded animals includes efforts such as cooling, wetting, providing shade and even assuring proper orientation of the animal on its ventrum to facilitate breathing. The response efforts for killer whales are of a great magnitude owing simply to the size of many killer whales. The first step in managing such an event is to contact the local authorities that work with marine mammals. A team approach is generally the best first step to assure a positive result. Overall management of live strandings is beyond the scope of this work. However, general information is available through the Geraci and Lousbury's 2005 book *Marine Mammals Ashore*.

Two main considerations for sample collection

1. Safety – killer whales are large and strong. Even when beached, these animals have the ability to swing wildly and rapidly. This should always be considered first and foremost
2. Reasonability – If the animal is about to die or will be euthanized, many of these samples can be collected post-mortem from the fresh carcass.

Depending on the animal's physical condition, data and samples that can be collected include:

1. Morphometrics – specifically total length, dorsal fin height, pectoral fin characteristics
3. Image capture (Photos) including evidence of human interaction – nets, lines, ship strike injuries, prop wounds
4. Skin sample collection via scrape for genetics
5. Blood collection – ideal samples are approximately 50mLs and include 3 mLs for a CBC and the rest of the blood is allowed to clot and separated to collect serum. Serum should evaluated for blood chemistries and hormones and the remaining material should be banked for additional evaluations.
6. If possible, fresh whole blood should be collected for immunology studies – see research requests – Jeff Stott's lab.
7. Lesion sampling – scrapes, swabs for microbiology and molecular analysis

A note on euthanasia:

Unfortunately, circumstances arise where euthanasia is necessary for stranded animals. These include:

- Disabling injuries such as boat strike or penetrating wounds

- Significant hemorrhage
- Unresponsive hyperthermia
- Massive skin blistering and/or sloughing
- Loss of reflexes or muscle tone

Important considerations for euthanasia are that the process be quick and complete with minimal discomfort for the animal in question and safe for others in the area. Authorities overseeing stranding response may have a specific protocol for euthanasia and should be contacted. In some cases, allowing the animal to die naturally may be more humane than intervening. Final considerations are that the effort minimally impact scientific specimens and that the process be completed in such a manner as to appear professional to all public onlookers.

Ballistics may be used by trained individuals to avoid drug residue problems but are not recommended for larger killer whale. If such a manner of euthanasia is selected as best, the animal should first be curtained off to prevent public viewing. The site of the bullet entry is critical (see Harms et al., 2014 – below).

Routine euthanasia with barbiturate overdose is feasible for killer whales. Drug volume requirements should be carefully determined for animal size. Newborn killer whales are approximately 300-400 pounds. Adults can weigh 10,000-16,000 pounds. Drug residues including impacts on scavengers and long half-life in the aquatic environment are a consideration. Carcass disposal options may make barbiturate administration an unreasonable manner of euthanasia. If barbiturates are used, the preferred manner of administration is via cardiac stick following premedication with a sedative (Geraci and Lounsbury, 2005). Attempts to use the tail or peripheral veins may be thwarted by vascular shunting or shock. Without the use of a premedicating sedative, the animal may begin to rhythmically raise and lower the tail in a swimming motion. This motion, "flurrying" can propel the animal from its original position.

Given the large size of killer whales, methods developed for baleen whales may be more appropriate for this species. Alternate methods of euthanasia employ tranquilization with drugs such as midazolam, acepromazine, and xylazine followed by saturated KCl solution (Harms et al., 2014).

Harms, C.A., W. A. McLellan, M. J. Moore, S. G. Barco, E. O. Clarke EO, V. G. Thayer and T. K. Rowles. 2014. Low residue euthanasia of stranded mysticetes. Journal of Wildlife Diseases 50:63-73.

APPENDIX XV: Cetacean ear extraction and fixation protocol

Introduction

There is an increasing concern about the impacts of anthropogenic underwater noise on cetacean populations. For this reason, the analysis of the ears, especially for the presence of possible lesions in the organ of Corti represents a fundamental effort to assess the implication of acoustic trauma in stranding events. These are otherwise not detectable by routine histopathologic techniques.

The difficulty relies in obtaining fresh material rapidly fixed by proper solutions and in accessing the cochlea by decalcifying methods without affecting the inner ear soft structures.

The Laboratory of Applied Bioacoustics (LAB) has developed a fast decalcification protocol for use with most of the common odontocete species (see Figure 1) that allows a fast diagnosis of acoustic trauma.

Figure 1: Periotic bone decalcification results from a harbor porpoise (*Phocoena phocoena*) after an exposition of 26 hours with the rapid decalcifier RDO®. While other decalcifiers need around three months for a similar complex size, RDO® allows obtaining very fast results.

TYMPANIC-PERIOTIC COMPLEX

The tympanic and periotic bones house the middle and inner ear, respectively. These structures are partially fused forming the tympanic-periotic complex (Figure 2). The tympanic periotic complex is surrounded by aerial sinuses called peribullar sinuses and suspended in the peribullar cavity through ligaments that hold it fixed and acoustically isolated it from the rest of the bones of the skull, except in sperm whales and some beaked whales, which present the tympanic-periotic complex partially fused to the temporal bone.

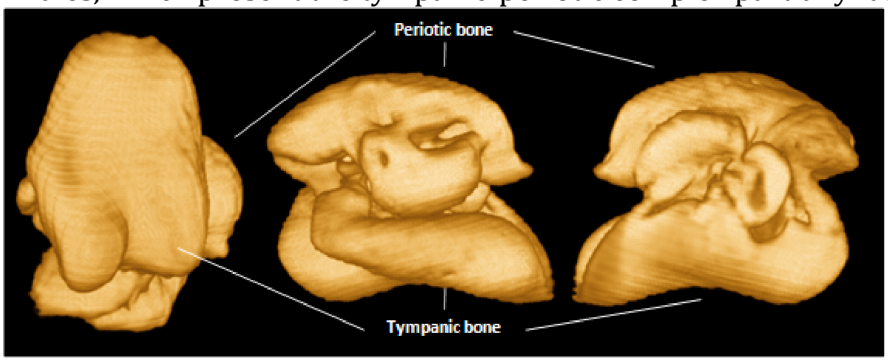

Figure 2.- Computerized tomography images 3D reconstruction from the tympanic-periotic complex of a bottlenose dolphin *Tursiops truncatus* in ventral, medial and lateral vision from left to right, respectively.

Extraction

1.With small specimens, it is recommended to cut the head off the animal for an easier manipulation (Figure 3).



Figure 3.- The position of the tympanic-periotic complex and auditory external meatus is indicated. The dotted line marks the incision path to separate the head from the rest of the body. Alternatively, the larynx and upper digestive system can be extracted from the head to facilitate the access to the ears.

2. Taking into account the localization of the tympanic-periotic complex (Figures 3 and 4), the easiest way to access the ears is to carefully remove the lower jaw.

Figure 4.- Sagittal cut of a bottlenose dolphin head in which the location of the tympanic-periotic complex is indicated.

3. Situating the head in dorsal recumbancy and removing the soft tissues and ligaments (Figure 5) faciltates tympanic-periotic complex extraction.

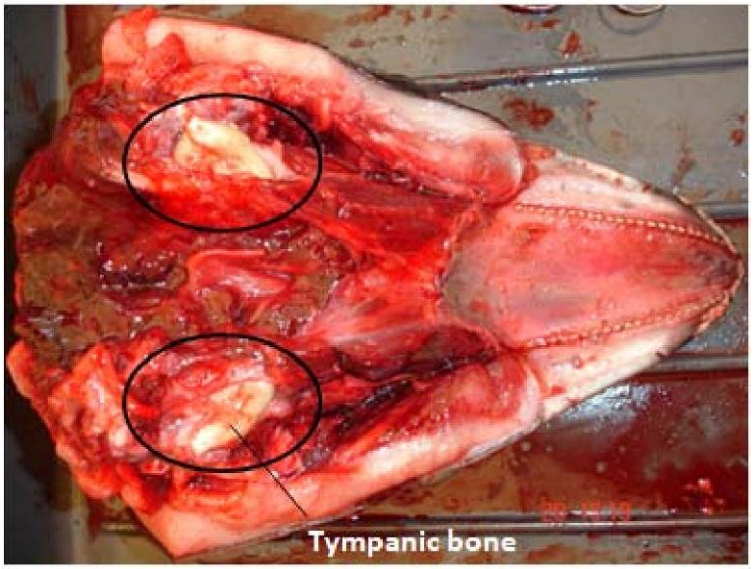

Figure 5.- Image taken during the necropsy of a *Phocoena phocoena*. This image reflects how the tympanic-periotic complex appears after removing the lower jaw (no effort has been made here to clean the area of extraction).

4. Incise gently around the tympanic-periotic complex with a small knife (a scalpel can be used for the final stage of the extraction) to cut the ligaments that maintain the ears in the paraotic sinus (see Figure 6).

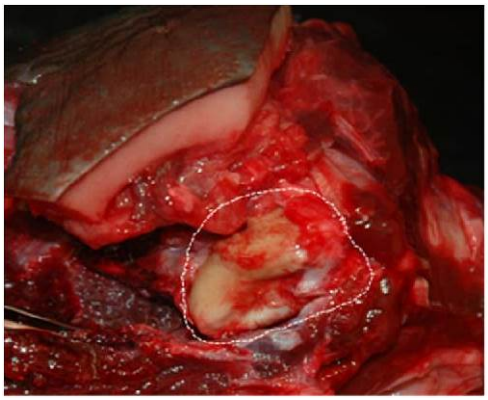

Figure 6.- Image taken during a *Phocoena phocoena* necropsy. The dotted line illustrates the location where the knife should be placed to extract the tympanic-periotic complex.

Fixation

5. At that stage, the ear could be fixed simply placing it in a fixative solution: glutaraldehyde 2.5% with 0.1M cacodylate buffer or 0.1M phosphate buffer (these solutions will be provided). The ears can also be injected with a mixture of paraformaldehyde 0.5% with glutaraldehyde 1% with phosphate buffer 0.1M or alternatively be injected with phosphate buffered formalin (pbf) 10%.

However, for a better result we recommend to follow the perfusion protocol.. If already experienced with the perfusion protocol, you may want to separate the periotic from the tympanic bone (Figure 7); cut the stapedial ligament and remove the stapes - if it does not come off easily, it helps passing a scalpel through the junction- make a small superficial

hole through the oval and round window membranes; using a soft catheter. Progressively and very slowly (with very little pressure) introduce the fixative solution (glutaraldehyde 2.5% with 0.1M cacodylate buffer) through the oval window and the round window until the solution passes out (Figure 8).

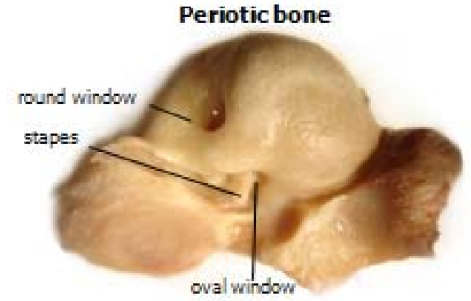

Figure 7.- Localization of the oval and round windows in the periotic bone.

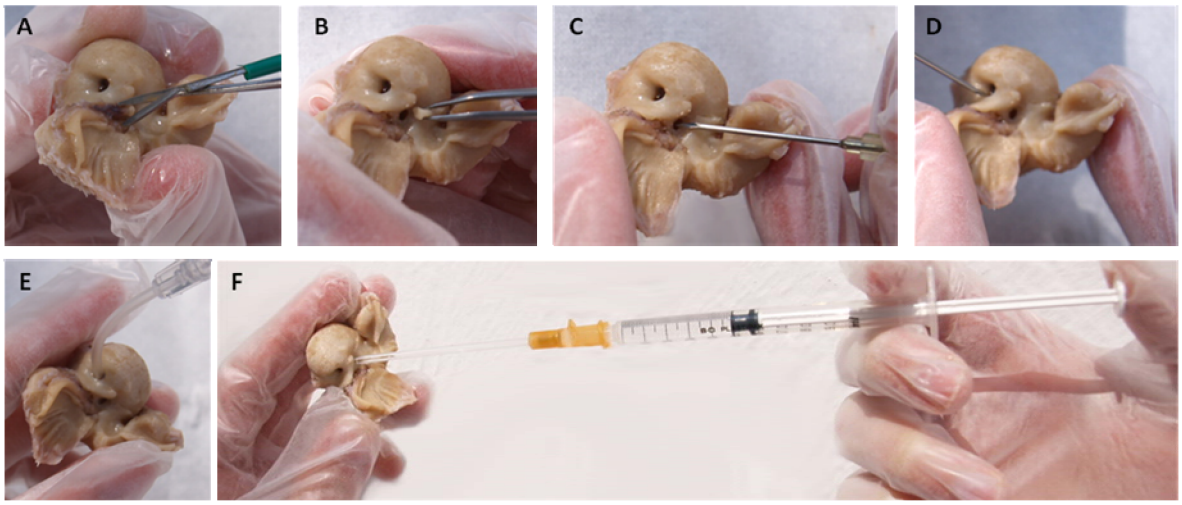

Figure 8. *Tursiops truncatus* periotic bone used to illustrate the injection process: A) cut of the stapedial ligament, B) stapes extraction, C and D) create a small hole in the oval and round window membranes respectively, E and F) very slow and progressive perfusion (with very little pressure) of the fixative through the oval window and the round window. Continue until the solution leaks out.

Place the ears in jars that contain liquid fixative (see point 6).

Contact

You can send the ears by express mail to the following address:
Stephen Raverty and Maria Morell
Animal Health Center
1767 Angus Campbell Road
Abbotsford., BC
CANADA, V3G 2M3

For question, do not hesitate to contact Maria Morell at 604-445-2013 or 604-822-2373
email: morell@zoology.ubc.ca

APPENDIX XVI: Barotrauma considerations and sampling protocol for gas bubbles

These instructions are a summary of the "protocol for gas sampling and analysis in marine mammals". For further information please visit the link to this article: http://www.nature.com/protocolexchange/protocols/2299

Material you need:

- 2-mL additive free glass tube (Kendall Monoject™ blood collection tube, ref: 301116)
- BD Vacutainer® one use holder (ref: 364815)
- Double pointed needle with a rubber barrier on the tube puncture side (BD Vacutainer® eclipse™ blood collection needle, ref: 368607).
- Disposable insulin syringes (BD Plastipak U-100 insulin ref: 329651).

Dissection

1. Carefully remove the skin and blubber minimizing damage to the major subcutaneous veins.
2. Examine the visible and larger subcutaneous veins for bubbles.
3. Take photos of veins with bubbles.
4. Sample bubbles*[1].

CRITICAL STEP: If pneumothorax is suspected, gas sampling could be done by using the Vacutainer® inserting the double pointed needle in between the ribs*[2]. Do not open thoracic cavity!

5. Open first the abdominal cavity carefully (try not to cut medium to large size vessels).
6. Examine the mesenteric and renal veins as well as the lumbo-caudal venous plexus for bubbles.
7. Take photos of bubbles within vessels.
8. Sample bubble's content "*in situ*" using the insulin syringes*[1].
9. Look for renal subcapsular emphysema.
10. Sample the subcapsular (gas) emphysema *in situ* using the Vacutainer® [2].
11. Sample intestinal gases using the Vacutainer® [2]. Preferably take at least three samples from different locations.
12. Open thoracic cavity. If desired, ribs could be disarticulated except the first 3 or 4 cranial ones. These ribs should be cut at 1/3 from the vertebral articulation.
13. Examine the coronary vessels.
14. Take photos of vessels and bubbles.
15. Sample bubbles*[1].
16. Follow up with routine necropsy protocol.

CRITICAL STEP: do not cut any systemic vein or sample organs until this step is reached.

17. Separate the head from the body.
18. You might disarticulate the mandible to have a better access to the pteryoid sacs.
19. Sample pterygoid sacs using the Vacutainer® *[2].

CRITICAL STEP: do not open the sinuses before gas sampling.

*[1]**Gas sampling from bubbles in veins**

CRITICAL STEP: place the vein under water whenever possible to avoid atmospheric air contamination.

1. Sample each bubble with a new dispensable insulin syringe (BD Plastipak U-100 insulin)
2. Inject the content immediately into a new Vacutainer® each time.
3. Label the Vacutainer® with volume recovered and location of the bubble.

CRITICAL STEP: Use one new syringe and one new Vacutainer® for each bubble.

***2 Gas sampling from cavities (intestine, pterigoyd air sacs) and gas associated lesions (pneumothorax and subcapsular emphysema)**

1. Couple the Vacutainer® plastic holder to the double pointed needle
2. Insert the needle into the cavity
3. Push the Vacutainer® against the other end of the needle
4. Leave for a few seconds
5. Remove the Vacutainer®
6. Remove the needle

CRITICAL STEP: If any of these steps is not done following this sequence, atmospheric air contamination will occur.

CRITICAL STEP: If steps from 3-13 are not done carefully following this sequence, air contamination will occur.

Storage and transport

1. Store the samples at room temperature and atmospheric pressure.
2. Store blank tubes with the samples; one blank per sample or a minimum of 3 blanks per animal.
3. If samples need to be transported in a plane, they should travel within the passenger cabin to prevent dramatic changes in atmospheric pressure that might alter the vacuum tubes, or use a plastic housing resistant to negative pressures (PREVCO™ subsea housing).

Appendix XVII: Dorsal fin measurement and collection request

Background:
The dorsal fin and detailed measurements of the fin and surrounding tissues are requested for use in the development of satellite tag attachment methods as part of a collaborative study. We have prioritized the list of requested materials and data from highest to lowest, as we recognize stranding responses are often limited in scope and resources. For more information contact Greg Schorr (gschorr@cascadiaresearch.org, 206.931.4638), Robin Baird (rwbaird@cascadiaresearch.org, 425.879.0360), Russ Andrews (RussA@alaskasealife.org) or Brad Hanson (brad.hanson@noaa.gov, 206.300.0282).
Note: Specimens must be freshly dead or only slightly decomposed (code 2).

1. **Dorsal fin collection (highest priority)**
   - Remove the dorsal fin including the area 15cm (6 inches) anterior, posterior, and lateral to the dorsal fin, down to the sheath/muscle interface
   - If possible, cover with A&D ointment (or similar non-petroleum based grease) prior to freezing. If covering is not possible, wrap in plastic and freeze.

Note: A FedEx number can be provided for shipment (contact Brad Hanson), or reimbursement of shipping cost can be arranged if necessary. Coolers or boxes can be returned upon request.

2. **Blubber/muscle measurements (lower priority)**
   - Measure the length of the dorsal fin from the anterior and posterior insertion points (See figure 1, distance "D").
   - Measure and record thickness of the blubber and thickness of the muscle at the following sites:

Site 1: From the anterior insertion point of the dorsal fin, measure 1/2 of "D" towards the head.
Site 2: From the posterior insertion point of the dorsal, measure 1/2 of "D" caudally.
Site 3: On one side (either the left or right, whichever is more convenient), from the anterior insertion point, measure 1/2 "D" laterally towards the midline.

Figure 1:

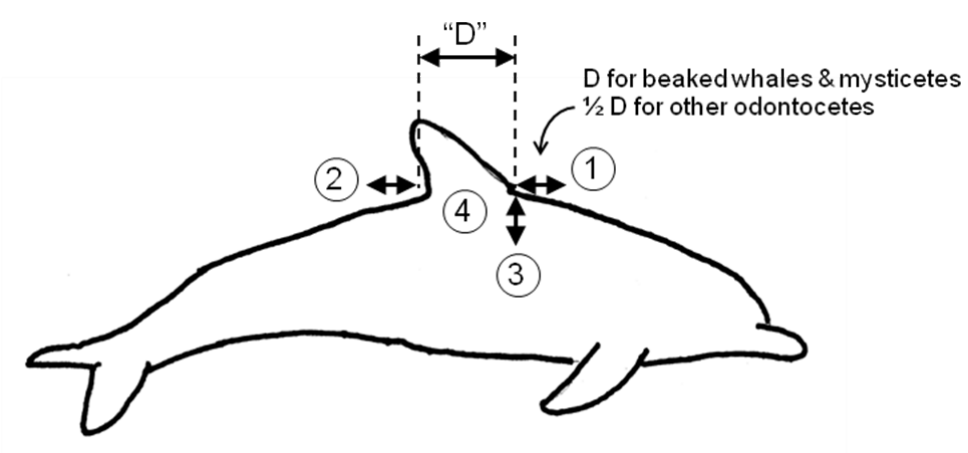

3. **Distance to dorsal process (lowest priority)**
   - Measure and record distance from epidermis to the dorsal process at the following site (figure 1 and 3):

Site 4: Measure 1/2 of the length of the dorsal between the anterior and posterior insertion point (figure 1 and 3). Site 4 should be on the body side of line between the anterior and posterior insertion point, not on the dorsal fin. Measure depth from the epidermis to the dorsal process at an angle perpendicular to the tangent of the body (figure 3).

Figures 2 (left) & 3 (right):

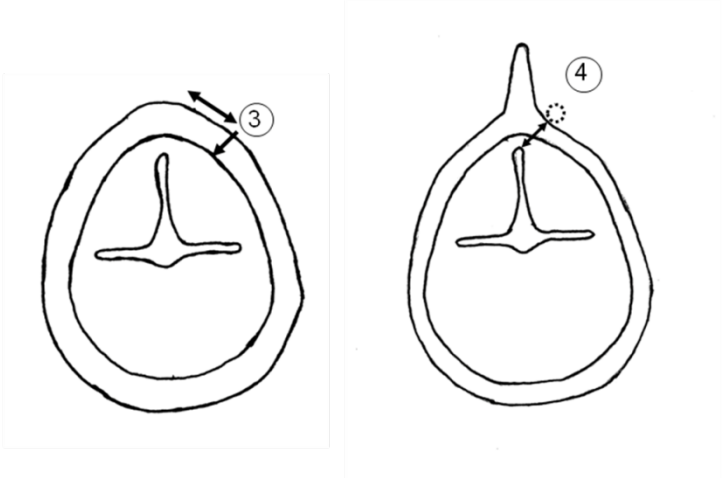

APPENDIX XVIII: Archiving tissue samples

Archiving tissues is critical. Despite the attempt to include all desired sampling in this necropsy protocol, inevitably, there will be requests for further testing. Efforts have been made to set up killer whale tissue respositories in the United States and Canada. Both contain -80C freezers with back-up generators and recording of daily freezer temperatures.

Researchers that have collected tissues for archiving and would like to deposit them in a killer whale tissue bank should contact:

In the United States:
Dr. Brad Hanson, NOAA/NMFS/Northwest Fisheries Science Center, 2725 Montlake Blvd. E, Seattle, WA 98112, Office phone: 206-860-3220, Fax: 206-860-3475, Cell Phone 206-300-0282, Email: **Brad.Hanson@noaa.gov**

In Canada:
Dr. Stephen Raverty, Animal Health Center 1767 Angus Campbell Road, Abbotsford, BC, Canada V3M 2G3 Phone, work: 604-556-3003 Phone, work: 800-661-9903 Email: **Stephen.Raverty@gov.bc.ca**

APPENDIX XIX: Lesion Description Form

Field ID: _____ Date: _____

LESION DESCRIPTION					PHOTOS			SAMPLES	
Lesion	Physical Location	Color Description	Comments	Size	on animal before sampling	of tissue extracted from animal	of animal after sampling	Histo	Other

APPENDIX XX: NOAA Fisheries NW Region Killer Whale Stranding Protocol

November 2012

**Any stranding response with ESA-listed Southern Resident killer whales must be coordinated with NOAA Fisheries and authorized under the National Marine Mammal Health and Stranding Response Program Permit.*

Southern Resident killer whales were listed as endangered under the Endangered Species Act (ESA) in 2005. This protocol was developed to implement actions in the *Recovery Plan for Southern Resident Killer Whales* [Section 4.2.1] and establishes a protocol for coordinating response to a killer whale stranding event. Section 4.2.1 Information from all killer whale stranding events is important to inform recovery of Southern Residents. The protocol also contains steps to ensure compliance with the terms and conditions of the Marine Mammal Protection Act and Endangered Species Act Research and Enhancement Permit 932-1905 issued to the Marine Mammal Health and Stranding Response Program.

1. Confirm the stranding and species identification via photos, reliable source, or by having a network member respond to the stranding.
2. Please notify Kristin Wilkinson, NOAA Fisheries of the stranding at 206-526-4747 office, 206-550-6208 cell. Please provide as many details as possible and email photos to Kristin.Wilkinson@noaa.gov as soon as they are available.
    a. If you are unable to reach Kristin or do not hear from her within 30 minutes please contact:
        i. Brent Norberg 206-526-6550 office, 206-909-3771 cell
        ii. Lynne Barre 206-526-4745 office, 206-718-3807 cell
        iii. NOAA Fisheries will contact Teri Rowles at NOAA HQ (301-427-8448) once the stranding is confirmed, Brad Hanson (206-860- 3220 office, 206-300-2082 cell) at the Northwest Fisheries Science Center, NOAA Office for Law Enforcement (206-526-6133), and Department of Fisheries and Oceans (604-666-9965) as necessary.
3. If the stranding is confirmed as a killer whale please take photos of the animal, gather as much information as possible, and attempt to limit public access to the animal. If it can be done safely, it is important to secure the carcass of dead stranded killer whales so it is not taken out with the subsequent tide.
    a. Photo Identification: Photos of the dorsal fin, saddle patch, eye patch or other identifying feature should be a priority (preferably left side) to assist with identifying type of killer whale (i.e., Southern Resident, Transient, or Offshore) and the individual identity of the whale. If possible, use of a white sheet as a backdrop behind the subject being photographed helps contrast these anatomic features.
    b. Acoustic Identification: If the animal is alive and floating in the water, or accompanied by con-specifics and has not been identified to ecotype or individual, in addition to photographs it would be worthwhile to contact the Northwest Fisheries Science Center or Center for Whale Research (contacts listed below) to assist with obtaining an acoustic recording.

4. Please collect information on location and site access for transfer via boat towing to closest boat ramp, removal by vehicle, or on-site necropsy.
5. NOAA Fisheries staff or the network coordinator will arrange a conference call if necessary to discuss the stranding. Participants may include experts from the following list of stranding network members and researchers that have specialized experience and have expressed an interest in participating in killer whale stranding response:

Name	Organization	Office	Cell
Brent Norberg	NOAA Fisheries	206-526-6550	206-909-3771
Lynne Barre	NOAA Fisheries	206-526-4745	206-718-3807
Kristin Wilkinson	NOAA Fisheries	206-526-4747	206-550-6208
Brian Gorman	NOAA Fisheries Public Relations	206-526-6613	206-604-6399
Brad Hanson	NWFSC	206-860-3220	206-300-0282
Dawn Noren	NWFSC	206-302-2439	206-423-0215
Candi Emmons	NWFSC	206-302-2432	206-251-2733
Joe Gaydos	SeaDoc Society	360-376-3910	360-914-1083
Stephen Raverty	BC Animal Health Center	604-556-3026	778-839-6916
John Calambokidis	Cascadia Research	360-943-7325	206-280-5320
Jessie Huggins	Cascadia Research	360-943-7325 x111	206-949-7924
Steve Jefferies	WDFW MMI	253-589-7235	253-380-4963
Dyanna Lambourn	WDFW MMI	253-589-7235	253-208-2427
Jen Olson	Whale Museum	360-378-4710 x27	360-472-1852
Dave Ellifrit	Center for Whale Research	360-378-5835	360-317-5287
Ken Balcomb	Center for Whale Research	360-378-5835	360-472-1707
Pete Schroeder	Global Research and Rescue	360 683-7437	
Susan Berta & Howie Garrett	Orca Network	1-866-672-2638	360-661-3739
Stephanie Norman	Central Puget Sound MMSN		206-321-0249
Local stranding network members covering area of stranding; see GIS maps for contact information.			
Inform Washington Department of Fish and Wildlife Law Enforcement 360-902-2936 if necessary.			
Inform US Coast Guard 206-587-0307 if necessary.			

6. If a conference call is necessary the following topics will be covered:
    a. Identification of an on-site coordinator, this will be the local Stranding Coordinator (Letterholder), NOAA MMHSRP Staff, or other Permit designee. The on-site coordinator will oversee field response, data

collection, and specimen disposition in consultation with the Permit Holder or designated Co-investigator.

i. The On-site coordinator will be responsible for identifying key staff which would include:
    1. Lead Veterinarian – Responsible for conducting a health assessment on the animal and overall care during the networks response.
    2. Field Logistics – Responsible for responding to the stranding, managing volunteers and their roles at the site, and communicating relevant information to NOAA Fisheries.
    3. Data Manager – tracking specimen disposition and samples. Managing all data that is collected during the response and sharing with the appropriate parties.
    4. Necropsy Lead (if necessary) – lead and conduct the necropsy of the animal. Work with the data manager on specimen disposition and where samples will be sent for analysis.

b. Identify next steps for response (see Field Response below)

c. Communication with interested parties and preparation for media inquiries

7. Field Response

a. For a dead animal:

i. A necropsy team will be formed to conduct a full necropsy. The necropsy lead should determine where the necropsy will take place (lab or field), the condition code (fresh, moderate, advanced), and what samples will be collected (including duplicates, samples to be archived, and samples for other researchers). The Killer Whale Necropsy and Disease Testing Protocol should be followed.
    1. The protocol can be found at: http://www.vetmed.ucdavis.edu/whc/pdfs/orcanecropsyprotocol.pdf
    2. The protocol provides an equipment checklist, logistics and necropsy recommendations, resources, disease information, etc.

ii. Previous information on dead stranded killer whales is listed in the table below. This information may be requested by the media.

b. For a live animal:

i. Live animal response is logistically complex, potentially dangerous for personnel and the animal, and is expensive. Review the below considerations, determine the level of intervention necessary, and consider what resources your network has to offer for response.
    1. Considerations for assessing a live stranded cetacean:
        a. Human safety is paramount and access to the animal should be restricted to qualified and authorized individuals.

b. Can the animal be moved from the beach into deeper water on the next high tide? When is the next high tide?
c. Is there any vessel support available to assist?
d. Is there a harness available to place the animal in to tow it out to deeper water?
    i. Contact at Point Defiance Zoo and Aquarium is Dr. Karen Wolf at 253-404-3639 (Office) or 253-381-3115 (Cell)
    ii. If a harness is not available one can be made out of Sampson line and some floats. See Figure 6.10 in Marine Mammals Ashore, A Field Guide for Strandings. Geraci & Lounsbury, 2005.
e. If the animal is going to stay on the beach for quite some time, keep the skin wet and if necessary, apply a salve to keep the skin from drying out.
    i. An application of zinc oxide will protect skin from sun and windburn and help prevent dehydration. Skin already damaged should be kept moist, shaded, and protected with zinc oxide, antibiotic ointment, or petroleum jelly. (Geraci & Lounsbury, 2005). These products can be purchased at any drug store.
    ii. In cold weather provide shelter from wind and precipitation, cover the extremities with a cloth dampened with mineral or vegetable oil. (Geraci & Lounsbury, 2005)
    iii. In warm weather or sunny conditions, pay particular attention to keeping the appendages wet to facilitate heat loss (when safe and accessible.)
    iv. Collect a blood sample and conduct hematology and clinical chemistry as soon as possible. Viral and bacterial swabs from the blowhole, mouth, rectum, and any lesions are also helpful. Gas analysis and an ultrasound may also be considered. Also consider taking a biopsy sample for genetics analysis.

2. Is there a tracking device available to monitor the animal after release?
3. Network members must coordinate with NMFS/NWR to develop and implement a media plan for disseminating investigation information.

a. NOAA Public Relations, Brian Gorman (206-526-6613) and Janet Sears (206-526-6172) are available to assist.

8. After the necropsy of a dead animal or release of a live animal is complete, the stranding network group responsible for the geographic area where the event occurred should fill out a Level A report (and provide Level B data) for the stranding response and close the loop with media contacts and with everyone involved. A post-response de-briefing with the response team, NOAA Fisheries and other parties is recommended. During the de-briefing follow up actions such as sample analysis, writing reports, and final disposition of parts (i.e., skeleton) should be discussed.

Veterinarian Contacts in the Northwest Region for Killer Whale Assessment

Name	Organization	Location	Phone Number	Email
Dr. Joe Gaydos	SeaDoc Society	Orcas Island	360-376-3910 Office 360-914-1083 Cell	jkgaydos@ucdavis.edu
Dr. Stephanie Norman	Central Puget Sound MMSN & Marine-Med	Bothell, WA	206-321-0249	whaledoctor@gmail.com
Dr. Marty Haulena	Vancouver Aquarium	Point Roberts, WA	415-847-2781 US Cell 604-831-9550 CA Cell	Martin.Haulena@vanaqua.org
Dr. Kelly Helmick	Woodland Park Zoo	Seattle, WA	206-605-9040	kelly.helmick@zoo.org
Dr. Pete Schroeder	East Jefferson Co. MMSN	Sequim, WA	360-683-7437 Cell 360-670-6345	jpsmmra@olypen.com
Dr. Lesanna Lahner	Seattle Aquarium	Seattle, WA	206-707-2613	L.Lahner@seattleaquarium.org

***For killer whale strandings in other parts of the world**

New Zealand: Call Ingrid Visser, Orca Research Trust, ingrid@orca.org.nz, P.O. Box 402043, Tutukaka, Northland, 0153, New Zealand; + 64 (0)9 43 43 043 office / home , + 64 (0)274 727 627 mobile, (NZ only 0800 733 7722)

*Please contact us if you would like to be added as a contact person for your region.

Appendix XXI: Protocol for examining killer whales for signs of human interaction

The following form should be used to examine killer whales for signs of human interaction. If you would like more information on the identification of human interaction in marine mammals or specific details regarding filling this form out, please see the complete paper from which this form originates:

Moore, K. T. and S. G. Barco. 2013. Handbook for recognizing, evaluating and documenting human interaction in stranded cetaceans and pinnipeds. NOAA Technical Memorandum, NOAA-TM-NMFS-SWFSC-510, 102 pp.

Available on-line at:
http://swfsc.noaa.gov/publications/TM/SWFSC/NOAA-TM-NMFS-SWFSC-510.pdf

APPENDIX XXII: Fetal examination and sample management

Killer whale fetuses can be encountered as gestational fetuses within dead stranded pregnant females or as abortions or still births. Killer whale pregnancy can last 15-18 months. Determining if a small-sized animal is a neonate or a fetus can be difficult. Fetal decomposition can occur in utero or after expulsion. A fully developed, full sized animal can be delivered as a stillborn due to fetal death just prior to or at parturition. Because of these complexities, a thorough examination and sample collection is critical for fetal review.

A killer whale can be identified as fetus if:

- The developing fetus is present within a gravid uterus or birth canal or the abdomen of an adult female with an internal uterine rupture
- The fetal development is incomplete

Findings that **suggest** but do not confirm the animal as a fetus include:

- The body is less than 2.5m (8.2 feet) in length or 182 kg (400 pounds) in mass.
- Gastric content includes amnionic fluid and no milk
- Fetal folds are present

Taking a history on a fetus:

1. Maternal information including age, overall health, past pregnancies and their out comes as known
2. Environmental situation including weather and conspecific events – is aggression/trauma a concern?
3. Paternal identity or possibilities
4. Any observed situation related to abortion – time/character of anorexia, contractions, straining, delivery complications, additional cases

Fetal/Tissue Examination:

1. Collect placenta, fetus, and amniotic fluid
2. Measure fetal length, weight, the distance between the eyes, note developmental features, estimate degree of decomposition (fresh, mild, moderate, severely deteriorated, mummified)
3. Examine the skin for meconium (green or orange) staining. Likewise, look for tan discoloration of the trachea and bronchi suggesting meconium inhalation.
4. Examine the placenta for completeness of expulsion. If the placenta is presented in sections, try to piece together to form a complete membrane. Weigh, measure the length and # twists in the umbilical cord. Extra support can be found at : http://placentation.ucsd.edu/killerwhalefs.htm

Specific points of examination:

Note: any abnormalities, photograph and sample for formalin

1. Observe for any malformations or organ abiotrophies (when something does not form)

2. Observe for any swelling/edema or hemorrhage – especially in the head/neck region that might suggest dystocia
3. Specifically observe the umbilicus for swelling/hemorrhage
4. Observe ribs and skull for swelling/fractures/irregularities
5. Observe organs for irregularity, firmness, necrosis, meconium staining, or abscesses
6. Examine brain for completeness; rule out hydrocephalus
7. Observe placenta for thickening, thinning, or discoloration
8. Specifically note the character of gastric contents – amnionic fluid versus curdled milk

Collection of Fetal samples for freezing/ancillary testing:

Abdominal/thoracic fluid (5 ml)
Blood (3-5ml)
Brain
Gastric fluid (5-10 ml)
Kidney
Liver
Lung
Pericardial fluid (3ml)
Spleen
Thymus
Tissue pool (liver, spleen, lung, brain) in viral transport media
Tissue pool (liver, spleen, lung, brain) in RNA later
Umbilical cord/placenta

Fetal samples for culture:

Stomach content – aerobic, anaerobic, fungal, and *Campylobacter* sp. cultures
Liver – aerobic culture
Lung - aerobic culture
Umbilicus – aerobic
Other cultures as indicated by gross findings

Fetal samples for 10% neutral buffered formalin:

brain
bladder
colon/rectum
gonads
esophagus
heart
intestines
kidney
larynx
liver
lung pituitary gland
lymph nodes
parathyroid
placenta (see exam details below)
skeletal muscle
skin
spleen
stomach
trachea
thymus
thyroid
tonsil
umbilicus

Placental exam:

1. Save sections of placenta, amnionic sac, and umbilicus in 10% neutral buffered formalin
2. Save two 10 x 10cm sections of placenta frozen in whirl paks
3. Save small section (1cm x 1cm – cut into fragments) of placenta in RNA later and freeze
4. Save small section in EM fixative (Gluteraldehyde or Karnovski's solution)

APPENDIX XXIII: Morphometric analysis of stranded killer whales

Note: If there are time or constraints or safety issues, please collect at least the data points in **BOLD**

Observer_____**Date**_____

Identification number_____**Gender**_____**Weight**_____

MEASUREMENTS, BODY (specify units of measure used_____)

1	**Total straight length, snout to notch**			13	Snout to genital slit	
2	Snout to center of eye (left)			14	Snout to anus	
3	Length of gape (left)			15	Eye to blowhole (center)(left)	
4	Snout to apex of melon			16	Projection of the lower jaw	
5	Snout to ear (left)			17	**Blubber thickness*, mid dorsal**	
6	Center of eye to ear (left)			18	**Blubber thickness*, mid lateral**	
7	Center of eye to angle of mouth			19	**Blubber thickness*, mid ventral**	
8	Center of eye to eye (curved - brow)			20	Girth at eye	
9	Snout to center of blowhole			21	**Girth at axilla**	
10	Snout to flipper (left)			22	Girth at leading edge of dorsal	
11	Snout to tip of dorsal fin			23	Girth at anus	
12	Snout to center of umbilicus			23a	Girth___ cm before notch	

*Blubber thickness is measured at line 22- just cranial to the dorsal fin

MEASUREMENTS, APPENDAGES (specify units of measurement____)

29	**Flipper length (ant) (left)**			33	Length of dorsal fin base	
30	**Flipper length (post) (left)**			34	Width of flukes (straight)	
31	Maximum width of flipper (left)			35	Length of flukes (left)	
32	**Height of dorsal fin**			36	Depth of fluke notch	

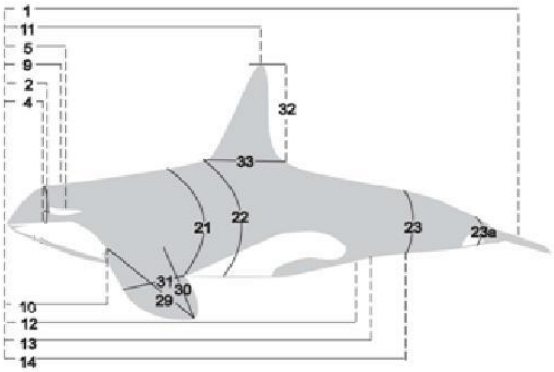

APPENDIX XXIV: Gross pathology data recording form

Event Information

Stranding date: _____

Recovery date: _____

Euthanized / Died

Date & time of death: _____

Necropsy date & time: _____

Storage prior to necropsy: _____

Stranding location: _____

Lat/Long:_____ N / _____W

Animal Info

Sex: M / F / CBD

Length: _____cm / in / ft

Weight: _____lbs / Kg

Pup / Calf / YOY / Sub-adult / Adult / CBD

Condition at stranding: 1 2 3 4 5 6

Condition at necropsy: 1 2 3 4 5 6

Human Interaction: Yes / No / CBD

Mass Stranding: Yes / No Number of animals:_____

Brief History:

Necropsy Observations: Please note general observations of color, condition, textures, etc. even when utilizing NA= not applicable, NE= not examined, NSF= no significant findings, NVL= no visible lesions. List weights (g) next to each organ examined.

External Exam (Please note all lesions and if sections of animal are visible or obstructed – typically due to inability to move/rotate for viewing).

Body Condition: robust / thin / emaciated / CBD
Skin (fetal folds?, color, condition, wounds, scars, parasites – please diagram all changes):

Dorsal surface:

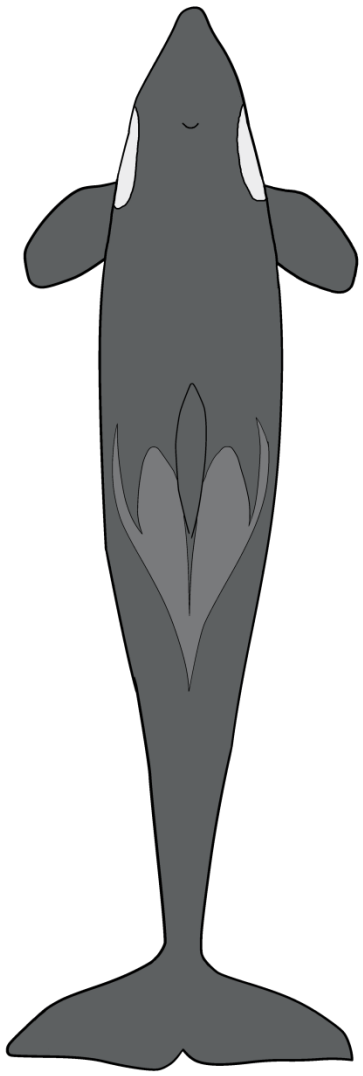

Ventral surface:

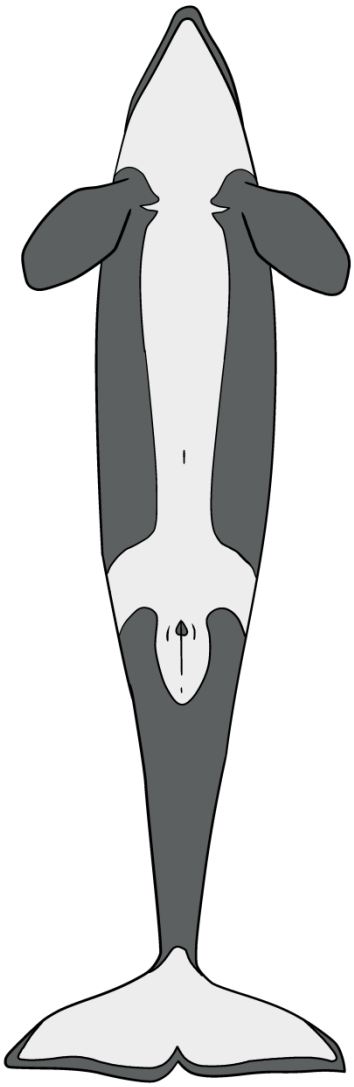

Right side:



Left side:



Blowhole:

Mouth (tongue, teeth)/ Mucous membranes (color):

Eyes (discharge, color, ruptures): **(R)** **(L)**

Ears: **(R)** **(L)**

Genital slit/anus/mammary openings/umbilicus:

Musculoskeletal system (bones, joints, muscles)

Blubber:

Diaphragm:

Skeletal:

Circulatory System

Pericardium:

Heart: (weight - kg)

Vessels:

Pulmonary System

Larynx:

Trachea:

Bronchi:

Lungs (color, condition, edema, congestion, consolidation, granulomas, emphysema, lesions):
(R)(Weight kg)

(L)(Weight kg)

Tracheobronchial Lymph:

Gastrointestinal System

Esophagus:

Stomach (contents, ulcers, mucosa, parasites):

Small Intestine:

Large Intestine/colon/anus:

Peritoneum, mesentery, omentum:

Hepatic / Pancreatic

Liver (weight kg, color, congestion, lesions, size):

Bile Duct / Pancreaticoduodenal duct (color, amount):

Pancreas:

Associated Lymph nodes:

Urinary / Reproductive Systems

Kidneys (reniculi differentiation, color, condition):

(R)(weight kg)

(L)(weight kg)

Bladder:

Testes / Ovaries: Immature / Mature

(R) Weight: kg, Lx W x H cm:

(L) Weight: kg, Lx W x H cm:

Mammary glands:

Uterus / Cervix / Vagina:

Pregnant: Y / N / NA (male) / CBD

Lymphatic System

Spleen (weight kg):

Scapular Lymph node:

Mesenteric Lymph node:

Other Lymph (list location):

Endocrine System

Adrenals:
(R) **Weight:** **g Lx W x H cm:**

(L) **Weight:** **g** **Lx W x H cm:**

Thyroids /parathyroids: (weights)

Pituitary gland:

Nervous system
Spinal cord:

Brain: **weight:**

Peripheral nerves:

Other
Peritoneal cavity:

Abdominal cavity:

Pterygoid Sinuses:

Thoracic cavity:

Internal Parasites (location, type, #)

SUMMARY- Differential Diagnosis from Gross Exam:

CARCASS DISPOSITION:
Soft tissue:

Skeleton:

PROSECTORS (list names and primary prosector signature)

SAMPLES/Disposition (Use attached list)

PHOTOS/VIDEO

Camera	Roll#	Frames:	Description:

APPENDIX XXV: Checklist - tissues to collect from a Code 2 or 3 killer whale carcass

Definition of Code 2: Freshly dead animal; skin firm, organs fresh

Definition of Code 3: Moderate decomposition; skin firm, body swelling, skin deterioration, often advanced predation, organs red and soft but discernible

Tissue	Histopathology	Culture swab	Dry swab	Ancillary testing	Cytology
Skin, multiple sites	☐ ☐ ☐			☐	
Blubber	☐			☐ ☐ ☐	
Dorsal fin				Intact ☐	
Head				Intact ☐	
Eye	1 globe ☐			5-10 ml ☐	
Conjunctiva	☐	☐ ☐	☐		
Ears				Intact ☐	
Ear, fat	☐				
Blowhole	☐	☐ ☐ ☐ ☐	☐		Scrape ☐
Mandible	(fat) ☐			Intact ☐	
Teeth (1-2)				Intact ☐	
Brain- cerebrum	☐ ☐ ☐	☐		☐ ☐ ☐ ☐	
Brain- cerebellum	☐ ☐ ☐			☐ ☐	
Brain- brainstem	☐			50 gm ☐	
Pituitary gland	☐			half ☐	
Spinal cord	Thoracic ☐ Lumbar ☐			Thoracic ☐ ☐ Lumbar ☐ ☐	
Brachial plexus	☐				
Oral mucosa	☐				
Oropharynx	☐	☐	☐		
Tonsil	☐			☐ ☐	
Tongue	☐			50 gm ☐ ☐	
Lymph node, multiple sites	☐ ☐	☐ ☐	☐	50 gm ☐ ☐	
Trachea	☐	☐	☐	5 cm ☐	
Thyroid gland	☐			1 whole ☐ ☐	
Parathyroid gland	☐			☐	
Thymus	☐			50 gm ☐ ☐ ☐	

Tissue	Histopathology	Culture swab	Dry swab	Ancillary testing	Cytology
Bronchus	☐	☐	☐	5 cm ☐	
Lung	☐ ☐	☐ ☐ ☐	☐	50 cm ☐ ☐	
Heart blood				50 ml ☐	
Pericardium	☐	☐		50 gm ☐	
Pericardial fluid				10 ml ☐	☐
Heart	☐ ☐ ☐			50 gm ☐	
Aorta and vena cava	☐				
Diaphragm	☐			100 gm ☐	
Liver	☐ ☐			100 gm ☐ ☐ ☐	
Bile				10 ml ☐	☐
Spleen	☐ ☐	☐		☐ ☐ ☐	
Pancreas	☐			50 gm ☐	
Stomach	☐ ☐	☐		Ingesta ☐ ☐	
Small intestine	☐ ☐	☐ ☐		Ingesta ☐ ☐	
Colon	☐	☐ ☐ ☐		Ingesta ☐	
Adrenals	☐ ☐			50 gm ☐	
Kidney	☐ ☐			100 gm ☐ ☐ ☐	
Ureter	☐			☐	
Urine				50 ml ☐ ☐	
Urinary bladder	☐			☐	
Umbilicus	☐	☐			
Mammary gland	☐	☐	☐	100 gm ☐	Aspirate ☐
Milk				50 ml ☐	
Genital slit	☐	☐ ☐	☐		
Urogenital canal	☐	☐	☐		
Vagina	☐	☐ ☐	☐		
Uterus	☐	☐ ☐	☐	50 cm ☐	
Ovary	☐	☐	☐	Intact corpora ☐	
Oviduct	☐			2-4 cm ☐	
Penis/testes	☐	☐ ☐	☐		
Accessory sex glands	☐				
Skeletal muscle	☐			100 gm ☐ ☐ ☐	
Joint fluid		☐			☐
Rib/Bone marrow	☐			100 gm ☐	☐
Peripheral nerve	☐				

APPENDIX XXVI: Checklist - tissues to collect from a Code 4 killer whale carcass

Definition of Code 4: Advanced decomposition; organs difficult to clearly discern, skin sloughing, often swollen and expelled GI tract or repro organs

Tissue	Histopathology	Culture swab	Dry swab	Ancillary testing	Cytology
Skin, multiple sites	☐ ☐ ☐			☐	
Blubber	☐			☐ ☐ ☐	
Dorsal fin				Intact ☐	
Head				Intact ☐	
Conjunctiva	☐	☐ ☐	☐		
Ears				Intact ☐	
Blowhole	☐	☐	☐		Scrape ☐
Teeth (1-2)				Intact ☐	
Brain- general	▭ ▭ ▭	▭		▭ ▭ ▭ ▭	
Oral mucosa	☐				
Oropharynx	☐	☐	☐		
Tonsil	☐			☐ ☐	
Tongue	☐			50 gm ☐ ☐	
Lymph node, multiple sites	☐ ☐	☐ ☐	☐	50 gm ☐ ☐	
Trachea	☐	☐	☐	5 cm ☐	
Thyroid gland	▭			1 whole ▭ ▭	
Parathyroid gland	☐			☐	
Thymus	☐			50 gm ☐ ☐ ☐	
Lung	☐ ☐	☐ ☐	☐	50 cm ☐ ☐	
Heart	☐ ☐ ☐			50 gm ☐	
Aorta and vena cava	☐				
Diaphragm	☐			100 gm ☐	
Liver	☐ ☐			100 gm ☐ ☐ ☐	
Spleen	☐ ☐	☐		☐ ☐ ☐	

Tissue	Histopathology	Culture swab	Dry swab	Ancillary testing	Cytology
Spleen	☐ ☐	☐		☐ ☐ ☐	
Pancreas	☐			50 gm ☐	
Stomach	☐ ☐	☐		Ingesta ☐ ☐	
Small intestine	☐ ☐	☐ ☐		Ingesta ☐ ☐	
Colon	☐	☐ ☐ ☐		Ingesta ☐	
Adrenals	☐ ☐			50 gm ☐	
Kidney	☐ ☐			100 gm ☐ ☐ ☐	
Urine				50 ml ☐ ☐	
Urinary bladder	☐			☐	
Umbilicus	☐	☐			
Mammary gland	☐	☐	☐	100 gm ☐	Aspirate ☐
Genital slit	☐	☐ ☐	☐		
Vagina	☐	☐ ☐	☐		
Uterus	☐	☐ ☐	☐	50 cm ☐	
Ovary	☐	☐	☐	Intact corpora ☐	
Penis/testes	☐	☐ ☐	☐		
Accessory sex glands	☐				
Skeletal muscle	☐			100 gm ☐ ☐ ☐	
Rib/Bone marrow	☐			100 gm ☐	☐
Peripheral nerve	☐				

APPENDIX XXVII: Checklist - tissues to collect from a Code 5 killer whale carcass

Definition of Code 5: Severe decomposition; Skeletal remains with associated soft tissue remnants

Tissue	Histopathology	Culture swab	Dry swab	Ancillary testing	Cytology
Skin, multiple sites	☐			☐	
Blubber				☐	
Ears				Intact ☐	
Skeletal muscle				☐	
Teeth (1-2)				Intact ☐	
Rib/Bone marrow	☐			☐	
Skull/skeleton				☐	

Photo Identifier:

(Please cut this tool out and use it as a scale and identifier for photographs you take)

Animal ID#(s): **Sex:** **Age class:**

Stranding Location:

Necropsy date:

Prosector:

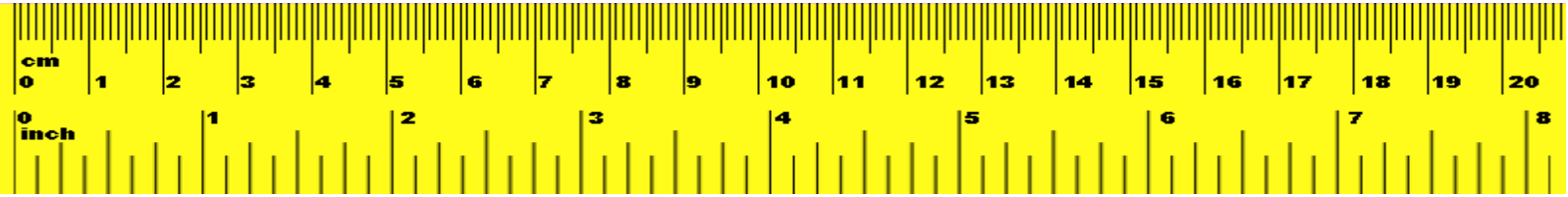

Appendix E: Selected MMHSRP Protocols

Sample Collection and Analysis

E-9: Handbook for recognizing, evaluating, and documenting human interaction in stranded cetaceans and pinnipeds (available at: http://swfsc.noaa.gov/publications/TM/SWFSC/NOAA-TM-NMFS-SWFSC-510.pdf)

NOAA Technical Memorandum NMFS

HANDBOOK FOR RECOGNIZING, EVALUATING, AND DOCUMENTING HUMAN INTERACTION IN STRANDED CETACEANS AND PINNIPEDS

Kathleen Touhey Moore
International Fund for Animal Welfare,
Marine Mammal Rescue & Research

Susan Gwynn Barco
Virginia Aquarium & Marine Science
Center, Stranding Response Program

MARCH 2013

NOAA-TM-NMFS-SWFSC-510

U.S. DEPARTMENT OF COMMERCE
National Oceanic and Atmospheric Administration
National Marine Fisheries Service
Southwest Fisheries Science Center

The National Oceanic and Atmospheric Administration (NOAA), organized in 1970, has evolved into an agency that establishes national policies and manages and conserves our oceanic, coastal, and atmospheric resources. An organizational element within NOAA, the Office of Fisheries, is responsible for fisheries policy and the direction of the National Marine Fisheries Service (NMFS).

In addition to its formal publications, the NMFS uses the NOAA Technical Memorandum series to issue informal scientific and technical publications when complete formal review and editorial processing are not appropriate or feasible. Documents within this series, however, reflect sound professional work and may be referenced in the formal scientific and technical literature.

"The findings and conclusions in this publication are those of the authors and do not necessarily represent the views of the National Marine Fisheries Service, NOAA."

NOAA Technical Memorandum NMFS
This TM series is used for documentation and timely communication of preliminary results, interim reports, or special purpose information. The TMs have not received complete formal review, editorial control, or detailed editing.

HANDBOOK FOR RECOGNIZING, EVALUATING, AND DOCUMENTING HUMAN INTERACTION IN STRANDED CETACEANS AND PINNIPEDS

Kathleen Touhey Moore
International Fund for Animal Welfare,
Marine Mammal Rescue & Research

Susan Gwynn Barco
Virginia Aquarium & Marine Science
Center, Stranding Response Program

MARCH 2013

NOAA-TM-NMFS-SWFSC-510

U.S. DEPARTMENT OF COMMERCE
Rebecca M. Blank, Acting Secretary
National Oceanic and Atmospheric Administration
Dr. Kathryn D. Sullivan, Acting Administrator
National Marine Fisheries Service
Eric Schwaab, Assistant Administrator for Fisheries

This document should be referenced as follows:

Moore, K.T. and S.G. Barco. 2013. Handbook for Recognizing, Evaluating, and Documenting Human Interaction in Stranded Cetaceans and Pinnipeds. U. S. Department of Commerce, NOAA Technical Memorandum, NOAA-TM-NMFS-SWFSC-510, 102p.

The authors are always interested in improving our understanding of human interaction and the effects of human activities on stranded marine mammals. If you have questions, or concerns about the content of this publication, please contact Moore or Barco:

Kathleen Touhey Moore
International Fund for Animal Welfare
Marine Mammal Rescue and Research
290 Summer Street
Yarmouth Port, MA 02675
kmoore@ifaw.org

Susan Gwynn Barco
Virginia Aquarium & Marine Science Center
Stranding Response Program
717 General Booth Boulevard
Virginia Beach, VA 23451
sgbarco@virginiaaquarium.com

Cover Images
*Left: Humpback whale (*Megaptera novaeangliae*) stranded in Virginia Beach, VA. Three lesions consistent with propeller strike from a large vessel are obvious on the left side of the animal.*

*Center: A juvenile harp seal (*Pagophilus groenlandica*) with a shotgun wound on Cape Cod, MA.*

*Right: Live bottlenose dolphin (*Tursiops truncatus*) wrapped in pot gear near Norfolk, VA. The animal was successfully disentangled and released on site.*

Table of Contents

Acknowledgments.....i
Preface.....i
1.0 Background.....1
2.0 The Basics.....4
3.0 Guidelines for Documenting Human Interaction...6
4.0 Recognizing Human Interactions.....11
4.1 Fishery Interactions.....12
4.2 Debris Entanglement.....36
4.3 Debris/Gear Ingestion.....38
4.4 Vessel Interactions.....41
4.4.1 *Sharp force trauma*.....44
4.4.2 *Blunt force trauma*.....51
4.5 Gunshot Wounds.....59
4.6 Projectiles and Other Penetrating Interactions.....61
4.7 Harvest/Mutilation.....61
4.8 Harassment/Human Interference.....64
4.9 Unknown or Undetermined Interactions.....66
5.0 Confounding Variables.....67
5.1 Natural and Unknown Marks.....67
5.2 Rapid Death.....71
5.3 Predation and Scavenger Damage.....72
5.4 Decomposition.....75
6.0 Necropsy and Sampling.....78
7.0 Outreach and Education..... 80
Literature Cited.....82
Appendix I HI Data Sheet and Instructions.....83

Acknowledgments

We would like to extend our gratitude to the many organizations and individuals who have contributed to the development of this protocol. The work presented here was funded by the NOAA John H. Prescott Grant Program (CCSN Award: NA04NMF4390044, VAQSP Award: NA03NMF4390483 and contracts: *NFFK0000-5-00554, NFFN5300-7-19457,* NFFKPR00-8-43285). The staff and volunteers of the Virginia Aquarium Stranding Response Team and the International Fund for Animal Welfare Marine Mammal Rescue and Research Team (formerly the Cape Cod Stranding Network), provided valuable data for this work. Additional case studies were provided by Dr. Frances Gulland (The Marine Mammal Center, Sausalito), Connie Merigo (New England Aquarium, Boston), and Kim Durham (Riverhead Foundation for Marine Research & Preservation, New York). For assistance with the watercraft interaction section, we thank Tom Pitchford (Florida Fish and Wildlife Conservation Commission) Sentiel (Butch) Rommel, and Alex Costidis (University of North Carolina, Wilmington). We would also like to thank Bill McLellan (University of North Carolina, Wilmington, VABLAB), Greg Early, Dave Rotstein, Janet Whaley, Brian Stacey (NOAA Office of Protected Resources), Brian Moore (National Marine Life Center), for editorial efforts and NOAA Fisheries OPR Northeast Region, Southeast Region and Headquarters for their guidance and support.

Preface

This project evolved from joint effort and John H. Prescott Marine Mammal Rescue Assistance Grant Program awards to the Cape Cod Stranding Network, Inc. (CCSN) and the Virginia Aquarium Stranding Response Program (VAQS) where the authors proposed to develop a human interaction training program for the Northeast Region Stranding Network in the United States. At the time of the awards, there was no finalized national human interaction data sheet and the project transformed to include development of a data sheet, data sheet instructions, and a training program. Upon completion of the regional work, the authors proposed to the national stranding coordinator, Dr. Janet Whaley, to provide the training to all stranding networks in the United States.

The information detailed in this handbook is designed to accompany the training program and to serve as a desk reference for stranding responders.

Note on contents

This manual will not address oil/chemical spills or acoustic interactions. Oil and chemical spills are handled under existing established protocols with standard operating procedures. Animals affected by a spill will be managed under spill response protocols implemented through the Incident Command System and overseen by the United States Coast Guard, NOAA Fisheries, and the U.S. Fish and Wildlife Service. Injuries caused by acoustic trauma are not fully understood at this time. Standard protocols are currently being developed and tested. If you suspect acoustic trauma based on circumstances surrounding the stranding, contact your regional stranding coordinator and describe the animal and circumstances. She or he will give you further instructions.

1.0 Background

Goals and objectives of this protocol

The goal of this protocol and the accompanying training material is to provide stranding network personnel with the tools needed to evaluate marine mammals for signs of human interaction (HI) and to collect HI data consistently in all regions of the United States. This goal will be achieved by accomplishing the following objectives:

- Define the terms associated with human interaction evaluations
- Explain the importance of being conservative with observations and reporting
- Provide an understanding of how HI data may/should be used
- Introduce a standardized examination protocol and accompanying data sheet
- Provide guidelines for recognizing and documenting evidence of human interaction found on stranded marine mammals

The protocol presented within this document will yield two important pieces of information. The first is an **objective evaluation** of an animal or carcass that determines whether any signs of human interaction are present on the animal (regardless of whether they may have contributed to the stranding or death of the animal, occurred before or after death, are healed or recent). [Note: for the purposes of discussion, the terms “signs of human interaction” and “findings of human interaction” will be used interchangeably throughout this document and both refer to the current human interaction field on the NOAA Level A data sheet.] The second is a **subjective finding** in which examiners use all available information and their experience to evaluate the likelihood that any observed evidence of HI contributed to the stranding event.

Why evaluate stranded marine mammals for signs of human interaction?

When human interaction data are gathered objectively and consistently, they can provide a solid scientific foundation for conservation and management measures. Documenting the types of interactions that take place and identifying the spatial and temporal patterns associated with the interactions can highlight resource use conflicts. With a better understanding of interactions, appropriate measures can be taken to resolve conflicts. Often, stranding data are the best source of information regarding the occurrence of different types of human interaction.

Furthermore, in the United States, the collection of human interaction data is mandated under the Marine Mammal Protection Act. The National Oceanic and Atmospheric Administration (NOAA) Fisheries Service requires that HI data be submitted with other basic information (such as species, stranding date and location, length, *etc*.) on each stranded animal.

Putting the data to use

Human interaction data are frequently and easily misinterpreted. In the United States, Level A data, including human interaction findings, are collected from each stranded marine mammal. The Level A data sheet asks for: “Findings of human interaction” with multiple choice answers of YES, NO, or CBD (**C**ould not **B**e **D**etermined), followed by related questions to gather more detailed information. However, different organizations and individuals often interpret this primary question differently. The federal instructions for the data sheet state that the data sheet field is designed to determine **only** whether or not there are signs of interaction present on the animal. ***This does not represent the cause of stranding or the cause of death of the stranded animal.***

By standardizing the way we examine animals, collect data, and document interactions, we ensure that we are not only answering the same question, but using the same basis to draw our conclusions. This protocol defines the terms we use to describe and categorize interactions. All organizations implementing this protocol and utilizing the data sheet will collect comparable data, affording the opportunity to analyze data on a broader scale, across the distribution of the species within US waters.

The final subjective conclusion on the data sheet requires the examiner to combine the initial objective finding from the data sheet with the event history/circumstances, sample analyses, and their own experience. This section allows the examiner the opportunity to evaluate the likelihood that an observed interaction contributed to the stranding of the animal.

However, the protocol is NOT designed to determine whether an observed interaction caused the death of an animal. Making this conclusion requires a complete necropsy which includes sampling for evaluation by a veterinary pathologist, sampling for ancillary diagnostics to rule out

infectious disease, and a full history of the circumstances of the stranding event.
When collected carefully and consistently, these data can be used to describe the types of interaction taking place (*e.g.* monofilament vs. multifilament net entanglement, small or large vessel interaction, ingestion of plastic debris, harassment, *etc.*).

Limitations of Human Interaction data

These data can provide a sound scientific basis for policy and management decisions, but one should not use human interaction data to estimate mortality or changes in mortality rate due to human interaction (*e.g.* it is illogical and inaccurate to utilize HI data to estimate mortality in a population. Many animals die of natural causes as well as human interaction. Furthermore, it is certain that many marine mammals perish at sea and their bodies are not discovered for examination. Thus, neither HI data, nor stranding data are representative of the total mortality rate).

Furthermore, there are categories of human interaction that are difficult, if not impossible, to evaluate at this time such as strandings that result from persistent harassment, those that may elicit detrimental behaviors such as sub-lethal exposure to sound, as well as long-term effects of man-made products that may result in lowered immunity, disease or reduced reproductive rate. Human activities have most likely resulted in exposure to novel pathogens such as *Toxoplasma gondii* for marine mammals. Fishing activities have changed abundance and distribution of many natural marine mammal prey species. There are new activities such as renewable energy and aquaculture operations that are just beginning to be exploited in the US, for which we do not yet know the potential impacts on marine mammals.

Currently, we cannot point to a mark or a diagnostic test that can tell us whether a stranded whale has been exposed to active sonar or to sound generated by a wind farm. We cannot guarantee that a seal pup was never exposed to humans or their activities. Finally, we must acknowledge that we do not understand the cumulative effects of multiple human interaction stressors on marine mammals.

We must acknowledge that human activities have affected the lives of every marine mammal, but for our purposes, we are trying to document those human activities that are consistently observable and can be documented by stranding responders.

2.0 The Basics

Definitions

There are several key terms used in this protocol. It is important that all examiners define these terms the same way in order to ensure that our data are comparable.

YES: you have examined the anatomical area/animal and you found clear signs of human interaction.

NO: you have examined the anatomical area/animal and you did NOT find signs of human interaction.

CBD (Could not Be Determined): you are unsure whether there are any signs of human interaction (this may be due to any of several causes including, but not limited to: inexperience of examiner, decomposition, missing body parts, logistical constraints, *etc.*).

NE (Not Examined): you did not examine the area.

NA (Not Applicable): this question is not applicable.

The importance of being conservative

In addition to standardizing our protocols and maintaining objectivity when examining animals, it is essential to be conservative in our evaluations. Since these data may be used to generate policies and management strategies, they must stand up to scientific, and possibly legal, scrutiny. By making very conservative evaluations, we ensure that our data are robust and strong.

Again, for the sake of consistency, we must establish what it means to be conservative. **The most conservative diagnosis is always CBD (Could not Be Determined)**. This is a fundamental premise of this protocol.

It is best understood by thinking of it this way: every animal or carcass is a CBD until proven otherwise. If evidence of human interaction was found, then the objective finding is YES, there were findings of HI. If the animal was thoroughly examined and no evidence of HI was found, then the answer was NO. However, if you were unsure of a mark on the animal for any reason, or if any factors compromised your ability to evaluate the carcass properly or thoroughly, then the finding must remain CBD.

The factors that can affect your ability to evaluate a stranded animal for signs of HI include, but are not limited to:

- Decomposition
- Scavenger damage
- Predation
- Inexperience in conducting these exams
- Logistics (large animals that one cannot manipulate to examine both sides, tidal constraints, weather)

(See Chapter 5.0 Confounding Variables)

It is important to begin with a finding of CBD, then look for evidence to prove otherwise (YES or NO). The reality is that it is much easier to say YES than it is to say NO. Therefore, we must begin with the conservative diagnosis of CBD and search for evidence to indicate a diagnosis of YES (there are findings of HI) or NO (there are no findings of HI). In the majority of cases, the finding will remain CBD. Take the following scenarios as an example:

Scenario 1: A decomposed seal carcass washes ashore. Some fur is missing from the right front flipper and both rear flippers are badly degraded with some skin and muscle missing. There is a circumferential constriction wound around its neck deep into the muscle layer. The edges of the wound appear clean and smooth. Although the source of the wound is not readily apparent (*e.g*. there is no gear on the animal), the wound is consistent with a ligature mark. One can definitively score this as a YES for signs of HI.

Scenario 2: A decomposed seal carcass washes ashore. Some fur is missing from the right front flipper and both rear flippers are badly degraded (This is the same animal as in Scenario 1, without the ligature mark.). One cannot definitively score this animal as a NO because several of the areas could not be evaluated due to the physical degradation. Thus, the only reasonable finding is CBD.

So, it is easier to have a YES finding in this case, but impossible to have a NO finding. It only takes one piece of evidence of HI to have a finding of YES for even a decomposed carcass, but it takes a full, uninhibited examination of all parts of the animal to generate a conclusion that there was no finding of HI. When you cannot definitively say YES or NO, you must conclude that the presence or absence of HI could not be determined (CBD). Thus, CBD is always the most conservative answer.

Strategy for evaluation

Since CBD is a conservative diagnosis, assume the answer is CBD and try to prove otherwise. If you have conducted a thorough examination and find no signs of HI, the diagnosis is **NO.** If you have conducted a thorough examination and find clear signs of HI, the diagnosis is **YES.** If all examiners begin with this premise, it will consistently ensure that the evaluations are conservative.

3.0 Guidelines for Documenting Human Interaction

Introduction to the protocol

A reproducible copy of the data sheet can be found in Appendix I. The first step in understanding the data sheet and protocol is to read the instructions that accompany the data sheet. These instructions describe the protocol and define the terminology in the data sheet and each data field line by line. Although this may seem obvious, it is important to answer the questions that are being asked.

The data sheet (below) drives your examination by leading you through the protocol. Be systematic in your examination, conducting it the same way each time.

1. To begin, observe the whole animal. Provide an overall, general external description of what you see.
2. Next, examine each anatomical area thoroughly, recording your detailed observations.
3. If the animal has died or has been euthanized, conduct a thorough necropsy. Sample all evidence of HI, as well standard samples for histopathology, toxicology, genetics, *etc*.

Be sure to document your observations (both external and internal) through images (drawings, photos, videos) and detailed notes. Once you have completed your gross examination, review your observations to determine whether there are findings of human interaction (objective evaluation). Now, review the stranding history and all other available information to make an initial HI evaluation (subjective evaluation), regarding how likely it is that any observed HI contributed to the stranding event, providing detailed information to justify your findings.

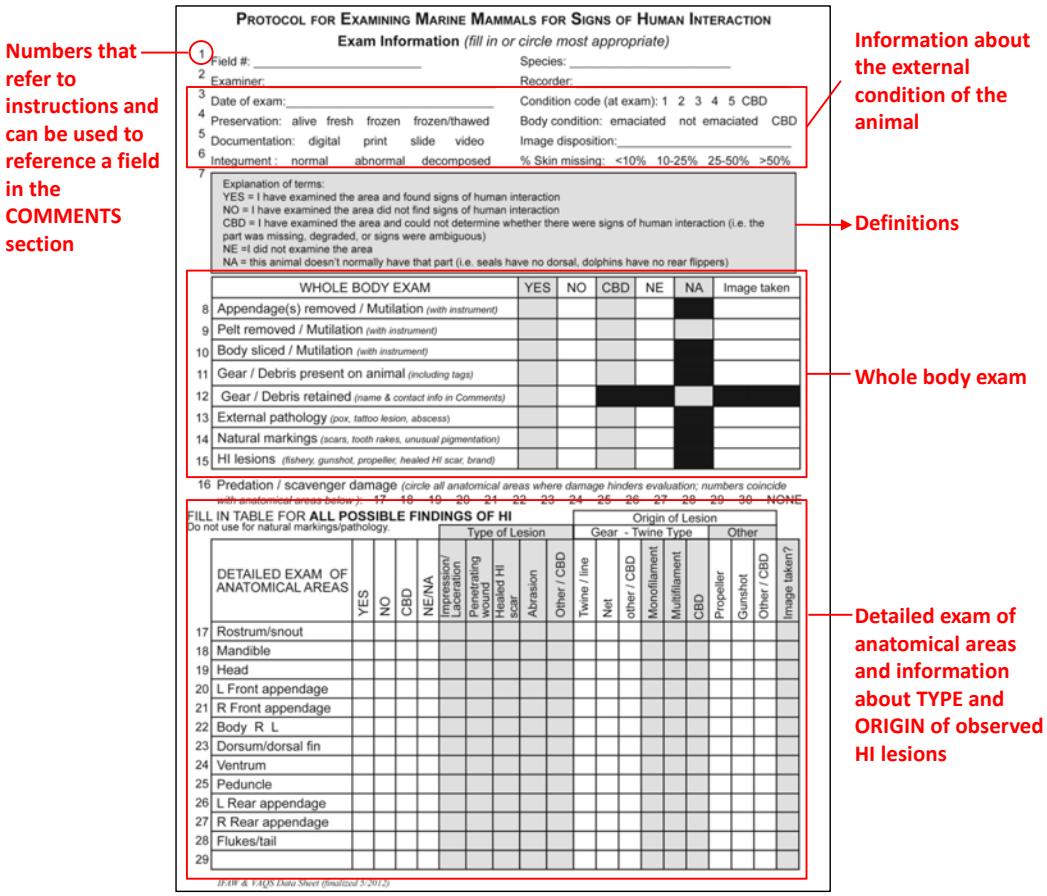

PROTOCOL FOR EXAMINING MARINE MAMMALS FOR SIGNS OF HUMAN INTERACTION

Exam Information *(fill in or circle most appropriate)*

1 Field #: _____ Species: _____
2 Examiner: Recorder:
3 Date of exam:_____ Condition code (at exam): 1 2 3 4 5 CBD
4 Preservation: alive fresh frozen frozen/thawed Body condition: emaciated not emaciated CBD
5 Documentation: digital print slide video Image disposition:_____
6 Integument : normal abnormal decomposed % Skin missing: <10% 10-25% 25-50% >50%

7 Explanation of terms:
YES = I have examined the area and found signs of human interaction
NO = I have examined the area did not find signs of human interaction
CBD = I have examined the area and could not determine whether there were signs of human interaction (i.e. the part was missing, degraded, or signs were ambiguous)
NE =I did not examine the area
NA = this animal doesn't normally have that part (i.e. seals have no dorsal, dolphins have no rear flippers)

	WHOLE BODY EXAM	YES	NO	CBD	NE	NA	Image taken
8	Appendage(s) removed / Mutilation *(with instrument)*						
9	Pelt removed / Mutilation *(with instrument)*						
10	Body sliced / Mutilation *(with instrument)*						
11	Gear / Debris present on animal *(including tags)*						
12	Gear / Debris retained *(name & contact info in Comments)*						
13	External pathology *(pox, tattoo lesion, abscess)*						
14	Natural markings *(scars, tooth rakes, unusual pigmentation)*						
15	HI lesions *(fishery, gunshot, propeller, healed HI scar, brand)*						

16 Predation / scavenger damage *(circle all anatomical areas where damage hinders evaluation; numbers coincide with anatomical areas below.)* 17 18 19 20 21 22 23 24 25 26 27 28 29 30 NONE

FILL IN TABLE FOR **ALL POSSIBLE FINDINGS OF HI**
Do not use for natural markings/pathology.

	DETAILED EXAM OF ANATOMICAL AREAS	YES	NO	CBD	NE/NA	Type of Lesion: Impression/ Laceration	Penetrating Wound	Healed HI scar	Abrasion	Other / CBD	Origin of Lesion: Gear - Twine Type: Twine / line	Net	other / CBD	Monofilament	Multifilament	CBD	Other: Propeller	Gunshot	Other / CBD	Image taken?
17	Rostrum/snout																			
18	Mandible																			
19	Head																			
20	L Front appendage																			
21	R Front appendage																			
22	Body R L																			
23	Dorsum/dorsal fin																			
24	Ventrum																			
25	Peduncle																			
26	L Rear appendage																			
27	R Rear appendage																			
28	Flukes/tail																			
29																				

IFAW & VAQS Data Sheet (finalized 5/2012)

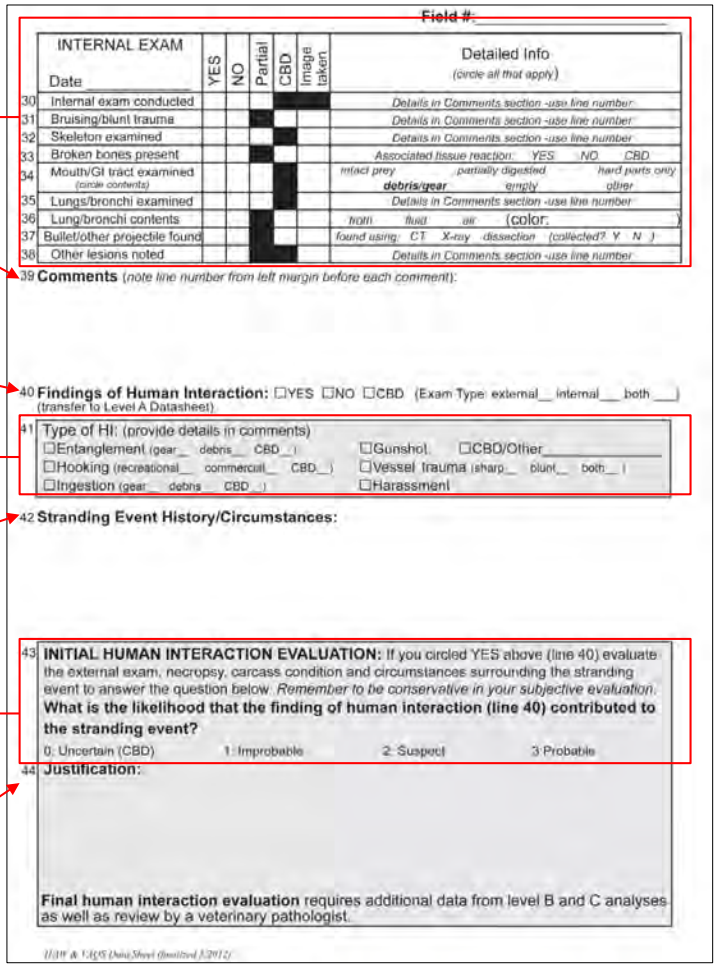

Field #: _____

INTERNAL EXAM Date _____	YES	NO	Partial	CBD	Image taken	Detailed Info (circle all that apply)
30 Internal exam conducted						Details in Comments section -use line number:
31 Bruising/blunt trauma						Details in Comments section -use line number:
32 Skeleton examined						Details in Comments section -use line number:
33 Broken bones present						Associated tissue reaction: YES NO CBD
34 Mouth/GI tract examined (circle contents)						intact prey partially digested hard parts only debris/gear empty other
35 Lungs/bronchi examined						Details in Comments section -use line number:
36 Lung/bronchi contents						froth fluid air (color:)
37 Bullet/other projectile found						found using: CT X-ray dissection (collected? Y N)
38 Other lesions noted						Details in Comments section -use line number:

39 **Comments** (note line number from left margin before each comment):

40 **Findings of Human Interaction:** ☐YES ☐NO ☐CBD (Exam Type: external__ internal__ both __)
(transfer to Level A Datasheet)

41 Type of HI: (provide details in comments)
☐Entanglement (gear__ debris__ CBD__) ☐Gunshot ☐CBD/Other_____
☐Hooking (recreational__ commercial__ CBD__) ☐Vessel trauma (sharp__ blunt__ both__)
☐Ingestion (gear__ debris__ CBD__) ☐Harassment

42 **Stranding Event History/Circumstances:**

43 **INITIAL HUMAN INTERACTION EVALUATION:** If you circled YES above (line 40) evaluate the external exam, necropsy, carcass condition and circumstances surrounding the stranding event to answer the question below. *Remember to be conservative in your subjective evaluation.* **What is the likelihood that the finding of human interaction (line 40) contributed to the stranding event?**
0: Uncertain (CBD) 1: Improbable 2: Suspect 3: Probable

44 **Justification:**

Final human interaction evaluation requires additional data from level B and C analyses as well as review by a veterinary pathologist.

Using the data sheet

The data sheet is designed to lead the examiner through the protocol step by step. Begin by reading and becoming familiar with the instructions that accompany the data sheet. Following the sheet each time an evaluation is done will help the examiner establish a routine in conducting the examination. Some basic guidelines will help develop consistent, systematic data collection:

- Be sure to fill in all spaces; do not leave any items blank
- Be objective in your examination
- Have the recorder repeat data back to the observer as it is written to reduce errors
- Provide as much detail as possible; use the comments section
- Event history is important – note any report details, witness accounts, fishing or other activities in the area, *etc*.

After finishing your observations, the examiner **must** evaluate the results:

Findings of Human Interaction and ***Exam Type***– based on **objective** observations, were there any findings of HI? (YES, NO, CBD). This is an objective analysis. It does not take into account the animal's physical condition, the timing of the human interaction with respect to the stranding or the circumstances surrounding the stranding. This simply indicates the presence or absence of signs of HI. Once you have determined the Findings

of HI, select the appropriate Type of Exam you conducted. If you ONLY conducted an external exam, check External. If you ONLY conducted an internal exam, check Internal (*e.g*. if the carcass lacked skin or pelt due to decomposition but you found plastic in the GI tract upon internal exam). If you conducted both an external and an internal exam check Both. The answers transfer to the NOAA Fisheries Level A data sheet.

Initial Human Interaction Evaluation and ***Justification*** – a **subjective,** but conservative, interpretation of the event**. Fill out this section if you checked YES for Findings of HI.** Using all of the information available, indicate the likelihood that the observed human interaction contributed to the stranding event. This is represented on a scale of 0-3 (0=Uncertain or CBD, 1=Improbable, 2= Suspect, 3=Probable). This scale functions as a confidence level. This subjective finding should take into account the experience level of the examiner, physical findings, stranding history and circumstances. **Most importantly, it takes into account the evaluator's level of experience. If you have not conducted many evaluations or are not familiar with the region, you may be unable to make an accurate evaluation and should circle CBD.** This section does not take into account results of level B and C analyses or review by veterinary pathologist which is why it is considered an INITIAL evaluation. Results of laboratory analyses, and the findings of veterinarians, pathologists and other experts should also be incorporated into the report when available and may either support or amend the original Initial Human Interaction Evaluation.

0. ***Uncertain (CBD)*** - You cannot provide an evaluation of the likelihood that human interaction contributed to the stranding (*e.g*. a Code 4 carcass is found with propeller marks; it is too decomposed to determine grossly whether the interaction occurred before or after death).
1. ***Improbable*** - It is unlikely that the observed human interaction contributed to the stranding and there are other gross findings that suggest an alternative cause for the stranding (*e.g*. there are healed entanglement scars on the flukes of a known humpback whale that died with a full-term fetus; it is unlikely that the past entanglement contributed to the stranding).
2. ***Suspect*** - It is possible that human interaction contributed to the stranding, but the findings of HI are weak and/or there are other findings that may have caused the stranding (*e.g*. there is a small amount of plastic found in an animal's stomach, but you are unsure of its effect and the animal is very thin with a high parasite level. Did the plastic ingestion cause the animal's decline or was a declining animal eating anything it could get?).
3. ***Probable*** - It is very likely that human interaction contributed to the stranding (*e.g*. a robust animal with a full stomach, froth in the lungs and marks that are consistent with entanglement and underwater entrapment).

For comprehensive and detailed instructions for completing the Human Interaction Evaluation data sheet, please see instructions in Appendix I.

How to describe and capture what you see

When describing the marks you see on an animal (natural or anthropogenic), be as detailed as possible. Note the location on the body relative to landmarks (*i.e.* distance from blowhole or anterior insertion of the dorsal fin), the size (length, width, and depth), shape, color, texture, smell, *etc*. If there appears to be a series of wounds or lesions, note the distance between them from either the leading or trailing edges of each lesion. Examiners often feel the need to use highly technical terms to describe what they see. This is not necessary; instead, use terms you are most comfortable with based on your level of experience. Plain, simple, accurate descriptions of what you see are important. The goal is to paint a picture that ensures all readers will understand what you saw. It is often useful to draw analogies to common objects in reference to such things as color and texture. For example, one can clearly picture the following observations noted on a common dolphin:

- A circular lesion on the right side of the peduncle at the lateral midline, 15cm cranial of the base of the flukes. The lesion is 3.4cm in diameter, characterized by an outer, dark gray line encircling the lesion and a pale gray-white scar-like inner ring. The center of the lesion appears ulcerated, open and deep red/ maroon similar to raspberry jam.
- 500-700ml of port wine colored fluid in peritoneal cavity.

Images and video

In addition to describing what you see, it is very important to document your observations through images and video. Digital, 35mm, and slide images are excellent means of capturing your observations. If possible, video taping or digitally recording images can also provide an outstanding record of your observations. If you don't have the means to photograph or video the animal, sketch what you see. These images are important in the human interaction evaluation. Documenting the evidence of HI, or the absence of that evidence, serves to support what you enter in the *Findings of HI* and *Initial HI Evaluation* fields on the data sheet. In addition, proper documentation allows those analyzing or utilizing HI data in the future to better understand and evaluate your conclusions. Images and video help ensure that data are not misinterpreted or misconstrued. When documenting your examination, remember these tips:

- Photograph/video everything – even if you don't see marks
- Always use label and scale in all images – label should include Field #, date of stranding, species, organization; close up shots should include the location of the lesion and/or name of the body part
- Be aware of shadows, glare and fingers – eliminate anything that obscures images and take images from different angles
- Draw and describe all marks - by concentrating on drawing an image, you make better observations of its location and size

Collecting physical evidence

In some instances, human interaction cases may be considered legal cases in which law enforcement officers will pursue the interaction as a criminal or civil offense. For this reason, it is important, whenever possible, to treat HI cases as possible legal cases. Evidence should be collected and handled in a systematic manner. Evidence can include any gear, debris, or other items removed from the animal, photos, and tissue samples, *etc*. Consult with your local law enforcement officials to determine their requirements for evidence handling. In the United States, NOAA Fisheries Office of Law Enforcement handles infractions of the Marine Mammal Protection Act. They have specific evidence handling procedures and Chain of Custody

protocols and forms (See Appendix C of Geraci and Lounsbury 2005). These measures ensure any evidence collected in the course of your investigation is admissible in court should a legal case ensue. Basic guidelines for evidence handling include:

- Be sure to label all evidence and samples appropriately
- Secure all evidence/samples, limiting access to a small number of known individuals
- When transferring evidence/samples to researchers or labs, be sure to maintain the Chain of Custody by utilizing a Chain of Custody form and instructions.

Summary of tips for conducting an evaluation

- **Develop a routine** - follow it for every exam
- **Document everything**
- Photograph (include label & scale in every image)
- Measure marks/lesions (all dimensions)
- Sample (especially for histopathology)
- Collect other evidence and maintain chain of custody
- **Interact with others** - share unusual cases and lesions with other stranding personnel, fishery managers, and veterinarians
- **Understand and acknowledge confounding variables** - decomposition, scavenger damage, sunburn, and logistics are all things that make HI evaluation difficult. Never be afraid to score something as CBD

4.0 Recognizing Human Interactions

In this section of the handbook, several common types of human interaction are presented in detail. Important definitions and descriptions are provided in conjunction with a summary of evidence and marks commonly observed. Examples are provided to illustrate these points, and several full case studies are provided to illustrate the use of this protocol in recognizing, identifying, and documenting evidence of human interaction in stranded marine mammals.

Definitions

Trauma: an injury (wound) to living tissue caused by an extrinsic agent

Blunt force trauma: Injury produced by a blunt object striking the body or impact of the body against a blunt object or surface (DiMaio and Dana 2007).

Sharp force trauma: an injury caused by a sharp or pointed object with sufficient force to create penetrating (incision/chop) wounds.

Impression: an impression occurs when a line, net, or other form of gear or debris leaves an indentation, but does not lacerate or abrade the skin/pelt. Impressions left by net or line usually wrap around the leading and/or trailing edges of a fin, flipper or fluke of cetaceans and around the necks of pinnipeds. Impressions on the leading edge of an appendage may line up with a similar mark on the trailing edge.

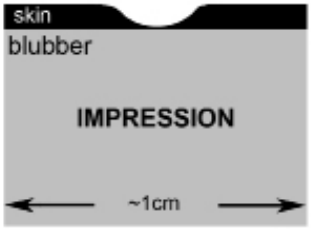

Laceration: a laceration is a tearing of the skin or pelt. Lacerations are caused by blunt trauma that results in stretching, tearing, crushing, shearing, or avulsion of tissue (DiMaio and Dana, 2007). We often think of lacerations as “cuts” into the skin; however, there is a distinction between a laceration and a cut or incision, which is a penetrating wound. On cross section, lacerations have rounded edges where a blunt object (*e.g.* net or line) has been pushed into the tissue until the surface has been broken or torn. Net and line usually leave linear lacerations.

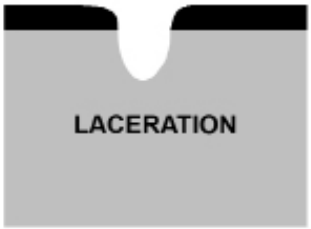

Incision: a penetrating wound that has clean edges that show no rounding or tearing. Wounds from monofilament twine (alone or as a net) may appear incised, but , in fact, are lacerations. See penetrating wounds below.

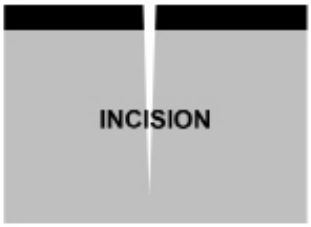

Abrasion: an abrasion occurs when the skin is scraped or rubbed away by a rough surface (DiMaio and Dana, 2007), without an obvious laceration (*e.g.* when the rough surface of gear or debris slides against the skin). In some cases, compression of the skin, such as when gear encircles or constricts an appendage, can also cause abrasions. This type of wound commonly occurs with heavy line or twine entanglement, or when loose or trailing ends of gear/debris rub (abrade) parts of the body.

Penetrating wounds: a penetrating wound occurs when a foreign object punctures or deeply penetrates the body and can be characterized as one of three types: stab wound, incised wound

or chop wound (DiMaio and Dana, 2007). Penetrating wounds are similar to lacerations in that they break the surface of the skin; however, lacerations are more superficial.

Stab: stab wounds are generally characterized by a small external wound and a wound tract that extends deep into the tissue and often into the body cavity. In stab wounds the depth of the wound is greater than the length of the wound that is apparent on the skin (DiMaio and Dana, 2007). Stab wounds are generally caused by weapons such as gaffs, or knives, or projectiles such as arrows, or spears.

Incised: incised wounds are clean cuts into the skin which are longer on the skin surface than they are deep (the opposite of stab wounds) (DiMaio and Dana, 2007). These wounds are caused by sharp-edged objects such as knives or some propellers.

Chop: chop wounds are incised wounds that penetrate deep to the bone, leaving a groove or cut in the bone. Tangential chops may leave a disk-shaped wound where bone and/or skin has been removed. Chop wounds may appear similar to lacerations (causing more tearing of tissue) when dull-edged implements are used (DiMaio and Dana, 2007)

Gunshot wounds: gunshot wounds are a type of ballistic trauma produced by bullets or other missiles projected from a firearm. These wounds may be glancing or penetrating in nature. Gunshot wounds will have different characteristics based on the type of firearm, type of ammunition (bullet, shotgun pellet, *etc.*), angle of the shot, and the distance between the muzzle of the firearm and the body.

Healed HI scar: a healed human interaction scar is similar to a natural scar in pigmentation, but exhibits similar characteristics to the other types of lesions described here (*e.g.* linear scars on leading edges of appendages consistent with entanglement). It is important to document healed HI scars as well as recent, unhealed wounds. [NOTE: Evidence of HI, even if healed and not likely associated with the stranding event, should still be scored YES for HI.]

Antemortem: an antemortem injury or lesion was present/existed preceding death though not immediately (see *premortem* below, Merriam-Webster, 2012).

Premortem: a premortem injury or lesion is one that occurs immediately before death (Merriam-Webster, 2012).

Postmortem: a postmortem injury or lesion occurred after death (Merriam-Webster, 2012).

The forensic definitions above will be utilized throughout the remainder of this handbook to describe the different types of wounds or signs of human interaction that may be observed from a variety of causes.

4.1 Fishery Interaction

Fishery interaction is probably the most subtle and varied form of human interaction that occurs. It is easier to recognize in cetaceans than in any other marine mammal group because marks are more easily made and remain evident for a longer time in soft, smooth cetacean skin.
In other marine mammals (pinnipeds, sirenians), it is more difficult to determine if a fishery interaction has occurred without gear present on or in the animal. Fine, subtle marks are often not evident on fur or, tough, thick hide.

Definitions

To fully understand the complexities of fishery interaction, there are several terms with which the examiner should be familiar.

Gear is any type of commercial or recreational fishing equipment (nets, buoys, line, hooks, lures, pots, or traps, *etc.*).

Line (right) is made up of many individual strands or filaments of a material (*e.g.* hemp, cotton, nylon, and polypropylene). The filaments are twisted into strands that are then twisted or braided into rope. Line is larger in diameter and heavier than twine (see below). Line can leave a large impression, but more often leaves an abrasion or 'rub' mark. It is used for moorings, towing, forms the float and lead line of nets, and attaches buoys and anchors. Some gear is comprised primarily of line, such as pot and trap fisheries. Line can be sinking (*e.g.* nylon), floating (*e.g.* polypropylene), or neutrally buoyant in seawater.

Twine is small diameter line that can be multifilament or monofilament. Twine is constructed of various materials and is combined in different ways. Nets are often comprised of one or more types of twine. This differentiation between 'twine' and 'line' is used by the commercial fishing industry and will likely be used by commercial fishers.

Monofilament twine (right) is a single, smooth strand of nylon that leaves a straight, narrow furrow, impression, or laceration. Heavy (larger diameter > 1mm) monofilament twine tends to leave impressions, while lighter (smaller diameter < 1mm) monofilament twine tends to penetrate into the flesh and leave lacerations.

Multifilament twine (left) is made up of multiple strands of material that are twisted or braided together. Multifilament twine can leave distinctive impressions (a series of parallel, angled lines or ovals). Multifilament twine can also cause lacerations or abrasions depending on the diameter and nature of the entanglement.

Microfilament twine (right) is a fairly new product. It is very narrow in diameter, but extraordinarily strong. It has the fine diameter of a monofilament twine, but is actually



multifilament, which gives it an abrasive texture. This very fine twine can cause extensive tissue damage. The narrow diameter, strength, and texture of this twine cause it to act like a saw or cutting blade. Microfilament twine most often causes lacerations and can rapidly, partially or completely, amputate an appendage.

Nets (below) can be made of either monofilament or multifilament twine and have various characteristics based on: twine diameter, square mesh size (measuring knot to knot), and stretch mesh size (taking one square of mesh, measuring diagonally between opposite knots of a mesh pulled taut).

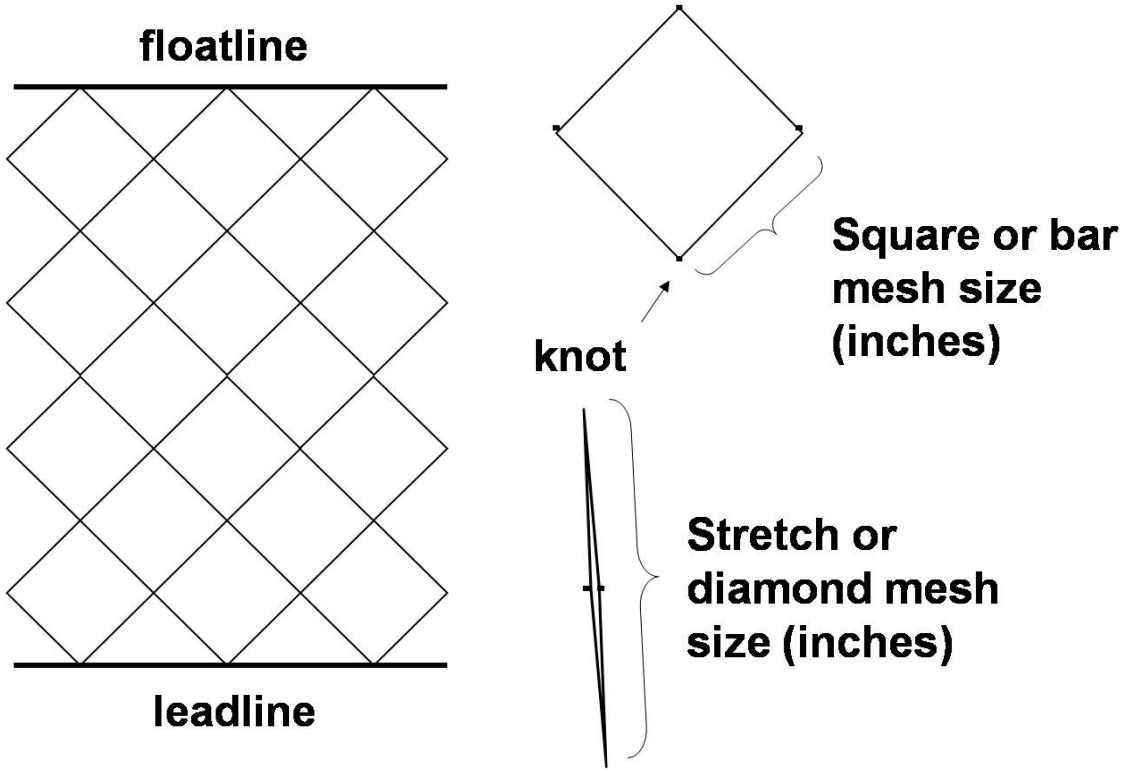

Gill net (right) is usually made up of 1 or more panels of monofilament net with a buoyant line at the top (float line) and a weighted line at the bottom (lead line). The mesh and twine sizes vary according to the target species and environmental conditions. Gillnets can be set at/in the upper, mid, or bottom of the water column. Many gillnets are anchored on one or both ends with cement, chain, or a standard anchor. Non-anchored gillnets are called drift nets.

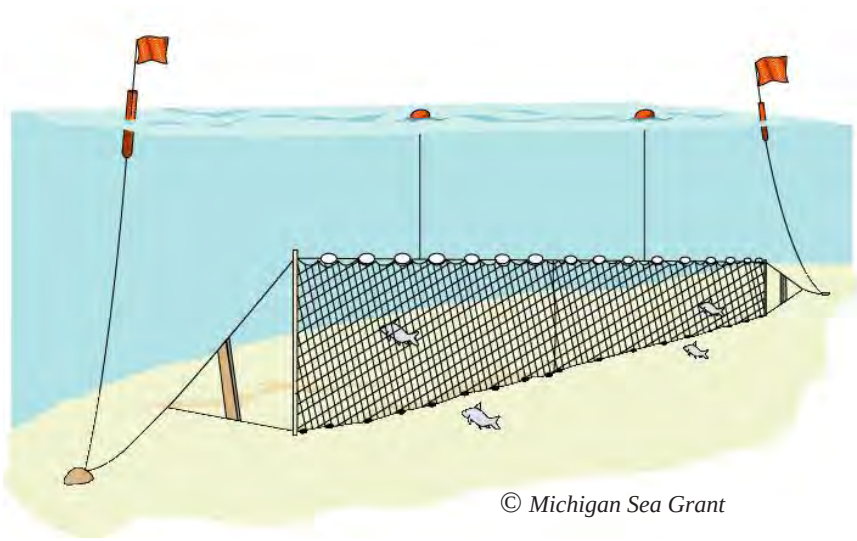

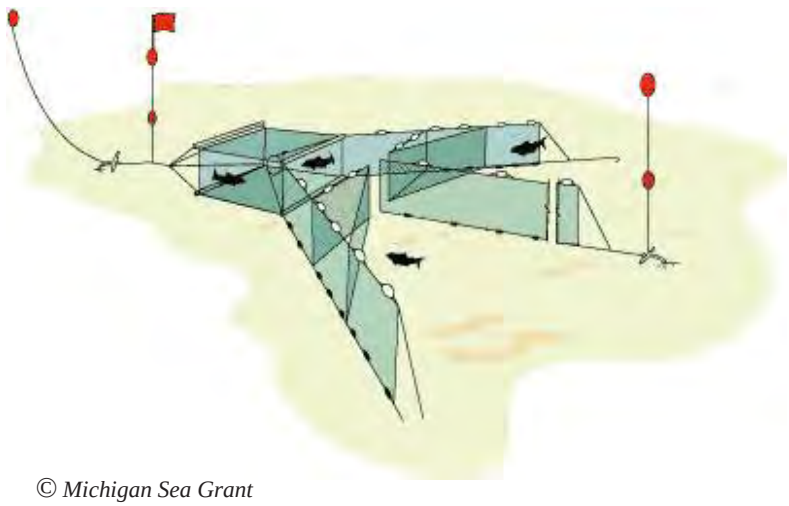

© Michigan Sea Grant

There is usually a buoy system on both ends. Animals can become entangled in the net, the anchoring system, the vertical (buoy) line, or the surface (buoy) system.

Fixed nets (left) are often called fish traps. They include pound nets, weirs, and several other types. Fixed nets are staked, moored, or anchored and are not moved. They usually have a straight leader line that directs fish toward the trap (or heart) part of the net. These nets are usually made of heavy twisted twine and the mesh sizes vary in different parts of the net and in different geographic regions. Animals can become entangled in the leader line, the anchoring system, or in the fish trap.

Hooks can be used in both recreational or commercial gear and includes both a single hook on a rod and reel ('rod and reel' fishery-standard recreational gear) and multiple hooks on line/twine. Longline (below) is commercial hook gear with numerous baited hooks on gangions or short pieces of line or twine that are attached to a central main line at regular intervals. The central line may be comprised of line or, less often, heavy monofilament, and the gangions are usually heavy monofilament twine. Some longlines are marked with light sticks which attract the target fish. Animals can become entangled in the central line, buoy lines, in the gangion and hook system, become hooked, or ingest a hook or light stick.

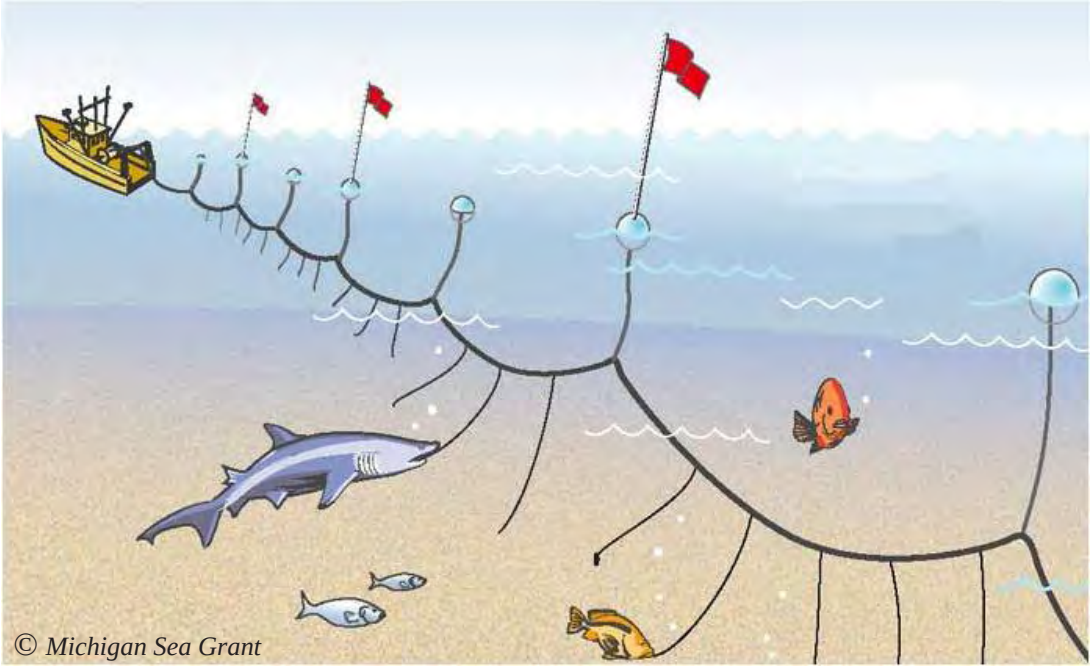

© Michigan Sea Grant

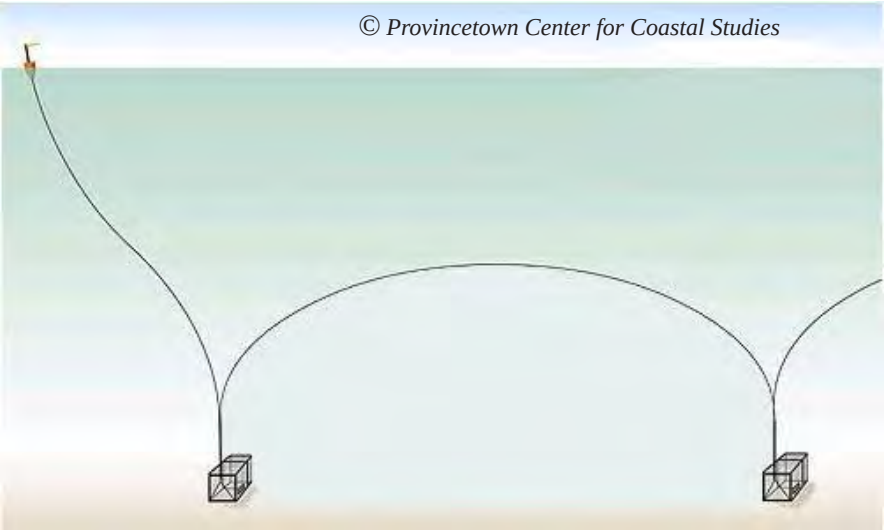

Pot (trawl) (right) is used for crabs, lobster, whelk, and other invertebrates as well as fish. When pots are attached together, the gear is called a trawl. The lines between the pots are called ground lines. These lines may be sinking lines that sit on the bottom between pots (mandated in Massachusetts) or buoyant lines that float within the water column. The trawl may have one or more buoy lines. Animals can become entangled in the ground line, vertical (buoy) line, or in the pot itself (usually going after bait).

Stranding responders should familiarize themselves with the types of fishing gear present in their area. Local fishers, fishery managers, enforcement officers, and commercial fishing supply houses are good sources of information. Establishing positive working relationships with local fishers and managers will not only aid in understanding gear types, but also prove useful in many aspects of stranding response. Fishers are often the best sources of information regarding activities in your area, such as changing conditions and new fishing gear. [FAO has produced a Fishery Manager's Guidebook (fisheries technical paper 424) which is available online at www.FAO.ORG. Basic gear types are described and illustrated in the document]

Examples of fishery interaction

Entanglement in fishing gear can leave many different types of marks on marine mammals. These marks primarily occur on the edges of the head, appendages and peduncle and can generally be categorized as impressions, lacerations, or abrasions. Evidence of entanglement varies by the type of gear, the species involved, and the location and nature of the entanglement. The following examples briefly highlight the most common entanglement injuries observed.

I**mpressions** are most often found on the head and leading and trailing edges of appendages. It is uncommon that an impression occurs only on a lateral surface (such as the thorax, side of the head, or on the flat surfaces of the flukes or flippers) without a corresponding mark on a leading and/or trailing edge. The diameter of the twine (twine size), the amount of struggle by the animal, the drag on the animal, and the shape of the affected body part all dictate whether gear produces an impression or a laceration. Impressions quickly disappear as an animal becomes desiccated or sunburned. When taking pictures of impressions, be careful of glare produced by lights and camera flash. Take images from several angles. Often an oblique angle without camera flash produces the best results.

*Bottlenose dolphin (*Tursiops truncatus*) with a MONOFILAMENT IMPRESSION on the rostrum creating a straight furrow (▬▬▬▬▬) in the skin (left; © Virginia Aquarium).*

*Harbor porpoise (*Phocoena phocoena*) with a MONOFILAMENT IMPRESSION across the rostrum (right; © Virginia Aquarium). Porpoises are notorious for NOT struggling if entangled in gear and often show only impressions.*





MULTIFILAMENT TWINE IMPRESSIONS appear as a series of parallel, angled lines or ovals in a furrow (||||||||||||||||||) (left; © Virginia Aquarium).

*The IMPRESSION on the dorsal fin of this bottlenose dolphin (*Tursiops truncatus*) is thicker than most monofilament seen in the area (VA), but there are no details (such as parallel, linear, diagonal marks) within the impression to indicate that the twine was multifilament. There are similar lesions on the flukes. Detailed Exam: YES for signs of HI, Type of Lesion = Impression, Gear = Net, Twine Type = CBD, (right; © Virginia Aquarium).*

LINE can leave IMPRESSIONS with a series of parallel, angled lines or ovals (larger than twine), or abrasions like these around the base of the peduncle (left; © Virginia Aquarium). Note also the tooth rake marks on the dorsal keel (see section 5.1 for more examples).

Lacerations are injuries which occur when the skin/pelt is penetrated. Net and line usually leave linear lacerations. These lesions may be either evenly spaced or bunched along an appendage and may be accompanied by impressions. They may be associated with twine, net, or line. Lacerations associated with entangling forms of HI most often occur on the leading edges of appendages and on the rostrum/snout and mandible.

*Bottlenose dolphin (*Tursiops truncatus*) with lacerations on the mandible and rostrum associated with fishery interactions (right). The animal also had several impressions encircling the head. It may have hit a net, received the lacerations, and then broken through the meshes until the head was caught. Sometimes the head goes through the net and the animal gets caught at the dorsal fin. In pinnipeds, the neck, appendages (especially between the claws), and the mouth are the areas most susceptible to lacerations (© Virginia Aquarium).*



*Harbor seal (*Phoca vitulina*) with LACERATIONS around the neck (left) from entanglement in a gill net (© Virginia Aquarium).*

*MICROFILAMENT BRAIDED TWINE, sold under names such as PowerPro™, Spiderwire™ and Firewire™, is a very strong, abrasive twine marketed to recreational rod and reel fishers. Experience with it in strandings is limited, but devastating, as seen in the lacerations on the flukes and dorsal fin of this bottlenose dolphin (*Tursiops truncatus*, below; © Virginia Aquarium).*

Abrasions that are associated with fishery interactions tend to occur when heavy (thicker diameter) twine or line is involved in an entanglement. They can occur at the primary entanglement site (appendages, head, *etc.*) and also along other surfaces of the body (flat, lateral surfaces of appendages and body) when gear is trailing from an animal and continually scraping against a body part.

*This stranded humpback whale (*Megaptera novaeangliae*) had deep lacerations consistent with entanglement at the angle of the mouth on both the left and right sides. The gear apparently rubbed against the ventrum causing* ABRASIONS *on the ventral grooves (left; ©NC Wildlife Resources Commission).*

*The minke whale (*Balaenoptera acutorostrata*; right, below) stranded on Nauset Beach, Orleans, MA in June 1999. Although no gear was present on the animal, abrasions and lacerations were present on the head, base of dorsal fin, flukes, peduncle, and left flipper. The* ABRASIONS *were consistent with entanglement in line that went through the mouth and extended out the left gape and across the body surface wrapping around the dorsal fin (right).The nature of the entanglement and staining in underlying tissues suggested that the entanglement was antemortem (©IFAW Marine Mammal Rescue and Research).*

Remember that even when HI wounds are healed, it is important to record your observations. Healed HI scars represent human interaction and should be recorded as such, regardless of whether or not the HI may have contributed to the stranding.

*A short-finned pilot whale (*Globicephala macrorhynchus*) with scars consistent with healed trauma from prior hooking injury on the right lip (left; © NC Wildlife Resources Commission). Several teeth in the upper jaw beneath the healed lip scars were broken, a classic sign of a hooking entanglement. Injuries of this type on pilot whales are consistent with longline entanglement; however, without gear present it is most conservative to note hook as the type of gear without being more specific.*

*Common dolphin (*Delphinus delphis*) that stranded in Virginia shows more subtle hooking (likely longline) entanglement scars than the pilot whale above. Teeth were broken between the two arrows on the upper lip. On cross section, the small white scar above the eye was curved, as if made by a hook (right; © Virginia Aquarium).*

*Fin whale flukes (*Balaenoptera physalus*) showing linear entanglement SCARS across the leading edge at the fluke insertion (left; © Virginia Aquarium).*

On pinnipeds and other marine mammals with pelts, fishery interaction is most obvious when gear is still attached. In some cases, gear will leave impressions and lacerations in the pelt that are obvious. Many times, there will be no external evidence once gear is removed.

*Gray seals (*Halichoerus grypus*) with large mesh, heavy TWINE IMPRESSIONS on the pelt, consistent with a local weir fishery which is a staked net fishery (left and below; © IFAW Marine Mammal Rescue and Research). Detailed exam: YES for signs of HI, Type of Lesion = Impression, Gear = Net, Twine Type = multifilament.*



*Harbor seal (*Phoca vitulina*) flipper with fine twine GILL NET ENTANGLEMENT (left, © IFAW Marine Mammal Rescue and Research).*

*Live gray seal (*Halichoerus grypus*) with entangling GILL NET gear. Note the gray float in the image at right. If constricting gear is removed, an animal that is not otherwise debilitated can recover without intervention (© IFAW Marine Mammal Rescue and Research).*

*Neck of a harbor seal (*Phoca vitulina*) showing laceration from monofilament gillnet gear (left; © IFAW Marine Mammal Rescue and Research).*

Harbor seal (Phoca vitulina) with a neck entanglement in a POT BUOY LINE (below; © Riverhead Foundation, Riverhead, NY).

It is important to note that nets may leave different types of marks on an animal depending on the material from which they are made and the body part with which they interact. Entanglement in a net may leave impressions on an animal, or may cause lacerations or abrasions, or all three on the same animal in different areas. In many cases, a combination of lesions is associated with entanglement in a net. Nets made of monofilament may leave multiple impressions or lacerations, but each lesion is a straight furrow. Nets will usually leave a different set of marks than a single piece of twine. On cetaceans, look for 'X' shaped lesions (especially on the leading edges of appendages), and impressions of mesh or darker points along a linear impression indicating a knot. Net will often bunch up at the widest point of an appendage, at the insertion of an appendage, or on the body. Look around the head, at the insertion of the flippers and flukes, and base of the dorsal fin for bunching.

*The flukes of this bottlenose dolphin (*Tursiops truncatus*) have a laceration on the leading edge with granulomatous tissue (inflammatory reaction) indicative of a long-term entanglement. It is likely that whatever material caused the lesion was carried by the animal for a long time (weeks to months). Twine and line of differing diameters can cause this type of lesion. Since there are also lesions on the other fluke blade and on other parts of the animal, it was scored as a fishery interaction, but the origin of this particular lesion was unknown (right; © Virginia Aquarium).*



*Peduncle of a bottlenose dolphin (*Tursiops truncatus*) showing an UNKNOWN MARK possibly made by chain. The origin of this mark would be noted as "CBD" on the datasheet unless the observer had previous experience with a lesion like this from a known source (above; © Virginia Aquarium).*



Above, the skin of a bottlenose dolphin (Tursiops truncatus) shows MULTIFILAMENT NET IMPRESSIONS. Note the diagonal twist marks within the impression. In Virginia, this twine is consistent with pound net gear (© Virginia Aquarium).

*Ventral flukes of a bottlenose dolphin (*Tursiops truncatus*) showing MONOFILAMENT NET IMPRESSIONS consistent with gill net entanglement. Note the single furrow of the monofilament above compared with the 'hatch marks' within the furrow of the mutlifilament marks above left (© Virginia Aquarium).*

When a net is recovered from a stranded animal, it is important to measure both the size of the overall net (dimensions of the float or lead line or number of meshes in height/width) and the size of each mesh (stretch and square size). Also note where in the gear the animal was entangled. Be sure to document the animal in the gear, and then thoroughly document the animal and gear separately once the gear is removed (Often a heavily entangled animal will have few obvious marks present once the gear is removed). This process will allow examiners to characterize the types of wounds caused by that particular type of gear. This case can then be compared with animals that strand without gear in an attempt to characterize what type of gear may have been involved. Collected gear should be tagged, secured, and transferred to the regional NOAA Gear Lab for identification (contact your regional coordinator for address).

Fishery interaction summary

Characteristics of entanglement are similar in cetaceans and pinnipeds, though the presence of fur in pinnipeds makes lesion detection difficult.

External evidence in cetaceans:

- Gear present
- Linear impressions
- Linear lacerations
- Encircling lesion (constrictions) most commonly pectoral flippers
- Abrasions

- Wounds usually most prominent on the head and leading edges of appendages

Internal evidence in cetaceans:

- Subdermal hemorrhage and bruising
- Hemorrhage associated with lesions

External evidence in pinnipeds:

- Gear present
- Lesions on body (impressions, lacerations & constrictions)

Internal evidence in pinnipeds:

- Subdermal hemorrhage and bruising
- Hemorrhage associated with lesions



*This bottlenose dolphin (*Tursiops truncatus*) was moderately decomposed externally and had twisted twine impressions at the tip of the mandible consistent with entanglement (above). A thorough internal examination revealed subdermal tissue staining consistent with hemorrhage behind the head (left). When a cetacean's rostrum/mandible are entangled ante- or premortem, struggling often results in hemorrhage observed grossly as tissue staining (©Virginia Aquarium).*

In some cases, the external exam may ***suggest*** fishery interaction, but not be clearly conclusive, (*e.g*. when only one or two marks are observed or when marks do not occur in the areas where you expect them to occur. In these cases, as in all cases, it is important to complete a full examination before drawing any objective or subjective conclusions. There are some observations that, while not considered ***evidence*** of fishery interaction on their own, are considered findings that are ***consistent with*** fishery interaction. These findings can be used to support findings of fishery interaction and include:

- Froth in lungs
- Evidence of recent feeding
- Robust body condition
- Other, similar cases at the same time in the same place

Perhaps the best way to understand how to examine marine mammals for signs of human interaction is to review case studies. The aim of every exam is to collect data and documentation in enough detail to allow an outside observer to review and understand the case at any point in time. While confounding variables (see Chapter 5.0) may limit or prohibit this ability, sufficient case data should be available for any animal in relatively good condition that has been completely examined. Regardless of the circumstances, the examiner should always provide enough data and accompanying documentation to allow an outside reviewer to both analyze the case AND understand the conclusions that were made and why. The case study offered below is based upon photo-documentation, data sheets and necropsy reports from a stranded marine mammal. All comments in the text can be found in the appropriate locations on the accompanying data sheet. Note that the information in this and other case studies in this document follow the general flow of the datasheet.

Case Study #1: Fishery interaction on a dolphin

CASE HISTORY: The bottlenose dolphin (*Tursiops truncatus*; VMSM 20031091) carcass was reported to Virginia Aquarium Stranding Response Team (VAQS) by the general public on the afternoon of 27 October 2003. The carcass was transported to VAQS. It was photographed, measured, and evaluated for HI and then stored in a walk-in cooler until necropsy on 30 October 2003 (it is important to note the storage conditions on the datasheet). Histopathology samples were collected and submitted to the Armed Forces Institute of Pathology (AFIP); results were received in May 2004.

EXAM INFORMATION (lines 1-7):
Condition code: 3
Preservation: fresh
Body Condition: not emaciated
Integument: normal
% Skin missing: <10%

This dolphin was a very early condition code 3 (moderately decomposed). The tongue was not bloated, but the carcass had some odor and the genital slit was slightly bloated. The carcass

was examined fresh and was not previously frozen. It was not emaciated. The skin (integument) was not sunburned or peeling and there were no gross abnormalities. There was no skin missing. All images were taken with the VAQS digital camera and were stored at the VAQS facility. (Note: all of these data are captured at the top of page one of the Human Interaction Evaluation data sheet, See page 32.)

Be sure to complete lines 4-6 on the data sheet which detail the external condition of the animal: this section adds information critical to understanding the quality of the human interaction evaluation - information that cannot be obtained from the Level A data sheet. For example: Condition Code, which takes into account both the external and internal condition of the animal, can represent a broad spectrum of circumstances. A code 3 (moderately decomposed) bottlenose dolphin could be very close to pristine with only minimal bloating and odor. This animal may have its skin intact and may look very much as it did when it was alive. Alternatively, a code 3 bottlenose dolphin could also have almost none of its skin remaining or be severely sunburned and desiccated. While the former example ("fresher" code 3) may be easy to fully examine for HI, the latter example ("late" code 3) may be very difficult to evaluate for subtle marks associated with some fishery interactions. Thus it is very important to note the key aspects of the external exam noted in lines 4-6.

WHOLE BODY EXAM (lines 8-16):

- Appendages
- Pelt
- Body sliced
- Gear/debris
- External pathology
- Natural markings
- HI lesions
- Scavenger damage

Before beginning a detailed exam, take a look at the whole animal. If possible, look at all angles and surfaces. Following your whole animal exam, check the most appropriate choice for each category (lines 8-15). If you check YES or CBD, describe what you see in the Comments section on the next page, noting the appropriate line number. Indicate whether you collected an image of an area with a Y (Yes) or N (No) in the Image taken section. If you are unable to examine any areas (NE), note the details in the Comments section.

If there is evidence of predation or scavenger damage, circle the number(s) that correspond to the anatomical areas (found in table below) where evidence is seen and note details of the damage in Comments.

In this case, natural markings (tooth rakes) and HI lesions from fishery interaction were noted during the whole body exam. Notes for each observation are in the Comments section on the second page of the data sheet.

DETAILED EXAM OF ANATOMICAL AREAS:
Signs of human interaction noted on specific body parts are captured in the Detailed Exam of Anatomical Areas section of the data sheet. Follow the lines in the table to direct your exam. To complete this section, examine each body part closely on all surfaces for any evidence of human interaction. Examine the animal carefully starting at the head and working caudally down the right and then left side, finishing with the tail or flukes. For this section, indicate whether you observe any SIGNS OF HUMAN INTERACTION in each anatomical area by checking the YES, NO, or CBD column. If you were not able to examine an area, check NE; if it does not apply to your animal, check NA (*e.g.* pinnipeds do not have a dorsal fin). Be consistent; examine anatomical areas in the same order each time you do an exam. In this case, evidence of human interaction was noted on the following body parts:

- Rostrum
- Mandible
- Head
- Flippers
- Dorsal fin
- Peduncle
- Flukes

All observed signs of HI were impressions or lacerations consistent with monofilament net entanglement.

Mandible and rostrum: Lacerations on the mandible and impressions on the melon and rostrum. Unaltered image is above left and marks are highlighted in the altered image is above right (all images in the case study ©Virginia Aquarium).

Dorsal fin: Lacerations were present on the leading and trailing edges and impressions were evident on the lateral surface (original image-left & highlighted image-below left).

Right flipper: The mark at the insertion of the flipper encircled the appendage and caused a laceration at the caudal insertion. Lacerations were present on the leading edge (original image-above right & highlighted right).

Peduncle and leading edge of the right fluke: Impressions and lacerations present on the peduncle. Additional lacerations present on the leading edge of fluke and impressions found on the ventral fluke surface (below left). Ventral right flukes: Lacerations noted on leading edge and impressions noted on ventral surface (below right).





PROTOCOL FOR EXAMINING MARINE MAMMALS FOR SIGNS OF HUMAN INTERACTION

Exam Information *(fill in or circle most appropriate)*

1 Field #: VMSM20031091 Species: *Tursiops truncatus*

2 Examiner: Sally Smith Recorder: Pam Jones

3 Date of exam: 27 Oct 2003 Condition code (at exam): 1 2 (3) 4 5 CBD

4 Preservation: alive (fresh) frozen frozen/thawed Body condition: emaciated (not emaciated) CBD

5 Documentation: (digital) print slide video Image disposition: VMSM

6 Integument : (normal) abnormal decomposed % Skin missing: (<10%) 10-25% 25-50% >50%

7 Explanation of terms:
YES = I have examined the area and found signs of human interaction
NO = I have examined the area did not find signs of human interaction
CBD = I have examined the area and could not determine whether there were signs of human interaction (i.e. the part was missing, degraded, or signs were ambiguous)
NE =I did not examine the area
NA = this animal doesn't normally have that part (i.e. seals have no dorsal, dolphins have no rear flippers)

	WHOLE BODY EXAM	YES	NO	CBD	NE	NA	Image taken
8	Appendage(s) removed / Mutilation *(with instrument)*		x				
9	Pelt removed / Mutilation *(with instrument)*					x	
10	Body sliced / Mutilation *(with instrument)*		x				
11	Gear / Debris present on animal *(including tags)*		x				
12	Gear / Debris retained *(name & contact info in Comments)*					x	
13	External pathology *(pox, tattoo lesion, abscess)*		x				
14	Natural markings *(scars, tooth rakes, unusual pigmentation)*	x					y
15	HI lesions *(fishery, gunshot, propeller, healed HI scar, brand)*	x					y

16 Predation / scavenger damage *(circle all anatomical areas where damage hinders evaluation; numbers coincide with anatomical areas below)*: 17 18 19 20 21 22 23 24 25 26 27 28 29 30 (NONE)

FILL IN TABLE FOR **ALL POSSIBLE FINDINGS OF HI**
Do not use for natural markings/pathology.

						Type of Lesion					Origin of Lesion: Gear - Twine Type						Origin of Lesion: Other			
	DETAILED EXAM OF ANATOMICAL AREAS	YES	NO	CBD	NE/NA	Impression/ Laceration	Penetrating wound	Healed HI scar	Abrasion	Other / CBD	Twine / line	Net	other / CBD	Monofilament	Multifilament	CBD	Propeller	Gunshot	Other / CBD	Image taken?
17	Rostrum/snout	x				x						x		x						y
18	Mandible	x				x			x			x		x						y
19	Head	x				x						x		x						y
20	L Front appendage	x				x						x		x						y
21	R Front appendage	x				x						x		x						y
22	Body R L		x																	
23	Dorsum/dorsal fin	x				x						x		x						y
24	Ventrum		x																	
25	Peduncle	x				x						x		x						y
26	L Rear appendage				x															
27	R Rear appendage				x															
28	Flukes/tail	x				x						x		x						y
29																				

IFAW & VAQS Data Sheet (finalized 5/2012)

Dorsal flukes: Leading edge impressions and lacerations are evident. Note the tooth rakes on the right leading edge and distal third of the fluke (right).



For each mark you observe, proceed to the Type of Lesion columns and check all that apply (*e.g.* impression, laceration, pentrating wound, *etc*.). If necessary, refer to the data sheet instructions to review the definitions for the different types of lesions (wounds). Once you determine the type of lesion, move to the Origin of Lesion section and check all that apply. Remember to be conservative. If you are unsure of the origin (source) of a lesion, choose CBD.

Every area that scores YES or CBD should have an IMAGE TAKEN with identifying information (field number, date of stranding, species, examiner, subject of image, *etc*.) and a scale (small ruler or something of known size). If film or disk space is not limited, take pictures of all areas. Note Y (yes) or N (no) in the IMAGE TAKEN column.

Every area that scores YES or CBD should have a comment associated with it. Number each comment with the corresponding line number for that anatomical area. Be sure to provide detailed information, such as the location on the anatomical area (*e.g*. leading edge of right pectoral flipper, measurements, *etc*.).

INTERNAL EXAMINATION – When dealing with a carcass, an evaluation is not complete without a thorough necropsy (internal examination). (Obviously, for live animals, an external exam is likely the only option (unless you have access to radiography and other diagnostics). Some forms of interaction are only evident through internal exam (*e.g*. ingestion of debris or gear), thus the Findings of Human Interaction (objective conclusion) for an animal with NO external evidence of HI may be changed to YES if necropsy reveals internal evidence such as debris ingestion. Likewise, the Initial Human Interaction Evaluation (subjective conclusion) may change if an animal with external evidence of HI (YES) is found to be suffering from disease, pregnancy complications, or injuries that likely contributed to the stranding. When this occurs, note that the objective evaluation remains YES, but the subjective evaluation changes since a more likely cause for the stranding is determined. Some internal observations can support a diagnosis of HI (*e.g*. for fishery interactions-full stomach, froth in lungs). Be sure to note the date of the internal exam in the INTERNAL EXAM box.

Field #: VMSM20031091

	INTERNAL EXAM Date 30 Oct 2003	YES	NO	Partial	CBD	Image taken	Detailed Info *(circle all that apply)*
30	Internal exam conducted	X					*Details in Comments section -use line number*
31	Bruising/blunt trauma		X				*Details in Comments section -use line number*
32	Skeleton examined	X					*Details in Comments section -use line number*
33	Broken bones present		X				*Associated tissue reaction: YES NO CBD*
34	Mouth/GI tract examined *(circle contents)*			X			*intact prey* *partially digested* *hard parts only* ***debris/gear*** *empty* *other*
35	Lungs/bronchi examined	X					*Details in Comments section -use line number*
36	Lung/bronchi contents	X					*froth* *fluid* *air* (color: white & pink)
37	Bullet/other projectile found		X				*found using: CT X-ray dissection (collected? Y N)*
38	Other lesions noted		X				*Details in Comments section -use line number*

39 **Comments** (*note line number from left margin before each comment*):

17-29. all marks consistent with monofilament net
34. 8 intact fish in fore-stomach (menhaden?), parasites in main stomach, fluid in main & pyloric, intestines had contents
36. bloody fluid in pleural cavity-white foam/froth in left lung, pink in right lung, both lungs had mild lung worm infestations
37. pancreas partially fibrotic, no *Campulla* seen

40 **Findings of Human Interaction:** ☒YES ☐NO ☐CBD (Exam Type: external__ internal___ both X_)
(transfer to Level A Datasheet)

41 Type of HI: (provide details in comments)

☒Entanglement (gear_X_ debris__ CBD__) ☐Gunshot ☐CBD/Other_____
☐Hooking (recreational__ commercial__ CBD__) ☐Vessel trauma (sharp__ blunt__ both__)
☐Ingestion (gear__ debris__ CBD__) ☐Harassment

42 **Stranding Event History/Circumstances:**

This animal stranded in an area where striped bass are being commercially fished just offshore. The fishery uses monofilament gill net and is the only active fishery reported in the area according to state fisheries officers. This *Tursiops* is one of 5 with similar monofilament marks encountered within 2 weeks and all animals have been in good nutritional condition with evidence of recent foraging.

43 **INITIAL HUMAN INTERACTION EVALUATION:** If you circled YES above (line 40) evaluate the external exam, necropsy, carcass condition and circumstances surrounding the stranding event to answer the question below. *Remember to be conservative in your subjective evaluation.*

What is the likelihood that the finding of human interaction (line 40) contributed to the stranding event?

0: Uncertain (CBD) 1: Improbable 2: Suspect 3:Probable

44 **Justification:**

This was a robust animal with evidence of recent foraging, no gross indication of significant underlying disease, and multiple injuries consistent with entanglement.

Final human interaction evaluation requires additional data from level B and C analyses as well as review by a veterinary pathologist.

IFAW & VAQS Data Sheet (finalized 5/2012)

Internal examination findings in this case include:

- Skeleton examined - no broken bones
- Stomach examined - intact fish in fore-stomach, parasites in main stomach, feces in intestine
- Lungs examined - bloody fluid in pleural cavity, left lung had white froth, right had pink froth and appeared hemorrhagic
- No evidence of sub-dermal bruising or blunt trauma
- No other pathology observed - mild lung worm, 30% fibrosis in pancreas, bloody fluid in abdominal cavity

COMMENTS - You must record the details of your observations in this section. Provide comments for each item for which you checked YES or CBD. When describing lesions, include measurements (*e.g*. length, width, depth, and distance between lesions), location (*e.g*. measurement from nearest landmark – 20cm caudal of the right flipper), color, shape, and texture. Note the characteristics of the edges (*e.g*. jagged, straight, or rounded) and the direction of linear lesions (*e.g*. wraps from leading edge of dorsal fin to trailing edge on left side). Number each set of comments using the corresponding line number for that row on the data sheet. Use extra pages if needed and be sure to note the animal's field number in the upper right margin. If this information is provided in the necropsy report or other data sheet, reference that material here. Note that in this case study, details for each YES and CBD are recorded.

FINDINGS OF HUMAN INTERACTION - Review your exam notes, and circle YES if you observed any signs of human interaction on the animal. Circle NO, if you <u>thoroughly examined the animal</u> and did not find any signs of human interaction. Circle CBD if: (1) you did not examine the animal thoroughly, (2) decomposition or scavenger damage hampered the exam, or (3) you are unsure whether marks on the animal were caused by human interaction. This is an objective analysis. It does not take into account the animal's physical condition, the timing of the human interaction with respect to the stranding, or the circumstances surrounding the stranding. TRANSFER THIS INFORMATION TO THE SIGNS OF HUMAN INTERACTION SECTION ON THE LEVEL A DATA SHEET. This dolphin had multiple linear lesions consistent with monofilament net on most appendages. Signs of human interaction = YES. Also check the correct details in the parenthetical notes.

TYPE OF HI - If you circled YES for Findings of HI, check the appropriate box for the type of HI observed. Also check the correct details in the parenthetical notes.

STRANDING EVENT HISTORY/CIRCUMSTANCES - Provide any information about the stranding event or circumstances surrounding the event that would be helpful in determining the HI diagnosis (*i.e.* fishing, drilling, oil spill, unusual mortality events, previous sightings of animal, unusual behavior prior to stranding, or other activities, *etc*.). Note any objective details provided by the initial reporter. These may be answers to questions you have asked (*i.e.* was there any blood in the water next to the animal? What did it look or smell like when you first observed it? How was the animal positioned such as belly up, on its side, *etc*.?).

INITIAL HUMAN INTERACTION EVALUATION - This section should be completed if you

circled YES under Findings of Human Interaction Observed (#39). It should be completed after filling out the entire data sheet. This section is subjective and takes into account the animal's physical condition, necropsy findings, the timing of the human interaction with respect to the stranding, and the circumstances surrounding the stranding. Most importantly, it takes into account the evaluator's level of experience. If you have not conducted many evaluations or are not familiar with the region or lesions observed, you may be unable to make an accurate final evaluation. In this case study, necropsy revealed no obvious pathology. The animal had fed recently and, based on its robust body condition, had been feeding consistently prior to stranding, thus the evaluation is 3 (probable).

4.2 Debris Entanglement

Debris entanglements often involve live, free swimming animals that may be hard to recognize and capture despite obvious injury. Generally speaking, debris entanglement affects pinnipeds at a greater rate than cetaceans, but both are known to have become entangled in debris. Due to their inquisitive nature, young animals will often investigate objects in the water, which can lead to entanglement, usually around the head/neck. Documentation of these cases is important and may lead to information about potentially harmful objects found in the marine ecosystem.

Definition

Debris: In the context of marine mammals and human interactions, debris refers to any non-fishery related items found in the water column (or on shore in the case of pinnipeds). Debris

*Gray seal (*Halichoerus grypus*) entangled in an aerobie ™ frisbee (above; © IFAW Marine Mammal Rescue and Research).*

includes garbage, balloons, items washed into the water from vessels and run-off, and other sources. Almost any debris long enough to wrap around a mouth or flipper or with an opening large enough for an animal to insert its head poses a risk of entanglement.

Examples of debris entanglement

The most common and obvious form of evidence is the visible object in which the animal is entangled. In most cases, the debris remains on the animal for a long period of time, or even permanently, resulting in constrictive injuries as the animal moves and grows. Constrictions from entanglements can lead to abrasions, deep lacerations, infection, and death. Entanglements that involve the mouth and/or flippers can restrict feeding and locomotion and result in emaciation.

*California sea lion (*Zalophus californianus*) with plastic debris around neck (left; © The Marine Mammal Center in Sausilito).*

*Bottlenose dolphins (*Tursiops truncatus*), especially juveniles, are curious and interact with objects in their environments. One juvenile in Sarasota, FL became entangled in a Speedo™ bathing suit (above). The entanglement was constricting and the animal was losing weight (above left). The dolphin was captured, disentangled, and released (© Chicago Zoological Society and Sarasota Dolphin Project).*

*Elephant seal (*Mirounga angustirostris*) with plastic packing band embedded in neck (left; © The Marine Mammal Center in Sausilito).*

4.3 Debris/Gear Ingestion

Debris and gear ingestion are two forms of HI that usually exhibit no obvious external marks. Animals that have ingested indigestible foreign matter may be emaciated, but that is not always the case. Small amounts of debris may not affect normal feeding and digestion. However, some species seem more prone to debris ingestion. These include deep diving sperm whales and beaked whales. Some animals ingest foreign matter as a common, natural occurrence. Juvenile ice seals (harp and hooded) that strand in the northeast U.S. frequently ingest rocks and sand. These animals can die from the resulting gut impaction as a consequence of this potentially natural behavior (*i.e.* not human interaction). It is important to understand that you cannot rule out debris/gear ingestion unless you carefully examine the GI tract of an animal. Debris/gear ingestion is one of the few forms of HI that is nearly as detectable in a Condition Code 4 animal as it is in a fresh animal.

Definitions

The definitions of **Debris** and **Gear** remain the same as those described previously.

Ingestion: When an animal eats or swallows debris or gear, the result is HI classified as debris/gear ingestion. Ingested items may be found anywhere in the gastrointestinal tract: esophagus, stomach (all chambers), intestines, or colon.

Examples of debris/gear ingestion

As previously stated, there are often no external signs of debris/gear ingestion. In some cases, individual animals may become emaciated if the debris has caused a blockage or other complication in the GI tract. However, in most cases, the only evidence of HI is the debris or gear itself. In the case of live animals in a stranding or rehabilitation situation, the debris may pass through the GI system. However, the majority of the debris or gear ingestion cases will not be found until necropsy and examination of GI contents. All debris, gear, and associated lesions should be photographed (be sure to include labels and scale), tagged, and archived as evidence of the HI. It can be very useful to photograph the debris *in situ*, then remove it, place it on a board with scale and labels and photograph again.

*Clear plastic, rock, and feathers from a harp seal (*Pagophilus groenlandica*) stomach (right; © IFAW Marine Mammal Rescue and Research).*

*Gillnet found in main stomach of a long-finned pilot whale (*Globicephala melas*). The net was associated with an abscess (below left) in the stomach (below right; © IFAW Marine Mammal Rescue and Research).*

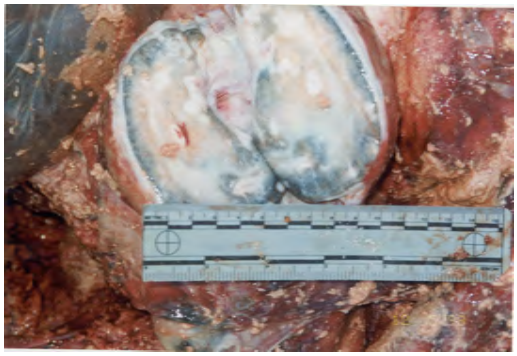

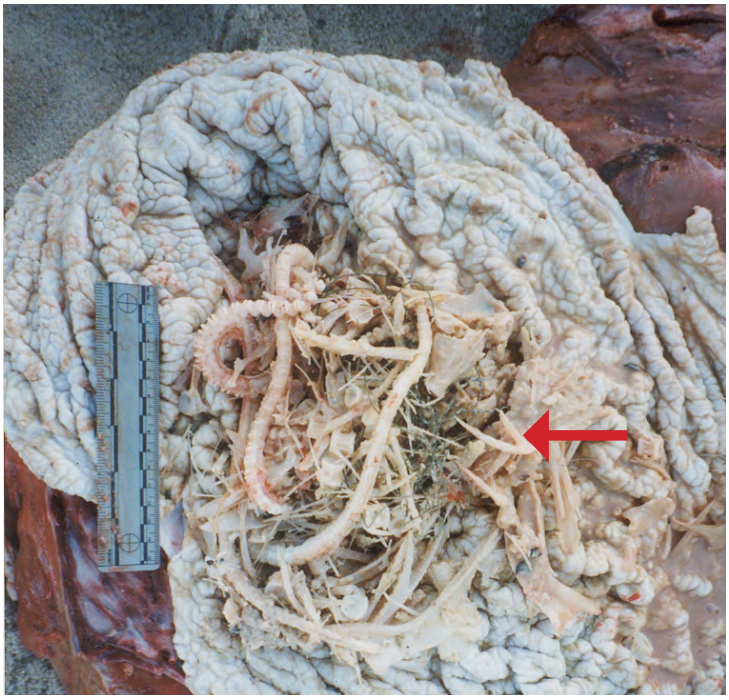

*Radiograph of a harbor seal (*Phoca vitulina*) showing a recreational bottom fishing rig including 2 hooks and a lead sinker in the GI tract (right, © Virginia Aquarium).*

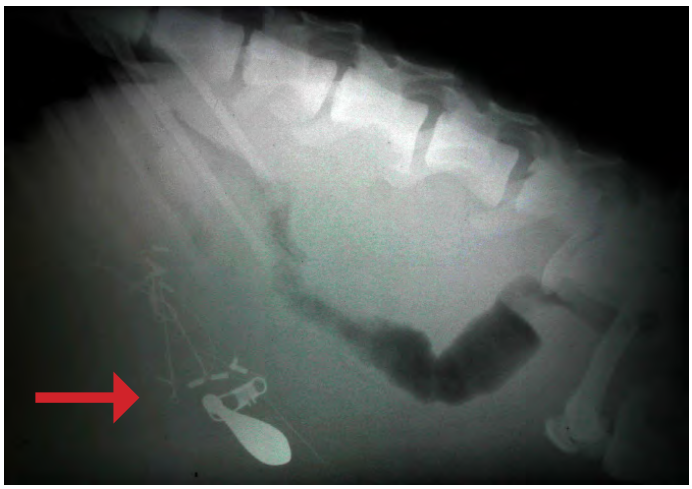

*Potato chip bag from the stomach of a pygmy sperm whale (*Kogia breviceps*; left). Parts of the bag were lodged in the sphincter between the main and pyloric stomachs, preventing food from passing through the gut (© Virginia Aquarium).*

Evaluating Debris/Gear Ingestion Cases

The harbor porpoise (*Phocoena phocoena*; below) stranded alive and was later euthanized. Upon necropsy, plastic debris was discovered in the forestomach (below; © UNC Wilimington).

FINDINGS OF HI = YES

Reaching a final evaluation can be problematic in debris and gear ingestion cases, especially when the amount of foreign substance is small. In this case, the harbor porpoise stranded alive, but emaciated. After hours in rehabilitation, it began exhaling worms and froth from the blowhole. It was euthanized and necropsied. Plastic debris was found in the stomach, but was not blocking sphincters. Was plastic ingestion a cause of or a symptom of illness? It was unclear whether the animal was already emaciated and compromised when it ingested the plastic (much like ice seals do with sand and rocks in New England) or whether it ingested the plastic and was then compromised because of the ingestion. The Final Evaluation reflects this uncertainty with a score of 2 (Suspect).

INITIAL HUMAN INTERACTION EVALUATION = 2 (SUSPECT)

4.4 Vessel Interactions

Vessel interactions can cause various forms of injury: sharp, intermediate, blunt, and a combination of these three. Sharp parts of vessels (often propellers) can cause sharp or penetrating trauma that is obvious upon external examination (in the form of characteristic wound patterns). The bow, keel, and other parts of vessels can cause blunt trauma that leads to internal injuries (sub-dermal hemorrhage, edema, internal organ rupture, internal hemorrhage and broken bones), often without any obvious external signs. For example, the hulls of small vessels can cause blunt trauma damage, especially in shallow water where an animal may be pinned against the substrate by the hull. Some blunt impacts, however, may leave external lesions.

Vessels inflict very different wounds depending on the vessel size, the part of the vessel that is involved (keel, propeller, bow, *etc*.; below), what part of the animal is involved, and its posture in the water prior to impact. It is imperative that a thorough internal exam accompany a finding of vessel interaction to determine whether the strike occurred before death.

Propellers are available in different sizes, have differing numbers of blades, varying pitch (angle of the blades), and direction of rotation. All of these variables affect the characteristics of the wounds resulting from propeller strikes. Vessels can have a single propeller or two propellers separated by varying distances. Two propellers can be side by side (*e.g.* twin engines on a small vessel), or mounted on the same axis (shaft) rotating in opposite directions. The latter configuration causes very unusual diamond or 'X' shaped lesions (see first Figure in section 4.4.1 images F and G). All of these factors combined with the varying size, shape, and movement of marine mammals makes diagnosis of propeller trauma challenging. Manatees are the marine mammal poster children for propeller damage and several excellent publications describe and analyze propeller trauma in manatees (Lightsey *et al*. 2006; Rommel *et. al*. 2007). The methods and measurements discussed in these publications are equally relevant to other marine mammals. By carefully documenting a suspected vessel trauma case, you may be able to discern antemortem or premortem trauma from postmortem trauma and to infer some characteristics about the vessel and the interaction. The examination and measurements detailed below are not likely to allow you to identify what specific vessel interacted with an animal, but they may allow you to determine the type or size of vessel or to rule out a specific vessel that is suspected of the interaction.



Definitions

Definitions of **Blunt force trauma** (blunt trauma) and **Sharp force trauma** (sharp trauma) remain the same as defined in the introductory section "Recognizing Human Interactions" under "Types of wounds/lesions observed."

In relation to vessel interactions, propeller wounds (or prop strikes) are the most common type of sharp trauma observed, but other vessel and engine parts such as skegs (see image below) can cause sharp trauma as well. Injuries from propellers are most similar to chop wounds (DiMaio and Dana 2007).

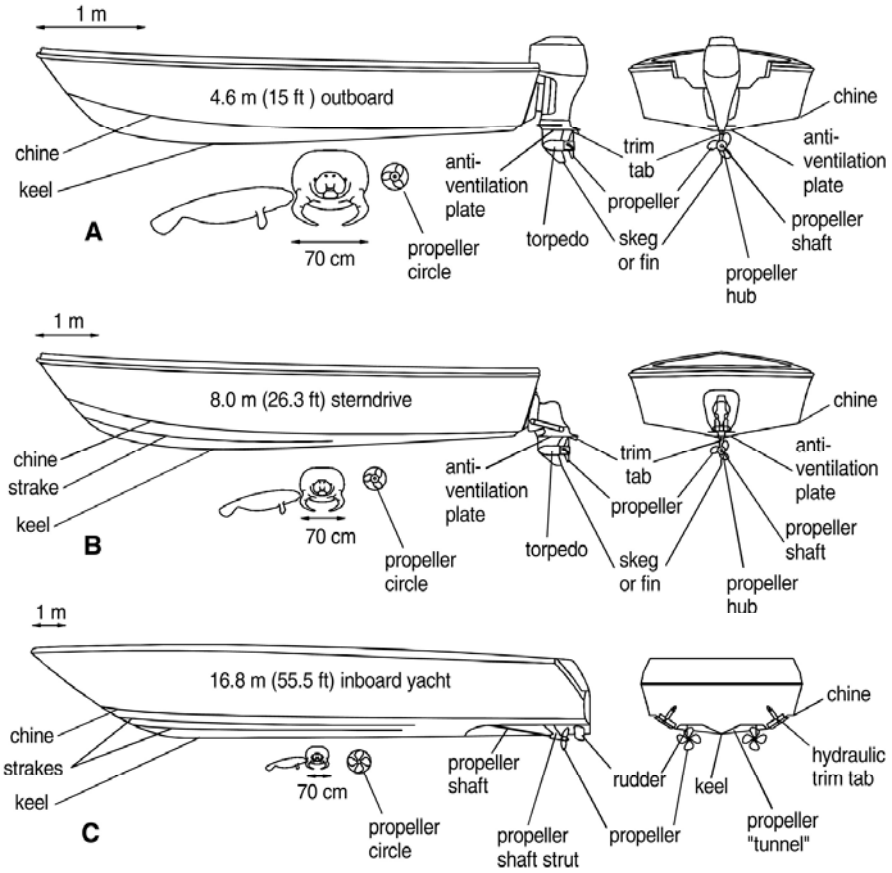

Smaller vessels (watercraft) exhibit a variety of hull, engine, and propeller configurations and sizes. This image from Rommel et al. 2007 illustrates several hull/engine configurations, highlighting parts that interact with manatees (left; © S. Rommel).

Propeller cut versus **propeller wound pattern**: Each lesion suspected to be involved with vessel interaction involving a propeller should be examined individually as 'propeller cuts' and collectively as a 'propeller wound pattern'. Measurements from each can add to your knowledge of the propeller(s) and, thus, the vessel type involved in the interaction. If there is a sequence of parallel lesions, such as those made by a single propeller, the examiner should number each lesion consecutively beginning at the cranial-most lesion. The numerical sequence in which the cuts are labeled represents the order in which they were measured, not the order in which the wounds occurred. In order to learn as much as possible about the vessel interaction, the following data should be collected on each propeller cut (Figure from Rommel *et al. 2007*): cut length, cut depth, wound axis, wound length, cut distance and propeller rotation (see definitions below).

Cut length: Using calipers (preferable), measure the straight length of each complete cut where both entry and exit points are visible (cuts that trail off a dorsal fin, keel, flipper, or fluke are not complete cuts). This straight measurement is most representative of the device that caused the wound. **The length of the longest cut provides a minimum estimate of the propeller diameter and is the best means of estimating propeller size**.

Cut depth: Cut depth is the maximum depth of a cut. This measurement provides an estimate of propeller radius and is useful when there are no cut lengths that can be measured on a carcass (*i.e*. there are no full cuts with both an entry and exit wound or beginning and end, such as when props cut through dorsal fins or flukes). A cut depth measurement is not possible when the injury penetrates into the body cavity or through an extremity. **In general, the deeper a propeller cuts in relation to its radius, the more distortion from a straight line you will see.** As seen in the illustration below, a shallow cut in relation to propeller blade radius (cuts number 13 & 14 image below) will leave a fairly straight cut, deeper cuts tend to be distorted into 'Z' or 'S' shapes (cut number 3 & 4 image below; adapted with permission from authors © S. Rommel).

Propeller wound pattern: The series of lesions caused by a propeller collectively forms the propeller wound pattern, which has dimensions and characteristics that can also be measured (refer to figure below; © S. Rommel):

Wound axis: If there are two or more propeller cuts, a wound axis may be determined. **The wound axis is a line passing through roughly the center of each cut in the series and is an estimate of the travel path of the vessel and its propeller**. If a substantial percentage of the length of the propeller blade is involved, then the entry point of each cut may have different characteristics from the exit point.

Wound length: The wound length is the length of the wound axis from the middle of the first to the middle of the last cut in the wound pattern.

Cut distance (or '**Cut span**'): Cut distance or cut span is the distance along the wound axis, between successive cuts in a single pattern and is **measured from leading edge to leading edge or from trailing edge to trailing edge**. The accuracy of these measurements is affected by wound contraction in antemortem injuries and degraded by postmortem distortion of the carcass (bloating and/or off-gassing). In general, the distance between cuts tells you about the pitch of the propeller. The closer the cuts, the greater the pitch of the propeller blades. Smaller and faster vessels usually have more angled (higher pitch) propeller blades. Larger, slower vessels and those designed for towing tend to have lower pitch propellers.

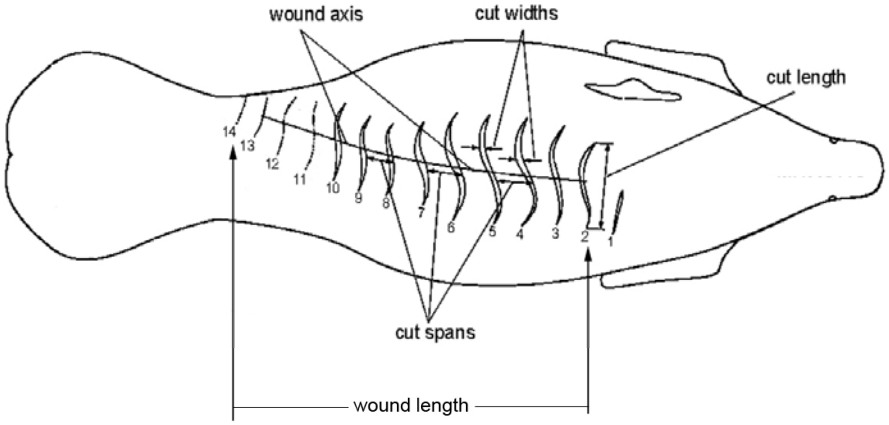

Propeller rotation (or '**Handedness**'): The propeller rotation refers to the direction a propeller rotates around its shaft when in forward gear. **If viewed from behind a vessel, right-handed propellers turn clockwise and leave a pattern of cuts slanted to the right along the wound axis. In contrast, left-handed propellers turn counter-clockwise and leave a pattern of cuts slanted to the left along the wound axis (**Figure from Rommel *et al. 2007*, below). In the US, most single propeller vessels have a right-handed propeller. If you see a single set of cuts from a left-handed propeller on an animal, the vessel was most likely a twin prop vessel (with two propellers side by side each turning in a different direction) and only the left-hand prop struck the animal.

4.4.1 Sharp Force Trauma

Propellers usually leave deep, roughly parallel wounds. Large propellers may bisect an animal.

Sharp force trauma from vessel interactions can be recognized by some common characteristics:

- Usually more than one lesion/cut
- Wound pattern often includes a series of lesions that are roughly parallel
- Individual propeller cuts have greater depth in the middle of the wound than at the edges
- Propeller cuts often form a corkscrew pattern
- Clean (not ragged) amputation of a fluke, flipper, or fin

When documenting sharp trauma from a propeller, it is important to gather as much data as possible about the wounds. These details may be useful in determining what part of a vessel and what type of vessel may have caused the wound(s). The following tips will guide the examiner in recording and documenting these events:

- Number the lesions starting at the head and move caudally
- Note the cut length and cut depth of each lesion
- Record the cut distance or span between each cut from the leading or trailing edges
- Determine the wound axis and wound length (remember the wound pattern is the series of cuts)

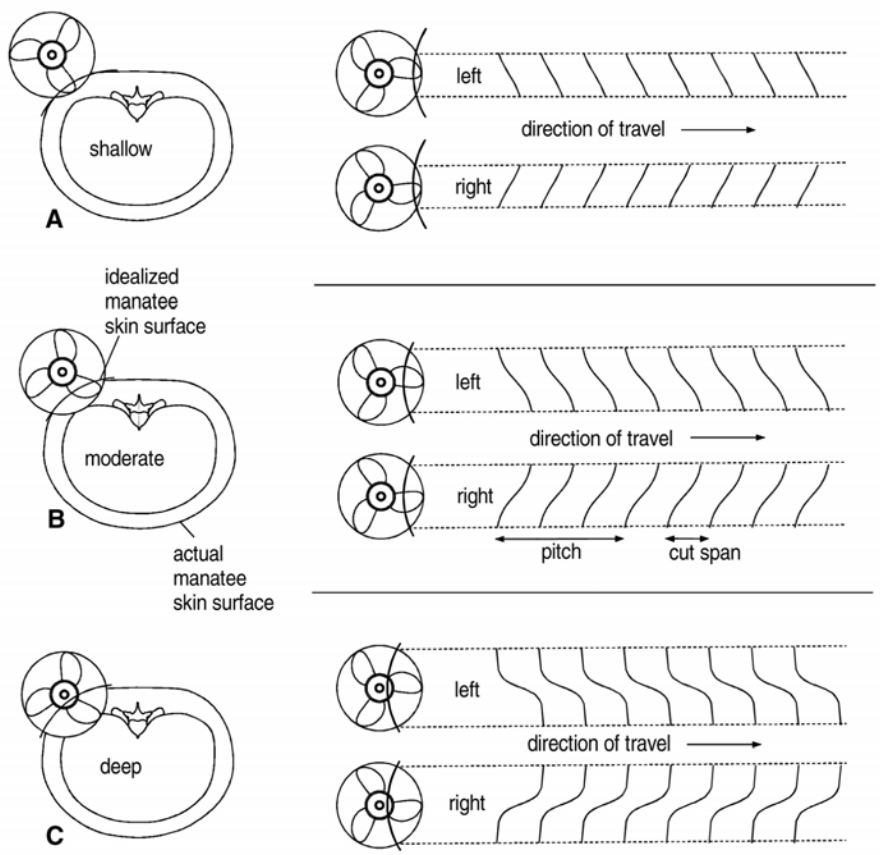

- Note the tissues affected (blubber & muscle, ribs, organs, *etc.*) and the amount of tissue staining consistent with hemorrhage (Note: staining or discoloration of tissues can have many causes, not all of which are related to trauma, including most commonly post mortem lividity.)

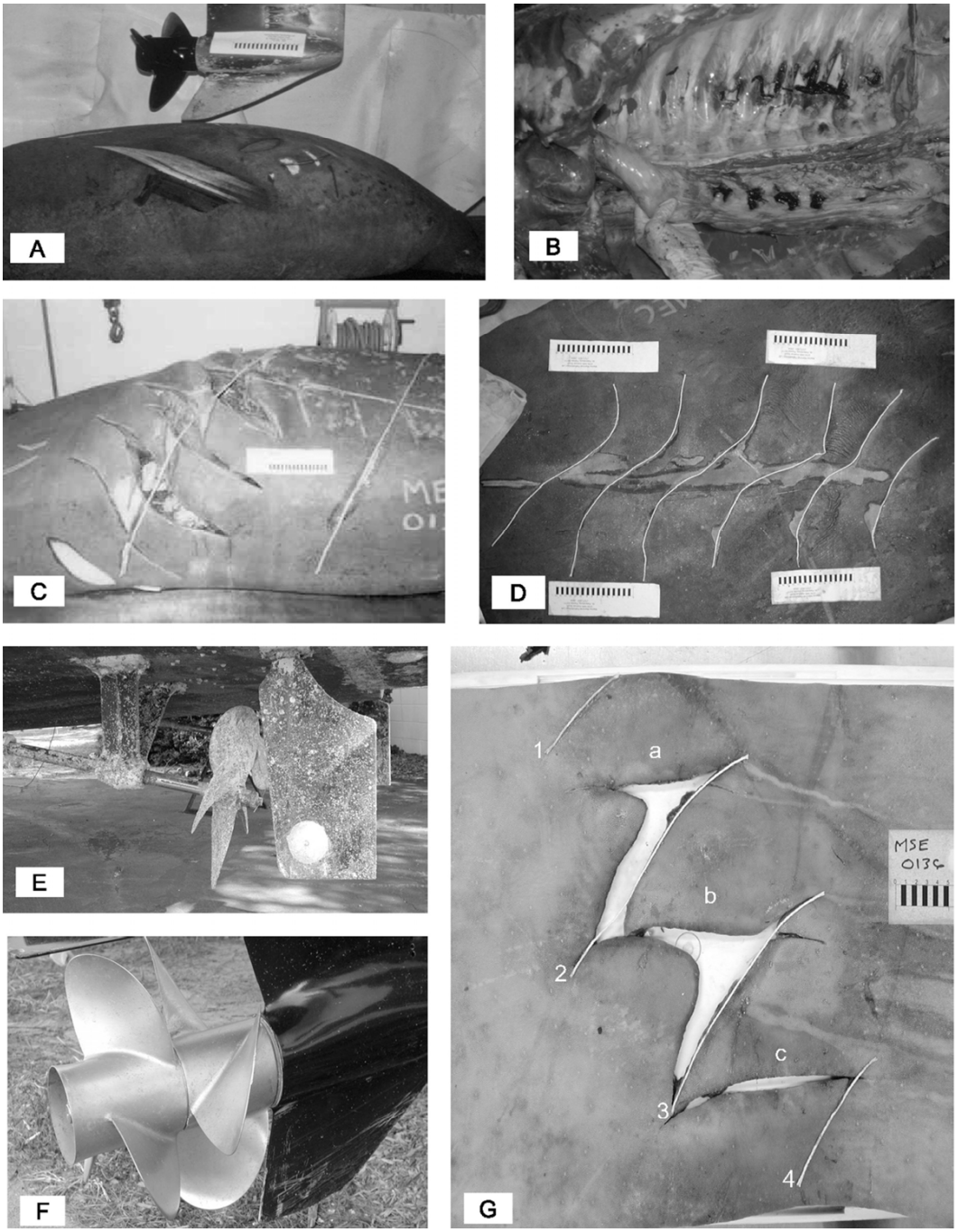

Examples of watercraft injuries in manatees and the propulsion system that was the most likely cause of the wounds (Rommel et al. 2007): (A) Skeg wound from an outboard motor (similar to the one suspended above the carcass; (B) Internal injuries from wound A; (C) Separate propeller and rudder wounds from a twin propeller inboard engine-left propeller caused the wounds; (D) Propeller and rudder wounds from a single propeller inboard engine and in-line rudder; (E) Propulsion system that caused wounds in image D; (F) Counter-rotating propellers on a single shaft; (G) Wounds caused by two counter-rotating propellers pictured in image F (used with permission from authors; © S. Rommel).

Evaluating Sharp Trauma Vessel Interaction Cases

This gray seal (*Halichoerus grypus*) has four parallel wounds penetrating deep to the bone on the caudal dorsum, to the right of the dorsal midline.

FINDINGS OF HI = YES

This dead gray seal (*Halichoerus grypus*) was reported to the stranding network on 9/8/04 as a seal hit by a boat with propeller wounds evident. The carcass was collected by the town Department of Natural Resources and transported to a landfill, where the carcass was examined on the same day. A partial internal exam (limited due to state of decomposition and logistical considerations) revealed sub-dermal staining consistent with hemorrhage in association with the wounds. An incomplete dissection revealed one cleanly cut rib associated with the wounds. Evidence of HI (vessel strike-sharp trauma) was present on the animal and observed muscle staining indicated that the propeller strike occurred before death and was the apparent cause of the stranding. Signs of human interaction=YES. Histopathology findings in conjunction with the details from the individuals reporting the event supported a finding of 3 (Probable) that the HI caused this stranding.

INITIAL HUMAN INTERACTION EVALUATION = 3 (PROBABLE)

Additional information from this vessel interaction case:

- *The wounds on the seal were straight (instead of 'S' or 'Z' shaped) indicating that the propeller in question did not penetrate deeply compared to its diameter. This makes any estimation of the propeller size using the cut length or depth an underestimate.*

- *The cut surface of the cranial side of each of the four lesions is curled under while the caudal side is completely exposed as a 'C' shape indicating the angle at which the propeller hit the animal. This suggests that the vessel was travelling from the animal's head toward its tail (in the opposite direction of the seal).*

Examples of sharp trauma caused by vessel interaction

*Large vessels with large propellers tend to create straight line cuts that are far apart like the 3 cuts on this humpback whale (*Megaptera novaeangliae*), noted when first sighted floating in Chesapeake Bay (left) and (below) after it washed ashore (© Virginia Aquarium).*

*Dorsal propeller wound pattern on a live stranded Gervais' beaked whale (*Mesoplodon europaeus*). This animal was observed alive in the surf. The injury obviously occurred premortem, but documentation is still important (above left). Of the four cuts, the shallowest was closest to the head and did not penetrate the blubber. The other three CUT WOUNDS penetrated through the blubber and into the epaxial muscle (above right). Examining the underside of the wounds is the best way to look for premortem tissue staining due to hemorrhage, as seen here in the blubber and muscle (above right; © Virginia Aquarium).*



*Sequential cut wounds in a live gray seal (*Haichoerus grypus*), with a close up at necropsy (left, © IFAW Marine Mammal Rescue and Research).*



*This gray seal (*Halichoerus grypus*) had at least two distinct propeller cut wounds that were partially obscured by shark predation/scavenging. The clean, straight line of the cranial-most wound extended from the left side across the back (top left) and the second cut wound appears to have amputated the left rear flipper (above right). The smaller, irregular wounds (which can mimic propeller wounds) on the ventrum (bottom left) are from the teeth of a large shark, most likely a great white (all images © IFAW Marine Mammal Rescue and Research).*

Examples of unusual sharp trauma caused by vessel interaction

Since 2009, an increasing number of severely damaged grey (Halichoerus grypus) *and harbor seal* (Phoca vitulina) *carcasses have been reported on the east coast of the UK (Bexton, et.al. 2012). Similar, but not identical, pathology has been observed in a number of harbour porpoise stranding in both the UK and other countries bordering the North Sea. The distinctive spiral appearance of the injuries has led to them being referred to as "corkscrew" wounds. (Andrew Brownlow pers. comm. 2012, June, SAC Wildlife Unit, Inverness, UK, IV2 4JZ). Work is underway to describe the propulsion system and mechanisms most likely to cause these lesions (Andrew Brownlow pers. comm. 2012, June, SAC Wildlife Unit, Inverness, UK, IV2 4JZ; all images this page © SAC Wildlife Unit).*

In seals, the distinctive lesion pattern comprises a single continuous, smooth-edged oblique laceration starting at the head and spiralling around the body. The wound edge is characteristically cleanly cut and the wound makes between one and three revolutions around the trunk.

In cetaceans, the trauma pattern broadly consists of two perpendicular lacerations beginning at the head and spiralling around the body. Wound margins also tend to be oblique and there is evidence of regular feathering to some wound margins, suggesting both smooth and serrated edges caused the trauma.

*The slow swimming, surface/sub-surface dwelling manatees (*Trichechus manatus*) are frequently struck by vessels. Many animals survive one or more vessel strikes and bear the scars of those interactions (right; © Florida Fish & Wildlife Conservation Commission).*

This is another example of a vessel strike on a Florida manatee (above). Note the serial nature of the cut wounds characteristic of a propeller strike. There are nine main cuts in the wound pattern that vary in depth into the underlying tissue. Also note the perpendicular lesion at the ventral edge, likely caused by the rudder or skeg of the engine (© Florida Fish & Wildlife Conservation Commission).

Evaluating a Decomposed Sharp Trauma Case

This was a lone, sociable bottlenose dolphin (*Tursiops truncatus*) that had been observed begging from boats. When the carcass was discovered, it was a code 4 (severely decomposed) with obvious propeller damage.

FINDINGS OF HI = YES

The size and orientation (corkscrewed around the body) of the lesions suggest an interaction with a fairly large vessel and that the propeller cut deeply into the animal compared to its diameter.

Despite suspicion that the dolphin was struck while it was alive, decomposition prevented us from determining if any tissue staining consistent with hemorrhage was present.

INITIAL HUMAN INTERACTION EVALUATION = 0 (UNCERTAIN, CBD)

This dolphin had been observed alone in a river for over 6 months. It was reported to be begging from boats and several calls from the public suggested that it was feeding on discarded bait from crabbers. Although the reported behavior of the animal indicates that it would have been susceptible to vessel strike because of its inclination to approach boats, we were unable to determine the likelihood that the HI contributed to the stranding due to decomposition.

4.4.2 Blunt Force Trauma

Blunt trauma from vessel interaction occurs when a blunt object strikes a victim with enough force to cause internal damage, often with only subtle external damage. When a marine mammal interacts with the hull or other blunt portion of a vessel, the interaction often results in fatal blunt trauma. The presence of unusual lumps, bumps, dents, or misshapen areas on a carcass can be an indication of blunt trauma. Other indications include: blood in the eyes, mouth, and nares (or blowhole). External signs of blunt trauma are not always evident, but, when present, they may include:

- Abnormal appearance of body shape (lumpy or misshapen profile)
- Swelling(s)
- Abrasions, lacerations, and/or discoloration/bruising

Internal evidence of blunt trauma is always present and serves as the primary diagnostic indicator. Internal evidence can include:

- Subdermal tissue staining which is consistent with hemorrhage and bruising (*e.g.* pink-tinged blubber or deep maroon/purple muscle tissue with a gelatinous texture)
- Edematous tissue
- Broken bones
- Organ damage

In almost all cases, blunt trauma is difficult to diagnose without a necropsy. In large cetacean carcasses, blunt trauma may result in one area decomposing faster than others internally. Because large whale carcasses do not cool down as readily as smaller animals, areas of blubber and/or muscle affected by trauma may appear more decomposed (often liquefied) than adjacent muscle and tissue. In fresh carcasses, organs affected by trauma may appear fractured or split. Broken bones, especially ribs, can also cause organ damage. In these cases, look for evidence of bleeding/hemorrhage associated with fractures and organ damage.

Examples of blunt trauma caused by vessel interaction

*Fin whale (*Balaenoptera physalus*) carcass in Virginia with a lesion later found to be associated with blunt trauma. The lesion was located on the left lumbar area just cranial to the dorsal fin (left). A close-up examination of the lesion reveals an ABRASION with missing skin and an area that is beginning to off-gas (below). When the blubber was removed from the side of the carcass, muscle below the lesion was very dark red and liquefied, while muscle adjacent to the area was lighter in color and a more normal texture. The transverse processes of the associated lumbar vertebrae were broken in this area. This hyper-decomposed area is supportive of pre- or antemortem trauma (below; all images © Virginia Aquarium).*

*Sometimes dead whales are found floating in inland harbors or ports, which are unlikely places to find live whales. These cases usually represent whales that have been struck by a ship and have been carried into port on the ship's bow. Lesions like the large 'dent' in the fin whale (*Baleanoptera physalus*) above are usually located about 1/3 of the body length from the tip of the rostrum. Shippers argue that whales are usually dead before they are hit by ships, but when these cases are examined, evidence most often supports ante- or premortem interaction (© Virginia Aquarium).*

*This harbor seal (*Phoca vitulina*) was recovered from a roadway in New York where a seal/vehicle interaction obviously occurred (left). Note the misshapen appearance of the head and neck (above left) and the bulging right eye (above right). Cases such as this, in which the cause of the trauma is obvious, provide an opportunity to document a known cause of HI. Through comparison, these cases help other responders in the field who may not have a 'crime scene' that provides clues to the cause of the trauma (© Riverhead Foundation, Riverhead, NY).*



Carcass of a seal rehabilitated and released by the Riverhead Foundation in Riverhead, New York and later found dead. Note the slight swelling on the dorsal surface of the neck and the bloody fur around the head (right). There was no obvious cut or penetrating wound on the animal. When the seal was examined internally, initial incisions revealed bloody blubber at the site of the swelling (below). While the trauma did not result in broken skin, the internal damage to the head and skull was massive, as shown here with the flesh reflected back to reveal a severe skull fracture and hemorrhage (below). The blunt trauma and case history suggest that this was likely the result of a vessel interaction. The seal was possibly hit by the hull of a vessel resulting in the traumatic head injury (© Riverhead Foundation, Riverhead, NY).

Example of blunt trauma NOT caused by vessel interaction

*Not all cases of blunt trauma are the result of human interaction. This bottlenose dolphin calf (*Tursiops truncatus*) appeared normal with the exception of tooth rakes and a small dent on the left side of the head (above). When the blubber was removed (left), discrete areas of tissue staining were obvious. Although this is considered blunt trauma, it was not due to human interaction. This was a case of infanticide where adult* Tursiops *inflicted the wounds seen on the calf (Dunn et al. 2002). Attacks and other natural events (such as birth) can result in blunt trauma, so collect data objectively and then analyze all findings (© Virginia Aquarium).*

Case Study #2 – Vessel strike with blunt force trauma

This sei whale (*Baleanoptera borealis*) in Virginia showed lesions on the right flank (below).

CASE HISTORY:
This sei whale (VMSM20031006) was reported floating in Norfolk harbor on 19 Feb 2003 by the US Coast Guard and was towed to a military beach for necropsy. The necropsy was completed on 20 Feb 2003.

EXTERNAL DESCRIPTION

Condition Code:	3
Preservation:	fresh
Body Condition:	not emaciated
Integument:	normal
% skin missing:	<10%

The left side of the whale showed no external lesions (right).

There were circular abrasions and a linear lesion on the right dorso-lateral surface above the pectoral flipper (right).

The whale was in fairly good condition with minimal bloating; it was marked as moderately decomposed (code 3). It was fresh when examined and was not emaciated. With the exception of the noted abrasions, the skin was intact and normal.

The location of the linear laceration and the abraded areas on either side of the linear mark indicate that the whale was most likely struck and then pinned against, and wrapped around, the bow (bulb) of a large ship. Although an exact vessel was not identified, the whale probably floated to the surface when the ship slowed or reversed to dock. An external examination alone allows us to score the carcass as YES for Signs of HI. However, without an internal exam, we cannot determine whether the whale was alive at the time it was hit.

WHOLE BODY EXAM:
The whole body exam, which can be challenging with large whales, revealed only the marks shown in the first photograph. The whale had a laceration perpendicular to the body axis from the dorsal midline extending ventral to the right flipper; the right flipper had no obvious injury. On either side of the laceration, there were large areas where the skin was abraded. The ventral and left sides had no obvious lesions. The initial exam centered on the tissue proximal to the linear lesion and abrasions.

DETAILED EXAM OF ANATOMICAL AREAS:
Following the data sheet, each anatomical area was examined. Given the good skin condition, the team was able to determine that, other than the linear laceration and rounded abrasions noted above, there were no other signs of HI present on the carcass.

Making cuts to remove blubber and examine underlying tissue (left).

We began the internal exam by removing the blubber from the right side of the carcass. Although there was an obvious external abrasion and laceration to the right thorax, internal exam showed no subdermal tissue staining consistent with hemorrhage beneath the wounds (below). There was no underlying tissue reaction to indicate that the whale was alive when hit. We continued the exam by stripping the blubber on the left side of the carcass.

On the left side of the carcass, we found bruising and hemorrhage associated with underlying rib fractures proximal to the left flipper (above left). Two ribs were fractured level with the mid-flipper on the left side (above right). There was obvious discoloration in the blubber and muscle consistent with hemorrhage caudal to the left flipper which was associated with the two broken ribs. The staining was deep into the muscle, including the intercostals (between the ribs). We sampled the stained blubber and muscle for histopathology and collected the ribs at the fractures.

Although the **external** evidence of ship strike was on the right side of the body, the **internal** injuries with associated clotted blood and edema (swelling) were on the left side. Other than these lesions and some intestinal parasites, the animal appeared to be healthy.

Based on gross observations, it appeared that the animal had actually been struck on the left side while alive. The body was probably trapped by the force of the vessel and then shifted or rolled to the right side, likely resting against the bulb on the bow of the ship, resulting in the (postmortem) external abrasions observed.

FINDINGS OF HUMAN INTERACTION OBSERVED = YES

There were obvious signs of abrasion from a large vessel on the right side of the whale. The internal evidence on the left side was consistent with blunt trauma.

INITIAL HUMAN INTERACTION EVALUATION = 3 (PROBABLE)

The external lesions on the right side appeared to be postmortem. The left side showed obvious subdermal damage consistent with antemortem/premortem blunt trauma. We felt confident that the whale was hit while it was alive. Histopathology results later confirmed the animal was alive when struck.

JUSTIFICATION: The laceration and abrasions on the right side were consistent with the whale being carried on a ship's bow for a period of time. Histopathology results showed that the internal injury on the left side occurred before death, indicating that the whale was probably struck on the left then shifted or rolled with the forward momentum of the ship so that the right side faced the bow. We think it was likely carried into port this way and then floated off when the ship slowed or changed direction. There were no other obvious pathologies other than a heavy parasite load in the intestines. Histology later confirmed our evaluation.

4.5 Gunshot Wounds

As defined previously, gunshot wounds are the result of ballistic trauma from firearms. These cases should be carefully documented. If you suspect gunshot or a similar injury prior to exam, contact a law enforcement officer and ask if s/he can be present at the exam.

If you discover wounds consistent with gunshot or evidence such as bullets or pellets during the exam:

- Contact law enforcement and your regional coordinator before completing the exam
- If possible collect a radiograph
- Take good pictures and/or video using a label and scale (see Chapter 3)
- Measure wounds (length, width, and depth)
- Use chain of custody for all evidence
- Avoid handling bullets or pellets with metal instruments. Store bullets and pellets in sealed paper envelopes instead of plastic bags or jars.

Definitions

Gunshot wound: wound produced by a firearm. Gunshot wounds will have different characteristics based on the type of firearm, type of ammunition (jacketed and unjacketed bullets, shot/pellets, slugs, *etc*.), angle of the shot, and the distance between the muzzle of the firearm and the body. Gunshot wounds inflicted on marine mammals are most likely to be distant wounds (>1ft) where muzzle imprints and gunshot residue will not be present.

Bullets are fired with firearms such as handguns and rifles. When a bullet passes through a body completely, it usually leaves an exit wound that is substantially larger than the entrance wound. This holds true when the bullet passes through bone. For example, if the skull is penetrated by a bullet, the side of the bone with the entry wound will have a sharp margin and the exit wound will be larger, exhibiting beveling and cracking, but not all bullets will exit.

Shotguns do not fire bullets. They fire a variety of different projectiles including different sizes of round shot/pellets as well as slugs. The entry wound from a shotgun may be quite large if the gun was discharged near the victim and nearly invisible if it was discharged at a distance (>10ft) and if the victim has a pelt. Shotgun wounds made with bird shot will be nearly round and ¾ to 1 inch in diameter at close range (up to 4 feet) and will become increasingly irregular with numerous individual pellet holes up to 10ft. Beyond 10ft, the pellets will spread out and become less detectable.

Radiographs (X-rays) are the best way to confirm gunshot if all or part of a bullet or shot/pellet(s) remain in the body of an animal. Probing tracts with blunt probes can facilitate detection of a bullet and extent of injuries, but samples should be taken first to avoid artefactual damage. Metal detectors can be useful in some cases to detect some types of projectile, but results are inconsistent and require confirmation by radiography or direct visualization.

Trauma characterized by hemorrhage, fracture, or secondary infection of any body part may occur in association with a gunshot injury. However post mortem gunshot wounds can ooze bloody liquid. Different projectiles fragment or pass through to varying degrees. Perforating holes may also be caused by bird beaks, mammalian canine teeth, gaffs, spears, and crossbow arrows. Bird peck holes are commonly identified as gun shot injuries by the public. Holes do not usually have distinguishing features to conclusively identify them as caused by guns.

Examples of gunshot wounds

*Harp seals (*Phoca groenlandica*) with close range shotgun wounds to the head (above). Radiographs revealed multiple pellets lodged in the tissue and bone (© IFAW Marine Mammal Rescue and Research).*

*Radiograph the harp seal (*Phoca groenlandica*) pictured on the left. The seal most likely sustained a shotgun wound from close range as evidenced by the skull damage (above; © IFAW Marine Mammal Rescue and Research).*

*Close view of a bullet wound in a California sea lion (*Zalophus californianus*; above). Note the fur has been shaved to expose the wound before surgery to remove the bullet (left; © The Marine Mammal Center in Sausilito).*

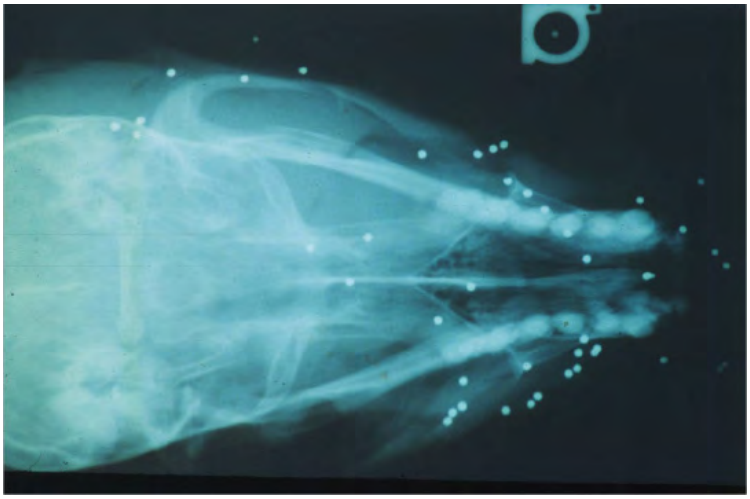

*California sea lion (*Zalophus californianus*) with bullet imbedded in forehead between the eyes. This animal was treated and survived (above; © The Marine Mammal Center in Sausilito).*

*Radiograph of a California sea lion (*Zalophus californianus*) with shotgun pellets in the head (left). The image shows the skull intact with numerous pellets imbedded in the tissue, suggesting a distance greater than 10ft from the firearm to the victim (© The Marine Mammal Center in Sausilito).*

4.6 Projectiles and other penetrating interactions

As defined earlier, a penetrating wound occurs when a foreign object punctures or deeply penetrates the body. They can be characterized as one of three types: stab wounds, incised wounds, or chop wounds (DiMaio and Dana 2007). As a reminder:

- **Stab** wounds are deeper than they are long (the wound visible on the external surface is short, but it penetrates deeply into the tissue). Stab wounds are caused by weapons such as gaffs or knives, or projectiles such as arrows or spears.
- **Incised** wounds are clean cuts into the skin and underlying tissue which are longer than they are deep (the opposite of stab wounds). These wounds are caused by sharp-edged objects such as knives or propellers.
- **Chop** wounds are incised wounds that penetrate deep to the bone, leaving a groove or cut in the bone and can be caused by propellers or other instruments.

Examples of other types of penetrating interactions

*California sea lion (*Zalophus californianus*) with an arrow penetrating the neck. Considering its emaciated condition, the animal may have survived for some time with the imbedded arrow (right; © The Marine Mammal Center in Sausilito).*

4.7 Harvest/Mutilation

In Alaska and limited areas of the lower 48 US states, hunting of some marine mammal species is legal, mostly by Native Americans. Gunshot and other penetrating wounds as well as knife marks on carcasses in these areas may be the result of legal harvest. Stranding responders should be aware of the legality regarding marine mammal harvest in their area and work with native hunters to recognize the signs of a harvested animal.

Mutilation of a marine mammal is usually a postmortem interaction. Its presence, however, is important to note in light of the Marine Mammal Protection Act. In addition, sometimes carcass mutilation is conducted by fishers in an attempt to disentangle animals from their gear, to sink a carcass, or conceal an interaction. Even when mutilation occurs legally, for example when a carcass is mutilated in the process of removal from fishing gear that is permitted to take marine mammals, it is important to document all of the evidence of HI. Although it is not illegal, the mutilation may be the only indication that an animal has interacted with gear and represents important data if documented correctly.

Definitions

Harvest: For the purposes of this manual, harvest is the legal hunting of marine mammals.

Mutilation: the intentional cutting or slicing of an animal or carcass. Mutilation generally involves the use of some type of knife or hand-held blade and can result in several common types of wounds (see penetrating wounds) and amputations including:

- Body sliced
- Appendages removed
- Body stabbed
- Body gutted

All of these wounds share the characteristic of having clean, smooth edges from the cutting implement. Body slices are the easiest type of mutilation to determine. Appendage/head removal can be problematic to detect if there is scavenger damage. If a carcass is scavenged in a body region where you suspect mutilation, look for knife cuts on bone (chop wounds) and areas where tissue is cleanly sliced in a straight line. The harbor porpoise (*Phocoena phocoena*) pictured below is typical of the mutilation observed in cetaceans along the mid-Atlantic US coast.

Pinnipeds and cetaceans are both legally harvested and illegally poached as well as subjected to mutilation. Animals entangled in fishing gear may be mutilated during the process of removal. Poaching is more common in pinnipeds and usually targets the reproductive organs for illicit sale.

Scavenger damage can hamper the observer's ability to determine if mutilation occurred. While the tissue on the head, flippers, and flukes may have been removed with an instrument, scavenger damage to the cut surfaces can make it difficult to assess. These cut surfaces are often the easiest targets for scavengers.

Examples of harvest/mutilation

*Harbor porpoise (*Phocoena phocoena*) from Virginia with BODY SLICE (left) and APPENDAGE REMOVED (dorsal fin, below). Since there is no harvest allowed in Virginia, this activity is considered mutilation (© Virginia Aquarium).*

*This bottlenose dolphin (*Tursiops truncatus*) stranded in Virginia with a BODY SLICE from larynx to anus (above). The unusual thing about this mutilation was that, in addition to the mutilation, all organs were removed (right; © Virginia Aquarium).*

Evaluating a Mutilation Case

In some areas of the United States, it is legal for certain people (particularly native communities) to harvest marine mammals or marine mammal parts for a variety of uses. These marine mammal interactions are legal and are not considered HI.

In most of the mainland US, however, taking of live marine mammals or parts of dead marine mammals is illegal without appropriate authorization, and never for resale. When some or all of a live or dead marine mammal is taken illegally (poached), we consider it a case of human interaction. When carcasses are cut open without any obvious attempt to harvest organs or parts, the damage done to an animal is considered mutilation, also a case of human interaction.

*This harp seal (*Phoca groenlandica*) carcass in Massachusetts was cut open and gonads were removed. Since there is NO harvest in MA, this is a case of illegal poaching/ mutilation and is considered a case of HI.* (*right; © IFAW Marine Mammal Rescue and Research*).

FINDINGS OF HI = YES

If the mutilation is postmortem, then the HI did not contribute to the stranding, but the circumstances surrounding the mutilation may be associated with the stranding event (*e.g.* fishery). Unless you have information that the animal WAS or WAS NOT affected by human activity prior to mutilation, you cannot accurately provide a Final Evaluation, therefore it must be scored as CBD.

Evaluation of mutilation cases is problematic since, in most cases, there is very little information about the circumstances surrounding the event. For example, was the animal caught in a net and its appendage(s) removed to get it out of the net or did it strand on the beach and a curious passerby removed the appendage(s) for a 'trophy'? In the former case, the mutilation would have been directly related to the stranding event. In the latter case it would not be related. If you don't know what happened, you should score the Initial HI Evaluation as 0 (Uncertain, CBD).

INITIAL HUMAN INTERACTION EVALUATION = Case dependent

4.8 Harassment/Human Interference

Perhaps the most difficult form of human interaction to address and document is interference or harassment.

Definitions

Harassment: Harassment is any human activity, intended or not, that causes an animal to change its behavior. Objectively, if the harassment is not observed by the responder, it is difficult to determine if it occurred, and even more difficult to document it. Subjectively, unless an animal is handled by the harassers (*e.g.* pinniped pup fed, petted, or collected by beachgoers), it is difficult to determine if the harassment caused the stranding event.

If human activity other than that of permitted stranding responders/researchers results in harassment, HI = YES must be the objective conclusion. This is true even if the animal is

dying and is harassed by being put in a truck to be moved by well-meaning (but un-permitted) rescuers. Perhaps the most common cases occur when beach goers push live animals back into the water after stranding. Even the carcass of a dead animal, if handled by unauthorized individuals, is considered human interference. In these cases, the illegal handling does not cause the stranding but, objectively, must be scored YES for signs of HI. However, the subjective evaluation and numeric score allow the examiner to take into account the circumstances surrounding the event = 1 (Improbable).

Although very little on the data sheet is directed toward harassment, it is a very real and prevalent form of HI, especially regarding live pinnipeds. On the data sheet, report a description of the harassment event, including names and contact information of witnesses, in the stranding event section. Indicate image documentation and where any images will be archived. The Initial Human Interaction Evaluation determination will depend on the circumstances of the stranding (or whether a stranding even occurred).

Examples of harassment

Beachgoer approaches resting seal (left; © IFAW Marine Mammal Rescue and Research).

*Feeding and swimming with wild cetaceans like this bottlenose dolphin (*Tursiops truncatus*) is illegal in the US and can lead to aggressive behaviors and reduced fitness (above; © NOAA).*

*Harbor seal weanling (*Phoca vitulina*) in MA being harassed by bystander (see shoes at top of image) (above; © IFAW Marine Mammal Rescue and Research).*

4.9 Unknown or Undetermined Interactions

Even with a broad understanding of marine mammal human interactions, some situations are difficult to understand. In some instances, it may be clear from the types of marks or signs on the animal that some form of human interaction has taken place; however, the exact cause or source of the interaction may not be obvious. When this occurs, it is still important to utilize this protocol to aid in consistently collecting and reporting the data. Do not try to over-interpret what you see. Unfortunately, there will always be some cases for which the cause of the interaction cannot be determined.

Evaluating an Undetermined Interaction Case

This Code 3+ bottlenose dolphin (*Tursiops truncatus*) was found with no skin and a cinder block tied to its flukes.

FINDINGS OF HI = YES

The carcass was found floating vertically (rostrum up) in a channel in VA anchored by a cinder block tied to its flukes. The attached cinder block was an obvious sign of HI; however the circumstances that led to this situation were not known. Perhaps a beach-front homeowner towed the carcass offshore and tied the cinder block to it hoping to keep the already dead animal off his/her property. Perhaps the animal was caught in fishing gear and the fisher removed it and weighed it down to make it sink. The only sign of HI was the attached cinder block which was no doubt postmortem (good luck tying a cinder block to a live swimming dolphin!), but it is impossible to know what actually happened. Since we cannot tell which of these hypothetical scenarios (or any other for that matter) may have led to the observed HI, we score the Initial Human Interaction Evaluation as 0 (Uncertain/CBD).

INITIAL HUMAN INTERACTION EVALUATION = 0 (Uncertain/CBD)

5.0 Confounding Variables

When conducting an HI evaluation, it is important to understand and acknowledge confounding variables. The best pathologist in the world cannot determine if HI is present on a severely decomposed animal. Understanding what can inhibit your exam and what can mimic marks made by human activities is a key part of conducting a thorough examination. This is where experience is helpful. Know what predators and scavengers occur in your region. If you have no other resources, leave a carcass exposed and revisit it repeatedly to see how it decomposes and what marks are left by local wildlife. Confounding variables can include:

- Natural and unknown marks
- Immediate death (exsanguination & asphyxiation)
- Predation
- Scavenger damage (aquatic & terrestrial)
- Decomposition (tissue degradation & bloating)

5.1 Natural and Unknown Marks

Because cetacean skin is delicate, many animals carry lesions and/or scars from conspecifics (members of their own species), predators, or prey. Scars from teeth or 'tooth rakes' are common marks seen on cetaceans. The rakes can be from conspecifics, which is common in the social delphinids, or from predators such as orca or sharks. Deep diving squid eaters such as sperm and beaked whales often have scars and impressions from squid tentacles and scars from cookie cutter sharks. Animals that carry hard barnacles such as humpback whales often have circular scars from barnacle attachment sites. All of these marks can obscure or even be mistaken for HI marks.

Cetacean skin shows impressions and lacerations prominently. Unfortunately, almost anything that touches it leaves marks on a cetacean's skin, which can make it difficult to distinguish natural marks from those left by human activities. In addition, after a cetacean dies, the skin degrades quickly both in water, where it begins to slough, and in air, where it desiccates and sun burns. For example, it is important to take note of the conditions under which an animal strands. Knowing that there is an oyster bar offshore of the marsh where a pilot whale stranded can help explain nonparallel linear lacerations on the ventrum.

*Dorsal view of the right fluke of a bottlenose dolphin (*Tursiops truncatus*) with both natural marks (tooth rakes-red arrows) and anthropogenic (human-made) marks (monofilament impression- yellow arrow). This bottlenose dolphin has both recent (darker gray) and healed (white) tooth rakes from other bottlenose dolphins. We know the rakes come from other bottlenose dolphins because of the inter-tooth distance. Other species will occasionally rake each other during social interactions. Bottlenose dolphins have been known to bite and rake harbor porpoises during aggressive interactions (right; © Virginia Aquarium).*

Examples of natural and unknown marks in cetaceans

*This stranded humpback whale (*Megaptera novaeangliae*) (right-dorsal surface of left fluke; below-ventral surface of right fluke) has healed tooth rake scars (white parallel lines in red circles) from killer whale teeth as well as a possible scar from a previous entanglement (red arrow). Note that the tooth rakes are on the flat surface of the flukes, and the possible entanglement scar wraps around the leading edge of the fluke and continues to the ventral surface (© Virginia Aquarium).*

*The flukes of a bottlenose dolphin (*Tursiops truncatus*) with unusual lacerations on the dorsal surface (above left). Wider angle view of the same animal (above right). Responders had attempted to retrieve the carcass on the previous day, but did not have the manpower initially to lift the animal over a bulkhead. They took pictures and returned the next day. Pictures from the first day do not show any marks on the flukes, thus we know the marks occurred postmortem. They could have been made by a knife, but it is also possible that a raptor (vulture or eagle) tried to scavenge the carcass. There were no other suspicious marks on the carcass. Not knowing what caused the marks, the responders scored the carcass as CBD (© Virginia Aquarium).*



*Neonate and perinate cetaceans like the bottlenose dolphins (*Tursiops truncatus*) above and right are both with fetal folds that appear as light colored lines or indentations. The umbilicus of a neonate/ perinate is very tender and erupts upon decomposition. Occasionally called in as entanglement, a thorough exam usually reveals that the 'line' around the animal is intestine. (© Virginia Aquarium).*

*A white-sided dolphin (*Lagenorhynchus acutus*; left) stranded in poor external condition (>50% skin missing) with unusual diagonal and 'X-shaped' marks on flank. This case is an example of a degraded animal with unusual marks. This white-sided dolphin had no epidermis on the right side, but it had several thick diagonal marks ~1cm wide and 10cm long. Some of the marks formed an 'X'. There weren't any marks on the leading edges of the dorsal fin, flippers or flukes. Unable to explain the marks, the responders scored it as CBD for HI (© Virginia Aquarium).*

Examples of natural and unknown marks in pinnipeds

Just as with cetaceans, there are times when it is difficult to determine if a lesion found on a pinniped is caused by HI. Pinniped pelts often do not hold the less severe, non-penetrating marks, such as impressions, that are readily visible on cetacean skin. Even when marks are present, it may be difficult to determine the source. In these cases, if you are equally unsure whether the marks are natural (due to predation, scavenging, or disease) or anthropogenic, score the lesion as Signs of HI = CBD.



*Harbor seal (*Phoca vitulina*) showing circumferential impressions around thorax and abdomen (above, left), and circumferential impression around left rear flipper (above, right). This live stranded harbor seal was brought to VAQS for rehabilitation. When it arrived, the fur was dry and, due to the animal's condition, it was kept dry for 24 hours. When wet the marks seen in these images became very prominent. There were no other external lesions on the animal. Unsure of the source of the lesions, the staff scored the animal as CBD for HI. If they examine animals known to have been entangled and observe similar lesions, they may reassess the diagnosis on this seal (© Virginia Aquarium).*

*Harbor seal (*Phoca vitulina*) found on rock jetty with unusual wounds to the head (above, left). In this case, the skull was opened and the brain removed (above, right). While it is not unusual for coyotes in the area to crush a seal's skull, it is uncommon for the brain to be the only tissue eaten. The responders were unsure what caused the lesion and scored it as CBD for HI. If, in the future, the source of the lesion is discovered, the diagnosis will be changed accordingly. Note that the rocks surrounding the animal are clean, showing no signs of struggle (© IFAW Marine Mammal Rescue and Research).*

5.2 Rapid Death

Injuries associated with a rapid death (premortem injuries) are common and include situations such as vessel trauma and underwater entrapment. Unfortunately, when injuries occur premortem (immediately prior to death) there is little or no time for tissue reaction before the animal dies. Thus, it can be difficult to evaluate (grossly and histologically) whether the lesions occurred when the animal was alive. This makes the subjective aspect of an HI evaluation challenging.

Examples of HI cases with rapid death

*This image (left) shows the ventral surface of the flukes of a right whale (*Eubalaena glacialis*). The left fluke of this whale was torn off exposing large vessels which likely caused the animal to rapidly bleed to death. Although, there was no histological support for premortem injury from this wound, a vessel reported hitting a whale of unknown species seven days prior to the stranding. Independently, a recreational fisher reported seeing a whale with half of a fluke bleeding profusely in the same area. This whale stranded approximately 50 miles south of the vessel strike location (© Virginia Aquarium).*



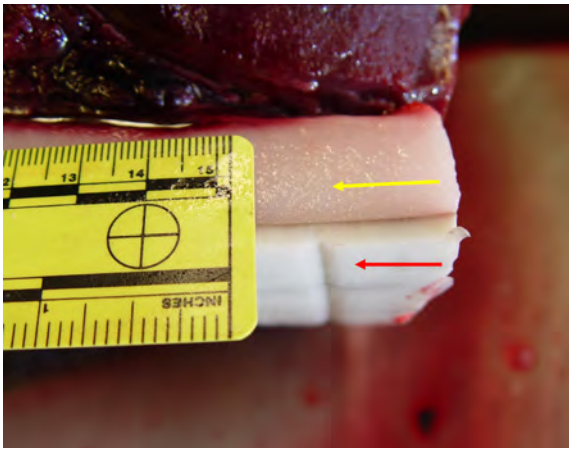

*This harbor porpoise (*Phocoena phocoena*; above left) was collected by a fisheries observer after being caught in a gill net. Note the circumferential impression around the head (red arrow). Upon necropsy, dissection of the line mark (red arrow, right) revealed NO underlying gross tissue reaction (yellow arrow, above right) illustrating the result of premortem injury in a confirmed entanglement case where the porpoise died so quickly from forced submergence that the body did not have time to mount an inflammatory response (© Woods Hole Oceanographic Institution).*

5.3 Predation and Scavenger Damage

Predation and scavenger damage are common and can destroy, mask, or mimic evidence of HI. Sharks often feed on live animals and carcasses at sea. Carcasses, and sometimes live animals, stranded on beaches are also exposed to scavengers and predators of all types. The most destructive terrestrial scavengers are birds (gulls, vultures, some raptors) and mammals (coyotes, foxes, bears and others). Often animals are scavenged by a host of critters.

Learning to recognize evidence of scavenger and predation damage common in your area is important. Comparing exposed tissue to that which was buried or submerged can help determine what marks were caused by scavengers and predators and what marks were present before the stranding (such as HI lesions). There are often characteristics that are common to certain types of predation and scavenging:

- Birds tend to target the eyes in cetaceans and pinnipeds, and the mandible (lower jaw) in cetaceans, often before an animal has died
- Coyotes will partially skin a seal to expose muscle and fat, leaving bare bones
- Coyotes target the rear flanks, head, and throat if attacking a live animal (bite wounds are similar to HI lesions such as gaff wounds (look at the number of wounds and wound patterns)
- Foxes and raccoons will chew on the distal edges of fins and flippers

Terrestrial Predators and Scavengers

If an area is undisturbed when you approach the carcass, look for tracks in the substrate. Birds and mammals leave distinct tracks which will give you an idea of who/what has visited the carcass before you. Coyotes in the northeast, bears in Alaska, and other large, terrestrial predators will attack live animals stranded or hauled out on beaches.

*Harbor porpoise (*Phocoena phocoena*) dorsal peduncle scavenged by foxes and birds (left; © Virginia Aquarium).*

*Harbor seal (*Phoca vitulina*) from Cape Cod, Massachusetts scavenged by coyote (below; © IFAW Marine Mammal Rescue and Research).*

*Harbor seal (*Phoca vitulina*) with coyote damage to head (above © IFAW Marine Mammal Rescue and Research).*

Examples of damage from terrestrial predators and scavengers

*Scene from a predatory event between a harp seal (*Phoca groenlandica*) and a coyote (above, left). Note the bloody trail in the upper portion of the image; this is where the coyote dragged the animal up the beach. Note the paw prints in the forefront of the scene (© IFAW Marine Mammal Rescue and Research)The damage done to the carcass can be substantial (above, right). In this case, the skull was exposed and crushed, and skin, fat, and muscle were torn from the thorax (© IFAW Marine Mammal Rescue and Research). Also note the gull tracks in the sand indicating post mortem scavenging.*

*Gull scavenging presents as small linear marks usually on the head and flat surfaces of the body. If there is an existing wound and/or the body cavity is open, scavenging raptors such as vultures and eagles may completely remove internal organs. On this harbor porpoise (*Phocoena phocoena; above right*), scavenging birds targeted the eyes and jaw fat. This lesion pattern is typical of bird scavenging, but can be mistaken by inexperienced observers as a gunshot lesion (© Virginia Aquarium). In Cape Cod, MA birds may "scavenge" live stranded animals. In fact, bird damage to the eyes and blowhole is a common reason for euthanasia in mass stranded dolphins.*

Marine Predators and Scavengers

Shark attacks on live animals and scavenging of dead animals are both common occurrences. It can be challenging to determine whether shark damage was antemortem, premortem, or postmortem, so we group both together as predation and scavenging. Other marine scavengers (amphipods, crabs, *etc*.) tend to leave marks similar to terrestrial scavengers.

While there are other marine scavengers, sharks pose the most significant hindrance to HI evaluation because of the size of the wounds they create and the amount of tissue they remove. The location of shark lesions can be indicative of whether lesions were pre- or post-mortem. When attacking live prey, sharks tend to target the genital area, approaching from below and behind their prey. When scavenging a dead animal, sharks will target any exposed area and may concentrate on areas surrounding existing wounds. For example, bloated carcasses generally float belly-up, resulting in shark bites on the dorsal surface. An area that has a lesion, especially if there are open wounds, is often the target of attack. Look carefully around bite wounds for evidence of other underlying lesions (especially propeller cuts). Learn to recognize shark 'tastes' (tooth marks without a bite/removal of tissue) and shark tooth rakes and distinguish them from line marks.

Examples of damage from marine predators and scavengers

*Bottlenose dolphin (*Tursiops truncatus*) stranded in Virginia with a shark bite and missing flukes (left). Compare the curved shape of the large bite wound to the straight line of the severed peduncle. It is unlikely, but not impossible that a shark would sever the flukes. Even a large shark would leave a slightly curved lesion as opposed to the straight lesion seen here. This carcass was scored as YES for APPENDAGES REMOVED because the lesion was indicative of the flukes being cut off instead of bitten (© Virginia Aquarium).*

*Neonate or stillborn bottlenose dolphin (*Tursiops truncatus*) with shark bite to the peduncle (© Virginia Aquarium).*

*Bottlenose dolphin (*Tursiops truncatus*) with shark bites. The ventral orientation of the bites may indicate ante- or premortem attack (© Virginia Aquarium).*

5.4 Decomposition

When examining a degraded carcass, there is very little you can do to salvage all but the most obvious external HI lesions. If, however, a carcass is sunburned on one side, it may be relatively intact on the other. Protecting the 'good' side from the sun until examination can help you with evaluation. If you are transporting a sunburned carcass, make sure to leave it burned side up in the transport vehicle. Badly decomposed, desiccated, or sunburned carcasses should rarely receive a score of NO for Signs of HI because it is unlikely that anyone could detect HI lesions in the face of decomposition. When carcasses such as these have clear signs of HI it is often challenging to make a subjective final determination other than 0 (CBD).

Cetaceans degrade very quickly externally when skin is exposed to sun, wind, and heat. When floating or submerged, the carcass loses its epidermis revealing the white blubber or hypodermis. In both cetaceans and pinnipeds, peeling, sloughing, and/or sunburned skin obscures marks, as does freezing and desiccation. As animals decompose, appendages degrade, the body cavity opens, and evaluation becomes even more difficult. If you cannot examine a carcass immediately, cover it with a wet towel or put it in the shade. If you must freeze a carcass before examining, place it in a tightly wrapped plastic bag to reduce freezer burn. It is important to note that the freezing process itself can create marks that mimic HI to the inexperienced observer. Freezer burns or desiccation can cause skin to crack creating lines not unlike lacerations from twine or net. However, these freezer artifacts are often found on the flat surfaces of the body (remember that net and line marks are most often found on the leading edges and around appendages and the head). Often the freezer marks affect an appendage, but rarely cross over the leading edge from dorsal to ventral surface. These freezer marks are also more jagged in appearance. Additionally, the bag in which the carcass is frozen may leave linear impressions on the carcass. Whenever possible, it is best to complete the HI exam before freezing.

Examples of damage from decomposition

*Decomposed (code 4) harbor porpoise (*Phocoena phocoena*) missing head, appendages and most of the skin (right; © Virginia Aquarium).*

*Decomposed (late code 3) bottlenose dolphin (*Tursiops truncatus*) with desiccated and peeling skin and rendering blubber (left; © Virginia Aquarium).*

*Ventral view of a badly decomposed (late code 3) harbor seal (*Phoca vitulina*) that had been frozen and thawed (left; © IFAW Marine Mammal Rescue and Research).*

When a carcass pours out of a bag (right) (frozen and thawed) there is very little you can do in the form of an HI exam (or any exam for that matter). With any type of HI, decomposition obscures lesions and causes carcasses to bloat, then deflate, making evaluation difficult (© IFAW Marine Mammal Rescue and Research).

*A code 4 or 5 carcass, like that of this humpback whale (*Megaptera novaeanglae*) (left) may exhibit broken bones or missing appendages, but the cause is as likely due to decomposition as to HI. Generally, unless gear or debris are attached or ingested, very decomposed stranded marine mammals should be scored CBD (© Virginia Aquarium).*

Evaluating a Decomposed Carcass

Left oblique view of a code 3 white-sided dolphin *(Lagenorhynchus acutus)* showing degradation of the skin *(above)*. Note the peeling skin on the dorsal thorax and condition of the dorsal fin. This is an example of the other end of the code 3 spectrum from the first case study.

EXTERNAL EXAM: Although there was some bloating, we felt that we could confidently say the carcass was not emaciated because of the fully rounded epaxial musculature. As seen from the image, there was a considerable amount of skin loss, especially on the right side. The dorsal fin and flippers were degraded and/or scavenged. Since they were present, although degraded, we scored the appendages as NO for mutilation (appendages removed/mutilation).

Despite its condition, the body was intact and was scored as NO for body sliced/mutilation. There was no gear or debris on the body. It was difficult to assess the body for other pathologies and HI lesions so we scored CBD in both of these fields.

INTERNAL EXAM: There were whole squid and whole fish in the fore-stomach. Both lungs were fluid filled, heavy and sopping. There was no other obvious pathology.

HISTORY: This was one of many offshore delphinids that stranded in the area in spring of 2004 during an Unusual Mortality Event (UME). Most carcasses were decomposed. Those that had stomachs had recently eaten squid. HI was suspected, but no evidence was obtained.

Findings of HI = CBD

Although you may not be able to objectively say there were signs of HI, if you feel that there was something other than natural death involved, it never hurts to write down your thoughts in a necropsy report or on the HI form. You may revisit the case in the future with new knowledge. Despite several observations consistent with fishery interaction (full stomach, robust body condition, fluid in lungs) there were no definitive HI marks.

6.0 Necropsy and Sampling

Most stranding response organizations have a system for examining those animals that wash ashore dead, die, or are humanely euthanized. A human interaction evaluation on a carcass is not complete until a full necropsy has been conducted (obviously, this is not the case for live stranded animals). The internal examination is an important part of the overall process because it can provide insights into the overall health of the individual and may also yield further evidence of human interaction. The HI data sheet guides the examiner to note particular internal findings that are consistent with human interaction. For example, debris or gear found in the gastrointestinal tract is a form of HI (debris/gear ingestion). Froth in the lungs and bronchi is indicative of an agonal death and may help support or refute external findings (froth in the lungs can be caused by euthanasia in some cases, but may alternatively indicate a struggle at the time of death such as struggling due to entanglement in fishing gear). As stated previously, a full stomach paired with net or line marks, *supports* a finding of fishery interaction. Remember that there are some internal findings that are considered *consistent with, but not indicative of* fishery interaction. These findings can be used to support other evidence, but cannot stand alone as evidence of fishery interaction (See 4.1 Fishery Interaction). Bruising and sub-dermal staining consistent with hemorrhage may reveal blunt trauma that was not evident externally. These are just a few examples of the many types of evidence that may be found internally. Thus, whenever possible, a full internal exam (necropsy) should be done.

Standardized protocol

As with the external exam, it is important to develop a standard routine when conducting a necropsy. Taking apart the animal and sampling it in the same order each time will help to minimize mistakes. Although a necropsy protocol is not included as part of the Human Interaction Evaluation protocol, the HI data sheet does prompt the examiner to describe key internal elements that may show signs of HI. Several necropsy manuals exist for reference, such as Pugliares *et. al.* 2007. Be sure to reference your necropsy report in the comments section of the HI data sheet.

Necropsy report

The Necropsy Report Form is an important part of the documentation process. Most institutions have developed their own data sheet to meet their needs (example at right). Many institutions will readily

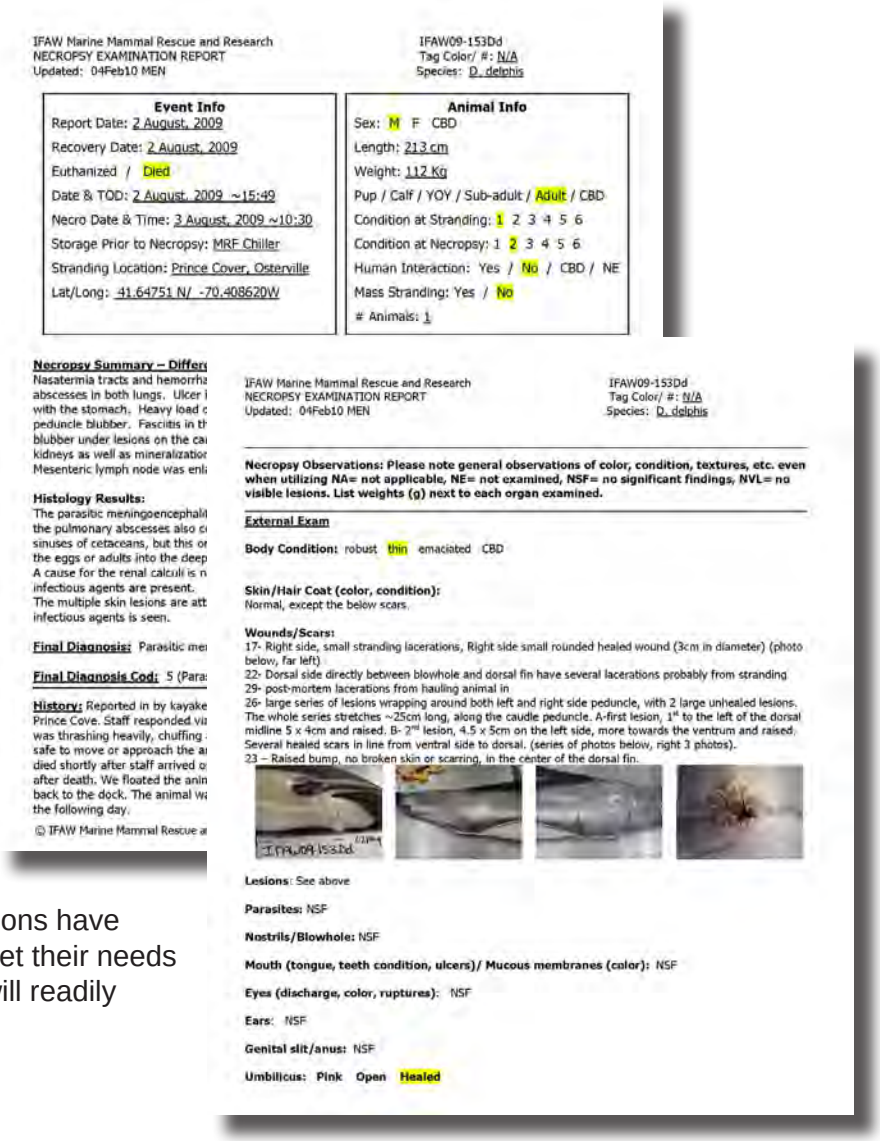

IFAW Marine Mammal Rescue and Research
NECROPSY EXAMINATION REPORT
Updated: 04Feb10 MEN

IFAW09-153Dd
Tag Color/ #: N/A
Species: D. delphis

Event Info
Report Date: 2 August, 2009
Recovery Date: 2 August, 2009
Euthanized / Died
Date & TOD: 2 August, 2009 ~15:49
Necro Date & Time: 3 August, 2009 ~10:30
Storage Prior to Necropsy: MRF Chiller
Stranding Location: Prince Cover, Osterville
Lat/Long: 41.64751 N/ -70.408620W

Animal Info
Sex: M F CBD
Length: 213 cm
Weight: 112 Kg
Pup / Calf / YOY / Sub-adult / Adult / CBD
Condition at Stranding: 1 2 3 4 5 6
Condition at Necropsy: 1 2 3 4 5 6
Human Interaction: Yes / No / CBD / NE
Mass Stranding: Yes / No
Animals: 1

Necropsy Summary – Differ
Nasatermia tracts and hemorrha
abscesses in both lungs. Ulcer i
with the stomach. Heavy load c
peduncle blubber. Fasciitis in th
blubber under lesions on the ca
kidneys as well as mineralizatio
Mesenteric lymph node was enl

Histology Results:
The parasitic meningoencephali
the pulmonary abscesses also c
sinuses of cetaceans, but this o
the eggs or adults into the deep
A cause for the renal calculi is n
infectious agents are present.
The multiple skin lesions are att
infectious agents is seen.

Final Diagnosis: Parasitic me

Final Diagnosis Cod: 5 (Para

History: Reported in by kayake
Prince Cove. Staff responded via
was thrashing heavily, chuffing
safe to move or approach the a
died shortly after staff arrived o
after death. We floated the anim
back to the dock. The animal wa
the following day.

© IFAW Marine Mammal Rescue a

IFAW Marine Mammal Rescue and Research
NECROPSY EXAMINATION REPORT
Updated: 04Feb10 MEN

IFAW09-153Dd
Tag Color/ #: N/A
Species: D. delphis

Necropsy Observations: Please note general observations of color, condition, textures, etc. even when utilizing NA= not applicable, NE= not examined, NSF= no significant findings, NVL= no visible lesions. List weights (g) next to each organ examined.

External Exam

Body Condition: robust thin emaciated CBD

Skin/Hair Coat (color, condition):
Normal, except the below scars.

Wounds/Scars:
17- Right side, small stranding lacerations, Right side small rounded healed wound (3cm in diameter) (photo below, far left)
22- Dorsal side directly between blowhole and dorsal fin have several lacerations probably from stranding
29- post-mortem lacerations from hauling animal in
26- large series of lesions wrapping around both left and right side peduncle, with 2 large unhealed lesions. The whole series stretches ~25cm long, along the caudle peduncle. A-first lesion, 1st to the left of the dorsal midline 5 x 4cm and raised. B- 2nd lesion, 4.5 x 5cm on the left side, more towards the ventrum and raised. Several healed scars in line from ventral side to dorsal. (series of photos below, right 3 photos).
23 – Raised bump, no broken skin or scarring, in the center of the dorsal fin.

Lesions: See above

Parasites: NSF

Nostrils/Blowhole: NSF

Mouth (tongue, teeth condition, ulcers)/ Mucous membranes (color): NSF

Eyes (discharge, color, ruptures): NSF

Ears: NSF

Genital slit/anus: NSF

Umbilicus: Pink Open Healed

share their form for use by other stranding responders. If you do not currently have a necropsy form, contact other networks for examples and either adopt one of the forms for your institution, or craft an original to best suit your needs. A good Necropsy Report Form should capture basic data such as field number, stranding location, date of stranding, date of necropsy, storage prior to necropsy, and the name(s) of the prosector(s). Every Necropsy Report should include a brief stranding history and a summary external exam. The internal exam is often recorded by organ system or individual organ. Examiners should provide as much objective information as possible regarding their gross observations. Note the internal condition of the animal, including the appearance of the organs, color, texture, size, and any abnormalities. Also describe in detail any lesions, tumors, abscesses, sub-dermal staining/hemorrhage, *etc*. Inserting digital images into the report is very useful for pathologists and others reviewing the case or examining any samples. Examples of Necropsy Report Forms are included in the appendices of Geraci and Lounsbury (2005).

In order to provide as much information as possible to pathologists, stranding organizations should submit a Necropsy Report with any samples disseminated for histopathology. Your notes and pictures may provide critical insights into their microscopic observations, increasing their ability to accurately interpret their findings and determine cause of death and other valuable information.

Suggested sampling

In addition to recording your gross observations, sample collection is an important element in the Human Interaction Evaluation process. The confirmation of the SUBJECTIVE evaluation may lie in the analysis of HI samples. Determining whether an injury has occurred ante-, pre-, or postmortem will aid in confirming your final diagnosis. In addition to collecting standard samples (genetics, life history, contaminants, histopathology, biotoxicology, virology, microbiology, *etc*.), be sure to sample wounds or other evidence of human interaction. Whenever possible, HI lesions should be sampled for histopathology. Collect HI samples in the same manner as standard histopathology samples. Be sure to capture normal tissue on either side of the lesion and sample past the full depth of the lesion (if possible). A list of standard tissues sampled during necropsy is included in the appendices of Geraci and Lounsbury (2005) and an example of a sample collection form is to the right.

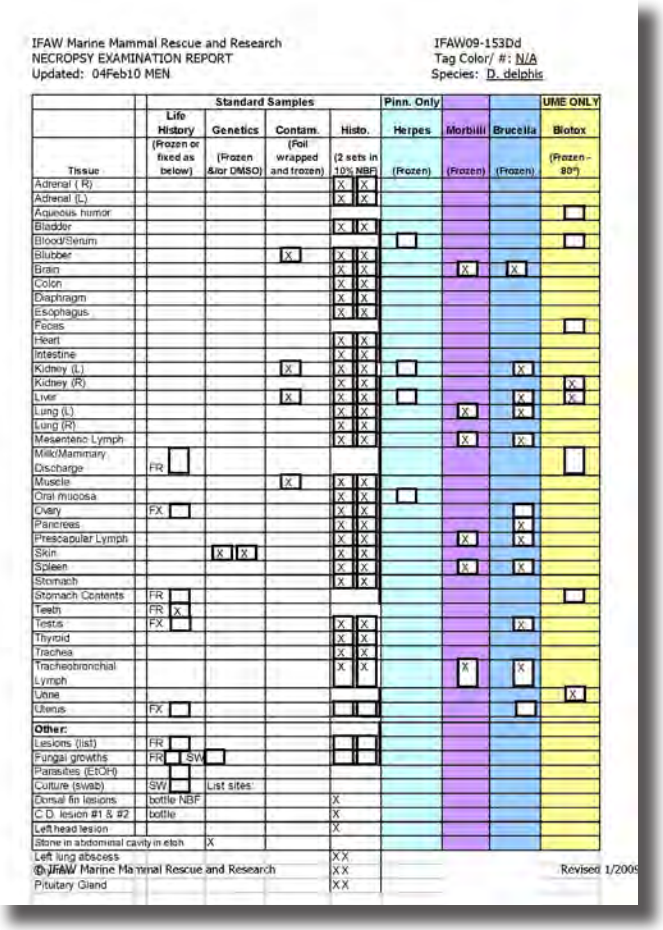

IFAW Marine Mammal Rescue and Research
NECROPSY EXAMINATION REPORT
Updated: 04Feb10 MEN

IFAW09-153Dd
Tag Color/ #: N/A
Species: D. delphis

		Standard Samples				Pinn. Only			UME ONLY
		Life History	Genetics	Contam.	Histo.	Herpes	Morbilli	Brucella	Biotox
Tissue		(Frozen or fixed as below)	(Frozen &/or DMSO)	(Foil wrapped and frozen)	(2 sets in 10% NBF)	(Frozen)	(Frozen)	(Frozen)	(Frozen -80°)
Adrenal (R)					X X				
Adrenal (L)					X X				
Aqueous humor									☐
Bladder					X X				
Blood/Serum						☐			☐
Blubber				X	X X				
Brain					X X		X	X	
Colon					X X				
Diaphragm					X X				
Esophagus					X X				
Feces									☐
Heart					X X				
Intestine					X X				
Kidney (L)				X	X X	☐		X	
Kidney (R)					X X				X
Liver				X	X X	☐		X	X
Lung (L)					X X		X	X	
Lung (R)					X X				
Mesenteric Lymph					X X		X	X	
Milk/Mammary Discharge	FR ☐								☐
Muscle				X	X X				
Oral mucosa					X X	☐			
Ovary	FX ☐				X X			☐	
Pancreas					X X			X	
Prescapular Lymph					X X		X	X	
Skin		X X			X X				
Spleen					X X		X	X	
Stomach					X X				
Stomach Contents	FR ☐								☐
Teeth	FR X								
Testis	FX ☐				X X			X	
Thyroid					X X				
Trachea					X X				
Tracheobronchial Lymph					X X		X	X	
Ulna									X
Uterus	FX ☐				☐ ☐			☐	
Other:									
Lesions (list)	FR ☐				☐ ☐				
Fungal growths	FR ☐ SW ☐				☐ ☐				
Parasites (EtOH)	☐								
Culture (swab)	SW ☐	List sites:							
Dorsal fin lesions	bottle NBF				X				
C.D. lesion #1 & #2	bottle				X				
Left head lesion					X				
Stone in abdominal cavity in etoh		X							
Left lung abscess					X X				
Right lung abscess					X X				
Pituitary Gland					X X				

© IFAW Marine Mammal Rescue and Research Revised 1/2009

7.0 Outreach and Education

The role of public sentiment in conservation and management

Marine mammals tend to generate a great deal of public interest. Stranding events are often the only time that members of the general public get to see these “charismatic megafauna” up-close and personal. Emotions can run high at stranding events, with bystanders wishing to help in the efforts to rescue live stranded animals or investigate the deaths of animals that do not survive. Often, there is a rush to find a cause and to lay blame for a death. Bystanders witnessing a mass stranding of dolphins may begin to ask if military actions or ocean noise caused the stranding. Others may suggest pollution as a culprit or fisheries interactions. The reality is that human interactions pose a difficult dilemma when dealing with the public. Strandings represent a wonderful opportunity to educate the public about marine mammals and the need for sound management and conservation to protect these species. However, it is unwise to cast blame while investigating a stranding. It is important that your conservative approach to evaluating the carcass be carried over into your interactions with the public. In some instances, HI cases may become law enforcement cases. It is inappropriate to discuss the details of an open case, thus, the best response in all instances is to explain that a thorough exam must be completed and the cause of the event is under investigation pending final results of analyses.

A staff member discusses the response taking place with local beachgoers (© IFAW Marine Mammal Rescue and Research).

Take care in speaking with bystanders and remember that a thorough exam is necessary before any conclusions can be made, including diagnostics for live animals and a full necropsy and sample analysis for dead animals. In these days of cell phone video, Facebook, and Twitter, casual remarks not meant for the public can easily become the next phenomenon on YouTube. Guard your comments carefully and understand that almost everything you say sounds bad when taken out of context. However, it is also ill-advised to ignore the obvious. If an animal is on the beach with net or other gear on it, or with obvious propellar wounds, acknowledge their presence, but reinforce the fact that one cannot determine the potential impact without further analysis (whether the interaction was ante- or postmortem, whether the interaction may have caused the stranding or death of the animal).

Being sensitive to other resource users

Resource use conflicts abound in the realm of natural resource management. Although lesions you observe may be due to fishery, vessel, or other human interactions, it is important to remember that the best likelihood of resolving these conflicts is through cooperative efforts. Alienating fishers will not help to reduce entanglements. Think very carefully before you publicly implicate an industry or group. Remember that, in many cases, commercial fishers have permits to legally take marine mammals. If you want cooperation in trying to solve a problem with HI, the worst way to go about it is to publicly accuse an individual or group, especially if you have

not yet conducted a thorough exam. Furthermore, stranding responders often rely on fishers and other marine resource users to report strandings and aid in response (providing access to injured or deceased animals offshore, *etc*.). Take care not to alienate these groups.

Literature Cited

Bexton, S., Thompson, D., Brownlow, A., Barley, J. Milne, R., and C. Bidwell. 2012. Unusual Mortality of Pinnipeds in the United Kingdom Associated with Helical (Corkscrew) Injuries of Anthropogenic Origin. Aquatic Mammals, 38(3), 229-240.

DiMaio, J.M. and S.E. Dana. 2007. Handbook of Forensic Pathology, Second Edition. CRC Press. New York, New York. 298p.

Dunn, D.G., Barco, S.G., Pabst, D.A., McLellan, W.A. 2002. Evidence for infanticide in bottlenose dolphins of the western North Atlantic. Journal of Wildlife Diseases 38:505-510.

Geraci, J.R. and V.J. Lounsbury. 2005. Marine Mammals Ashore: A field guide for strandings, Second Edition. National Aquarium in Baltimore, Baltimore, MD. 362p.

Lightsey, J.D., S.A. Rommel, A.M. Costidis and T.D. Pitchford. 2006. Gross necropsy diagnosis of watercraft-related mortality in the Florida manatee (*Trichechus manatus latirostris*). Journal of Zoo and Wildlife Medicine 37(3):262–275.

Merriam-Webster. MedlinePlus Medical Dictionary. http://www.merriam-webster.com/medlineplus. 2012.

Pugliares, K., Bogomolni, A., Touhey, K., Herzig, S., Harry, C., Moore, M. (2007). Marine Mammal Necropsy: An introductory guide for stranding responders and field biologists. Woods Hole Oceanographic Institution Technical Report. WHOI 2007-06. 133pp.

Rommel, S.A., A.M. Costidis, T.D. Pitchford1, J.D. Lightsey, R.H. Snyder, E.M. Haubold. 2007. Forensic methods for characterizing watercraft from watercraft-induced wounds on the Florida manatee (*Trichechus manatus latirostris*). Marine Mammal Science 23(1):110-132.

Appendix I:

Human Interaction Data Sheet and Instructions

Protocol for Examining Marine Mammals for Signs of Human Interaction

Exam Information *(fill in or circle most appropriate)*

1 Field #: _____ Species: _____

2 Examiner: _____ Recorder: _____

3 Date of exam: _____ Condition code (at exam): 1 2 3 4 5 CBD

4 Preservation: alive fresh frozen frozen/thawed Body condition: emaciated not emaciated CBD

5 Documentation: digital print slide video Image disposition: _____

6 Integument : normal abnormal decomposed % Skin missing: <10% 10-25% 25-50% >50%

7

Explanation of terms:
YES = I have examined the area and found signs of human interaction
NO = I have examined the area did not find signs of human interaction
CBD = I have examined the area and could not determine whether there were signs of human interaction (*i.e.* the part was missing, degraded, or signs were ambiguous)
NE = I did not examine the area
NA = this animal doesn't normally have that part (*i.e.* seals have no dorsal, dolphins have no rear flippers)

	WHOLE BODY EXAM	YES	NO	CBD	NE	NA	Image taken
8	Appendage(s) removed / Mutilation *(with instrument)*						
9	Pelt removed / Mutilation *(with instrument)*						
10	Body sliced / Mutilation *(with instrument)*						
11	Gear / Debris present on animal *(including tags)*						
12	Gear / Debris retained *(name & contact info in Comments)*						
13	External pathology *(pox, tattoo lesion, abscess)*						
14	Natural markings *(scars, tooth rakes, unusual pigmentation)*						
15	HI lesions *(fishery, gunshot, propeller, healed HI scar, brand)*						

16 Predation / scavenger damage *(circle all anatomical areas where damage hinders evaluation; numbers coincide with anatomical areas below)*: 17 18 19 20 21 22 23 24 25 26 27 28 29 NONE

FILL IN TABLE FOR **ALL POSSIBLE FINDINGS OF HI**
Do not use for natural markings/pathology.

						Type of Lesion					Origin of Lesion: Gear - Twine Type						Origin of Lesion: Other			
	DETAILED EXAM OF ANATOMICAL AREAS	YES	NO	CBD	NE/NA	Impression/ Laceration	Penetrating wound	Healed HI scar	Abrasion	Other / CBD	Twine / line	Net	other / CBD	Monofilament	Multifilament	CBD	Propeller	Gunshot	Other / CBD	Image taken?
17	Rostrum/snout																			
18	Mandible																			
19	Head																			
20	L Front appendage																			
21	R Front appendage																			
22	Body R L																			
23	Dorsum/dorsal fin																			
24	Ventrum																			
25	Peduncle																			
26	L Rear appendage																			
27	R Rear appendage																			
28	Flukes/tail																			
29																				

Field #:_____

	INTERNAL EXAM Date _____	YES	NO	Partial	CBD	Image taken	Detailed Info *(circle all that apply)*
30	Internal exam conducted						*Details in Comments section -use line number*
31	Bruising/blunt trauma						*Details in Comments section -use line number*
32	Skeleton examined						*Details in Comments section -use line number*
33	Broken bones present						*Associated tissue reaction: YES NO CBD*
34	Mouth/GI tract examined *(circle contents)*						*intact prey partially digested hard parts only* ***debris/gear*** *empty other*
35	Lungs/bronchi examined						*Details in Comments section -use line number*
36	Lung/bronchi contents						*froth fluid air* (color:)
37	Bullet/projectile found						*found using: CT X-ray dissection (collected? Y N)*
38	Other lesions noted						*Details in Comments section -use line number*

39 **Comments** (*note line number from left margin before each comment*):

40 **Findings of Human Interaction:** ☐YES ☐NO ☐CBD (Exam Type: external__ internal___ both ___)
(transfer to Level A Datasheet)

41 Type of HI: (provide details in comments)

☐ Entanglement (gear__ debris__ CBD__) ☐ Vessel trauma (sharp__ blunt__ both__)
☐ Hooking (recreational__ commercial__ CBD__) ☐ Gunshot ☐ Mutilation
☐ Ingestion (gear__ debris__ CBD__) ☐ Harassment ☐CBD/Other_____

42 **Stranding Event History/Circumstances:**

43 **INITIAL HUMAN INTERACTION EVALUATION:** If you marked YES above (line 40) evaluate the external exam, necropsy, carcass condition and circumstances surrounding the stranding event to answer the question below. *Remember to be conservative in your subjective evaluation*.

What is the likelihood that the finding of human interaction (line 40), contributed to the stranding event?

0: Uncertain (CBD) 1: Improbable 2: Suspect 3: Probable

44 **Justification:**

Final human interaction evaluation requires additional data from level B and C analyses as well as review by a veterinary pathologist.

PROTOCOL FOR EVALUATING MARINE MAMMALS FOR SIGNS OF HUMAN INTERACTION

Introduction

Evaluating marine mammals for signs of human interaction requires consistent, objective examination by trained personnel. This document is meant to accompany formal training by experienced stranding network participants. This protocol is divided into an objective data collection section and a more subjective initial human interaction diagnosis. The primary goal of this protocol is to determine whether evidence of human interaction is present on the animal. The secondary, and more difficult, goal is to determine whether human activities contributed to the stranding event. A positive score for Findings of Human Interaction results from an objective evaluation of an animal or carcass. This evaluation does not attempt to determine whether the signs of human interaction occurred before, during, or after a stranding event and does not attempt to qualify the severity of the interaction.

The subjective Initial Human Interaction Evaluation takes into account the circumstances of the stranding event and the animal's physical condition. A high score indicates that human activities most likely caused the stranding. A low score indicates that although signs of human interaction are present, the likelihood that the interaction caused the stranding is very low. For example, old, healed propeller scars on a known whale are unlikely to have caused a stranding during a domoic acid event and a dead dolphin calf covered by debris on a beach following a hurricane is unlikely to have died due to entanglement.

Determining the cause of death is not an objective of this protocol. Without further evaluation, such as histopathology, and review by veterinarians, pathologists and/or other experts, the exact reason for stranding and cause of death cannot be definitively determined.

Human interaction (HI) data illustrate where problems between marine mammals and humans occur. When collected carefully and consistently, these data can be used to describe the types of interaction taking place (*e.g.* monofilament net, multifilament net, small or large vessel interaction, ingestion of debris, *etc.*), thus providing a sound scientific basis for policy and management decisions. The nature of strandings makes it inadvisable to use human interaction data to estimate mortality or changes in the mortality rate due to human interaction.

In addition, there are categories of human interaction that are difficult, if not impossible, to evaluate such as strandings that result from persistent harassment, those that result in detrimental behaviors such as surfacing too quickly from a dive after exposure to sub-lethal sound, as well as long-term effects of man-made products that may result in lowered immunity, disease, or reduced reproduction. There are new activities such as renewable energy and aquaculture operations that are just beginning to be exploited in the US. We cannot point to a mark or a diagnostic test that can tell us whether a stranded whale has been exposed to active sonar or to sound generated by a wind farm. We cannot guarantee that a seal pup was never exposed to humans or their activities. Finally, we must acknowledge that we do not understand the effects of multiple human interaction stressors on marine mammals.

We must acknowledge that, in some way, human activities have affected the lives of every marine mammal, but for our purposes using this form, we are trying to document those human activities that are consistently observable and can be documented by stranding responders.

Definitions

In order to effectively evaluate marine mammals for signs of human interaction, you must understand what you are looking for. Below are terms and explanations of data sheet sections:

Document developed by IFAW MMRR and VAQS (2012) with funding from the John H. Prescott Grant Program

For most of the sections, you must choose among the following answers:

YES you have examined the area (*i.e*. left front appendage, snout) and you found signs of human interaction

NO you have examined the area (*i.e*. left front appendage, snout) and you found NO signs of human interaction

CBD (Could not Be Determined) which means either: (1) you have examined the area and could not determine whether the marks you saw were signs of human interaction, (2) you could not properly examine the area because it was degraded (scavenged, skin/pelt missing, mangled, *etc*.), or (3) you could not examine the area because it was missing (removed, decomposed)

NE you did not examine the area (an explanation as to why is often helpful – *e.g*. it was too dark; the animal was to large to roll over, *etc*.)

NA this question is not applicable to this animal (*e.g*. it is a seal and doesn't have a dorsal fin, or it is a dolphin and doesn't have rear appendages)

Strategy for filling out the human interaction data sheet

Each line on the data sheet is numbered in the left hand margin. These numbers serve two purposes: (1) each number corresponds to a section within these instructions with details about how to complete that line; (2) the line numbers should be entered in the comments section on the second page of the data sheet to indicate to which item the comment refers.

Page 1:

EXAM INFORMATION: Fill in or circle the most appropriate answer for each of the fields.

1 *Field #*: unique identifying number originally assigned to the animal by response personnel. Note: the field number NEVER changes. If other filing numbers are added or accession numbers from other institutions are added, they should be noted as "additional identifiers".
Species: note the genus and species or common name of the animal.

2 *Examiner*: the person evaluating the animal.
Recorder: the person recording the information on the data sheet.

3 *Date of exam*: the date that you are conducting the human interaction evaluation.
condition code (at exam): the condition code of the animal at the time of the human interaction evaluation. Use Smithsonian Institution condition codes (Geraci and Lounsbury 2005).

4 *Preservation*: circle one of following - ALIVE, FRESH (not previously frozen), FROZEN (completely or partially frozen while exam was conducted), or FROZEN/THAWED (previously frozen, but completely thawed before exam).
Body condition: circle one of following - EMACIATED (clearly thin, concave epaxial muscle, obvious neck, ribs, scapulae, hip bones, and/or vertebral processes), NOT EMACIATED (robust or slightly thin, but not fitting the description of emaciated above) or CBD could not be determined (bloated, decomposed, not examined, *etc*.).

5 *Documentation*: circle all forms of photo/video documentation that apply.
Image disposition: indicate which camera, disk, tape, *etc*. that images were taken or stored on and the acronym of the organization that is maintaining them.

6 *Integument*: (skin, fur, hide) circle one of following - NORMAL (as if it were healthy and alive), ABNORMAL (conditions not associated with decomposition such as: alopecia, skin lesions, sloughing, abrasions, *etc*.) or DECOMPOSED/SCAVENGED (post-mortem changes such as peeling, sunburn, or scavenger damage).
% Skin missing: Circle the most appropriate number. Note that this does not apply to alopecia (fur loss) but to SKIN loss.

7 *Explanation of terms*: definitions of common terms used throughout the data sheet.

WHOLE BODY EXAM: Before beginning a detailed exam, take a look at the whole animal. If possible, look at all angles and surfaces. Following your whole animal exam, check the most appropriate choice for each category. If you check YES or CBD, describe what you see in the *Comments* section on the

next page, noting the appropriate line number. Indicate whether you collected an image of an area with a Y (Yes) or N (No) in the *Image taken* section. If you are unable to examine any areas, note the details in the *Comments* section.

8 *Appendages removed* (*with instrument*): Check YES if the head or any appendages (limbs, dorsal fin, fluke, *etc*.) appear to have been removed from the animal with an instrument (*e.g.* if there are obvious straight line cuts or straight nicks to the bone). In the lower 48 states of the US, this would be consistent with mutilation. In other areas, such as AK, this may be evidence of the legal harvest of a marine mammal. It is essential to work with local communities and agencies to interpret your findings in these cases. Check NO if all appendages are intact. Check CBD if you are unsure why an appendage is missing or if you cannot examine all appendages. If it appears an appendage was completely removed by scavenging or predation (*e.g*. shark bite removed entire dorsal fin) you should check CBD.

9 *Pelt removed* (*with instrument*): Check YES if the pelt appears to have been removed with an instrument (knife, scraper). Check NO if the pelt is intact (even if the animal's skin is intact but the hair/fur is missing). Check CBD if you are unsure (due to decomposition, *etc*.) of whether the animal's pelt was removed. Again, removal of the pelt in most regions of the US would be considered mutilation; however, in areas where harvesting is permitted, care must be taken in interpreting and documenting the interaction. If legal harvest is suspected, contact your Regional Coordinator for guidance on documentation and reporting. Check NA if the animal has no pelt (cetacean or manatee).

10 *Body sliced* (*with instrument*): Check YES if the carcass appears to be sliced with one or more cuts (from a knife or other blade), consistent with either legal harvest or mutilation (as above, dependent on the region). Multiple parallel cuts are often indicative of propeller wounds and should be noted under the *HI Lesions* category. Check NO if the body is intact or open body cavity is obviously due to natural causes (*e.g.* scavenging, predation). Check CBD if the body cavity has been penetrated and you are unsure of the cause.

11 *Gear/debris present on animal:* Check YES if the animal is entangled in gear (net, line, pot, buoy, line with hook, *etc*.) or debris (anything else). Check NO if there is no gear/debris on the animal. Check CBD if you are unsure for any reason (*e.g*. gear/debris is found on, but not wrapped around the animal, or gear/debris was reported on the animal but apparently removed before you responded). Note *gear/debris present on animal* = YES if tags (roto, satellite, *etc*.) are present on the animal.

12 *Gear/debris retained:* Check YES if the gear was retained by a stranding network or NOAA enforcement official. Note the name and contact information if the gear was retained by anyone other than your organization. Check NO if the gear was not retained. Check NA if there was no gear/debris present on the animal.

13 *External pathology:* If the animal has any lesions that appear to be disease-related such as pox lesions, tattoo lesions, abscesses, or other unexplained lumps, bumps, or sores, check YES. Check NO if the animal has no disease-related lesions. Check CBD if you observe lesions and are unsure of their origin or if the integument is too degraded to assess.

14 *Natural markings:* If the animal has any natural markings (*e.g*. tooth rakes, unusual pigmentation, any non-HI scars) check YES. If the natural marks hamper your examination, please note in the COMMENTS section. If there are no natural markings, check NO. If you cannot tell if there are any marks or are unsure of the origin of marks/scars check CBD.

15 *HI lesions:* Note lesions that may be associated with human interaction (fresh or healed entanglement or propeller scars, gaff marks, gunshot, healed HI scars, brands, *etc*.). Check YES if any human interaction lesions are observed. Check NO if no other lesions are observed. Check CBD if you observe lesions and are unsure of their origin or if the integument is too degraded to assess. A detailed exam of these lesions will occur in the next section.

16 *Predation/scavenger damage:* If there is evidence of predation or scavenger damage, circle the number(s) that correspond to the anatomical areas where evidence is seen. If the area affected is not numbered, circle *#29*, and note the area in the table below (*e.g.* genital slit, umbilicus, tongue) and note details of the damage in *Comments.*

Document developed by IFAW MMRR and VAQS (2012) with funding from the John H. Prescott Grant Program

17-29 **DETAILED EXAM OF ANATOMICAL AREAS**– Use this table to record findings of all suspected or possible evidence of human interaction. This means that any mark that the observer believes is consistent with some type of HI should be noted here. In addition, any marks for which the source Could not Be Determined, but that do not appear natural, should also be recorded in this table. DO NOT RECORD INFORMATION ON NATURAL MARKINGS OR OTHER LESIONS IN THIS SPACE. Examine the animal carefully starting at the head and working caudally down the right, then left, side, finishing with the tail or flukes. For this section, indicate whether you observe any SIGNS OF HUMAN INTERACTION in each *anatomical area* by checking the YES, NO, or CBD column. If you were not able to examine an area, check NE, or if it does not apply to your animal, check NA. Be consistent; examine anatomical areas in the same order each time you do an exam.

TYPE OF LESION- If you checked YES or CBD in any area, proceed to the *Type of Lesion* section and check all columns that apply.

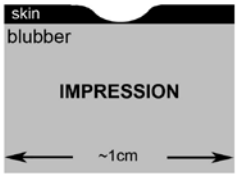

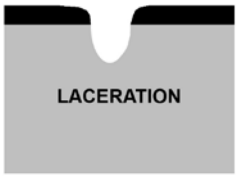

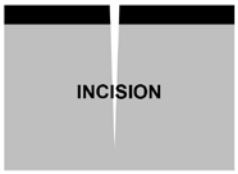

- An *IMPRESSION* is a compression wound that occurs when an object leaves an indentation but does not lacerate or abrade the skin/pelt. Impressions left by net or line usually wrap around the leading and/or trailing edges of a fin, flipper, or fluke. Impressions on the leading edge of an appendage may line up with a similar mark on the trailing edge.
- A *LACERATION* occurs when the skin/pelt is penetrated from tight constriction or prolonged compression. The skin tears resulting in a lesion. Net and line usually leave linear lacerations. These lacerations may be evenly spaced along an appendage, or bunched near the proximal end of appendages (indicating net) and may be accompanied by impressions. A laceration is different from an incision which is made by a sharp instrument such as a knife. In cross section, a laceration or impression has rounded or jagged edges indicating surface tissue damage.
- An *INCISION* has clean edges and results in little surface tissue damage (see image at right).
- A *PENETRATING WOUND* occurs when a foreign object punctures or deeply penetrates the body, and is generally characterized by a small external wound and a wound tract that extends deep into the tissue and often into the body cavity. Sources of penetrating wounds include gaff, knife stab, spear, arrow, gunshot (especially bullet), *etc.*
- A *HEALED HI SCAR* is similar to a natural scar in pigmentation, but exhibits similar characteristics to the other types of lesions described here (*e.g.* linear scars on leading edges of appendages consistent with entanglement, parallel scars consistent with prop strike, *etc.*). **Only check this column if the lesion is completely healed with no open tissue**. Healed scars may be pigmented and may feel different than surrounding tissue, but there should be no exposed flesh, discharge, or soft swelling if the wound is healed. Treat healing lesions the same as fresh lesions. Evidence of HI, even if healed and not likely associated with the stranding event, should still be scored positive (YES) for HI. It can be difficult to determine the origin of healed scars. If you are unsure of the origin, check CBD instead of YES in the first set of columns.
- An *ABRASION* occurs when gear or debris rubs an area and scrapes the skin/pelt without forming an obvious laceration or distinct impression. This often occurs with heavy line or twine entanglement or when loose or trailing ends of gear/debris rub (abrade) parts of the body.
- Choose *OTHER / CBD* for any other types of lesions and describe in the comments section.

Document developed by IFAW MMRR and VAQS (2012) with funding from the John H. Prescott Grant Program

ORIGIN OF LESION - Once you determine the type of lesion, move to the *Origin of Lesion* section and check all that apply.

LINE is made up of many individual strands (multifilament) and is large in diameter. It is used for moorings, towing, forms the float and lead line of nets, and attaches buoys and anchors.
TWINE is a small diameter line and can be multi- or mono- filament. Twine is constructed of various materials and is combined in different ways:

MONOFILAMENT twine – a single strand of nylon twine that leaves a single, straight, narrow impression or laceration (Figure 1, A).

MULTIFILAMENT – line or twine made up of multiple strands of material that are twisted or braided together and can leave a distinctive impression as a series of parallel, angled lines or ovals (Figure 1, B and C). If heavier twisted or braided line rubs on a body part or becomes tightly wrapped, it can cause an abrasion.

NET – nets can be made of either monofilament or multifilament twine and have various characteristics: twine diameter, square mesh size (knot to knot), and stretch mesh size (diagonal between opposite knots of a mesh with one knot between; Figure 2). Net impressions are often characterized by either a criss-cross pattern or a bunching of impressions with or without knot marks evident where lines intersect.

There are two parts to this section. First, we ask you to indicate what created the lesion, and if the lesion was related to gear, such as net, twine, or line. Second, we ask if you can determine whether the gear was monofilament or multifilament.
Based on the descriptions above, indicate the origin of the lesion:

- *Twine/Line* - select TWINE/LINE if the impression, laceration, or abrasion is consistent with the descriptions above, but is not indicative of interaction with a net.
- *Net* - select NET if the marks are consistent with the descriptions above. Nets made of monofilament may leave multiple impressions or lacerations, but each lesion is a straight furrow.
- *Other/CBD* - select this column if the marks appear consistent with entanglement or interaction with some type of gear, but you cannot determine which type.

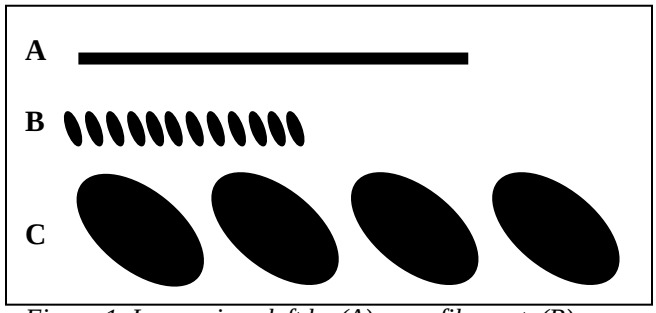

Figure 1. Impressions left by (A) monofilament, (B) twisted twine and (C) twisted line. Impressions are most visible on cetaceans.

If you checked *Twine/Line*, *Net, or Other/CBD,* indicate whether lesions were caused by *monofilament* or *multifilament* gear. Select *CBD* if you observe linear marks, but you are unsure of the origin.

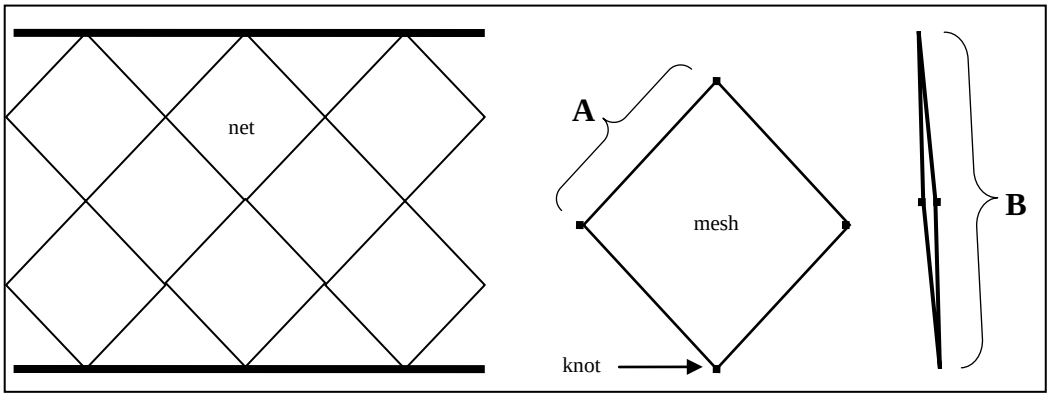

Figure 2. Typical net design. Nets are measured by the depth and length of the meshes hung between the top and bottom lines (float line and lead line on gill nets) and the horizontal length of the meshes. The mesh size can be measured from knot to knot (A) which is called the square *or* bar *mesh size or (B) at it's maximum diagonal width which is called a* stretch *mesh size.* Twine *size is the diameter of the twine the makes up the mesh.*

If the lesion you noted was not made by gear (line, net/twine), check the appropriate box to indicate the source:

- *Propellers* usually leave deep, roughly parallel lacerations (Figure 3). Lesions can be straight (A), Z or S-shaped (B), curved (C), or open in the middle with thin trails (not illustrated). Large propellers may bisect an animal.

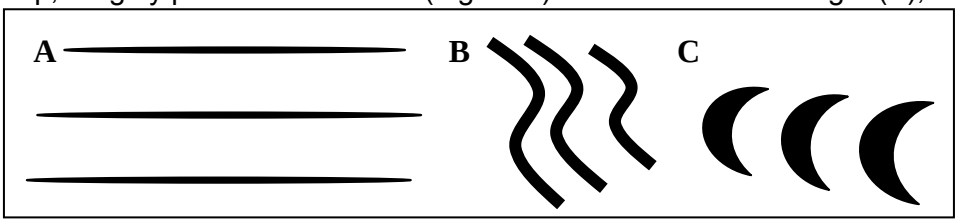

Figure 3. Types of propeller lesions left by different styles and sizes of propeller. The length, depth, and spacing between lesions can provide information as to the type of propeller and, thus, type of vessel.

- *Gunshot* wounds vary based on the weapon used (shotgun, rifle, hand gun) and the distance an animal is from the weapon. Gunshot wounds can be very difficult to identify through gross exam, but can be characterized by single (bullet) or multiple (pellet) puncture/penetrating wounds. Radiographs are often necessary to confirm the findings.
- *Other/CBD* - select this column for lesions with other origins including, gaff, arrow, and debris entanglement, *etc*. or if you are unsure of the origin of the lesion(s).

Every area that scores YES or CBD should have an IMAGE TAKEN that includes a label with identifying information (field number, date of stranding, species, examiner, subject of image, *etc*.) and a scale (small ruler or something of known size). If film or disk space is not limited, take pictures of all areas. Note Y (Yes) or N (No) in the IMAGE TAKEN column.

Every area that scores YES or CBD should have a comment associated with it. Number each COMMENT with the corresponding line number for that anatomical area.

If you find lesions in an area not listed in the Detailed Exam table, add it on line 29 and reference in the COMMENTS section.

Page 2:
FIELD # - Be sure to fill out the field number on both sides of all pages associated with this animal.

INTERNAL EXAM - An evaluation of a dead animal is not complete without a thorough necropsy (internal examination). Some forms of interaction are only evident through internal exam (*e.g.* ingestion of debris or gear) and a final interpretation may change if an animal with external evidence of HI is found to be suffering from disease, pregnancy complications, injuries, *etc*. Some observations support a diagnosis of HI (*e.g.* for fishery interactions - full stomach, froth in lungs) and others provide evidence for HI although nothing was noted externally (*e.g.* stomach full of man-made debris). Be sure to note the DATE of the internal exam in the INTERNAL EXAM box.

30 *Internal examination conducted* – If you were able to examine the entire animal, check YES. If you did not examine the animal internally, check NO. Check PARTIAL if you only examined part of the animal (*e.g.* abdominal cavity only), then describe in the *Comments* section what was examined.

31 *Bruising/blunt trauma* – Indicate if you see any focal area of bruising (discrete area, not diffuse along an entire body region). Note whether the area is associated with an external lesion. If it is not associated with a penetrating lesion or wound, it should be considered blunt trauma. If you check YES or CBD, note the size of the area and the tissue depth (*e.g*. sub-dermal to blubber, into muscle, through muscle and into mesenteries and organs) in the *Comments* section (do not confuse diffuse post-mortem blood pooling with bruising).

32 *Skeleton examined* – Check YES if the entire skeleton was examined. Check NO if no bones were examined. Check PARTIAL if only some of the skeletal elements were examined. If you check

PARTIAL, note in *Comments* section what was examined (*e.g.* examined skull, head, left ribs, and flipper, but not right side or vertebral column).

33 *Broken bones present* - Note whether you observed any broken bones.
Associated tissue reaction - Examine the tissue around the break(s) and circle whether any tissue reaction has occurred (hemorrhage, fibrous tissue, swelling at bone ends, *etc*.). If you are unsure, check CBD.

34 *Mouth/GI tract examined* - Check YES if the entire GI tract was examined. Check NO if none of the GI tract was examined. Check PARTIAL if only some elements of the GI tract were examined and note which areas were examined in the *Comments* section (*e.g*. stomach, but not intestines). Note in the *Detailed Info* column the predominant condition of the contents. Circle *debris/*gear if non-prey items (plastic, line, hooks, *etc.*) are found. Use the comments section to describe the region of the GI tract (*e.g.* esophagus, stomach chamber, intestine, or colon) and its contents (*e.g*. fish, squid, crabs, mussels, milk, plastic bag, unknown). Stranded animals with full stomachs are often suspect cases. Ingestion of gear or debris is considered a human interaction.

35 *Lungs/bronchi examined* - Check YES if both lungs were thoroughly examined. Check NO if the lungs were not examined. Check PARTIAL if you performed a partial examination and record in *Comments* section.

36 *Lungs/bronchi contents* - Circle all that apply in the *Detailed Info* column and describe the contents of each lung, including content volume, in the *Comments* section.

37 *Bullet/projectile found* – Check YES if you discovered any type of projectile (*e.g.* bullets, pellets, arrow heads, *etc*.) during the internal exam. Check NO if no projectiles were found. Check CBD if you are unsure of an object you have found. Indicate how the item was discovered in the *Detailed Info* section (CT scan, X-Ray, dissection) and indicate whether the object was collected. Note: it is important to follow Chain of Custody procedures when collecting this evidence. Provide details in the *Comments* section.

38 *Other lesions noted* - Note whether any other pathologies were observed, describe in *Comments* section.

39 **COMMENTS** – The details of what you observe are required in the section. Provide comments for each item for which you checked YES or CBD. When describing lesions, include measurements (*e.g*. length, width and depth, distance between lesions), location (*e.g.* measurement from nearest landmark – 20cm caudal of the right flipper), color, shape, and texture. Note the characteristics of the edges (*e.g.* jagged, straight, rounded) and the direction of linear lesions (*e.g*. wraps from leading edge of dorsal fin to trailing edge on left side). Number each set of comments using the corresponding line number for that row on the data sheet. Use extra pages if needed and be sure to note the animal's field number in the upper right margin. If this information is provided in the necropsy report or other data sheet, reference that material here.

40 **FINDINGS OF HUMAN INTERACTION** – Review your exam notes and check YES if you observed any signs of human interaction on the animal. Check NO if you thoroughly examined the animal and did not find any signs of human interaction. Check CBD if: (1) you did not examine the animal thoroughly, (2) decomposition or scavenger damage hampered the exam, or (3) you are unsure whether marks on the animal were caused by human interaction. This is an objective analysis. It does not take into account the animal's physical condition, the timing of the human interaction with respect to the stranding, or the circumstances surrounding the stranding. After determining the objective Findings of HI, select the EXAM TYPE you conducted. If you ONLY conducted an external exam, check EXTERNAL. If you conducted only an internal exam, check INTERNAL (although we are not sure when this would ever be the case, it is currently on the NOAA Level A form). If you conducted both external and internal exams, check BOTH. Note, even an external exam that is scored CBD due to decomposition or other factors is still considered an exam. In some cases, there may be a finding of CBD during the external exam, but YES during an internal exam (*e.g.* if the carcass lacked skin or pelt due to decomposition but the animal had ingested plastic).

Document developed by IFAW MMRR and VAQS (2012) with funding from the John H. Prescott Grant Program

TRANSFER THE ABOVE INFORMATION TO THE FINDINGS OF HUMAN INTERACTION SECTION ON THE LEVEL A DATA SHEET.

41 **Type of HI** - If you circle YES in line 40, indicate to the type(s) of human interaction that you observed.

Entanglement - occurs when there are lesions (such as linear impressions, lacerations, or circumferential lesions), or material on the animal consistent with entanglement.

- Choose *gear* as the type of entanglement if the lesions and/or gear removed strongly suggest fishing gear. Note that you cannot make assumptions about whether gear was actively fished, discarded, or 'ghost gear.' All should be checked as *gear*. Likewise, line alone, while used in fishing operations, is also used for many other applications and cannot be assumed to be fishing *gear* unless it has specific markings or attachments indicating it was used in a fishery. Examples of the latter include buoys, lead core line, and pots. Line of unknown origin should be marked as *CBD*, line obviously used for anchoring, mooring, or towing should be considered *debris*.
- Choose *debris* if the entangling material is not related to fishing gear. This includes material such as plastic bags or sheets, textiles such as clothing, rubber or latex, and metal. Line of unknown origin should be marked as *CBD*, and line obviously used for anchoring, mooring, or towing is considered *debris*.
- Choose *CBD* if you are unsure of the origin of the entangling material.

Hooking – occurs when a fishing hook (or lure) is imbedded on the body or in the mouth of an animal. If the hook or lure is in the throat or GI tract, it should be considered *ingested* gear.

- Choose *recreational* if the hook or lure is of a size or design that indicates it is strictly recreational gear (local tackle shops are often helpful for this).
- Choose *commercial* if the hook or gear is of a size or type, or is configured in such a way (such as a longline gangion) that indicates it is strictly commercial gear.
- Choose *CBD* if you cannot determine the origin of the gear or if it is used in both commercial and recreational fisheries.

Ingestion – occurs when an animal ingests a foreign object. Ingestion occurs if the object travels past the mouth and into the throat. If the object is a hook or lure, and it is in the mouth, the HI is *hooking*. If the object is line, twine or debris and it is tangled in mouth it is *entanglement*. Gear or debris must be ingested to fit this category.

- Choose *gear* if fishing gear such as a hook, lure, fishing twine, or net was ingested.
- Choose *debris* if plastic, metal, or other man-made debris was ingested.
- Choose *CBD* if you cannot determine the origin of the ingesta, but it is clearly man-made.

Gunshot - occurs when an animal is shot with a gun (handgun, shotgun, or rifle). Presence of one or more ballistic projectiles is the best way to diagnose a gunshot interaction. Wounds from other projectiles should be categorized under *CBD/Other*.

Vessel trauma - occurs when an animal is impacted by a vessel, usually through impact with the hull or propulsion system. The trauma can be 'sharp' trauma, such as that from a propeller, or 'blunt' trauma such as that from the bow of a ship, or a combination of the two.

- Choose *sharp* trauma if the external injury appears to be one or more roughly linear wounds with internal tissue damage associated with the chop or slice wounds.
- Choose *blunt* trauma if wounds, particularly broken bones and soft tissue damage, are more internal than external and are consistent with impact from a large object such as a vessel.
- Choose *both* if the wounds appear to be a combination of sharp and blunt trauma.

Mutilation – occurs when an animal or carcass is intentionally cut or sliced. Mutilation generally involves the use of some type of knife or blade and can result in several common types of wounds and amputations including body sliced, stabbed, or gutted or appendages removed.

Harassment – occurs when human activity changes the behavior of an animal. In this context, harassment occurs if the animal is harassed while it is in the process of stranding, is already stranded, or if the harassment results in a stranding. It is important to note that harassment is

common especially with hauled out pinnipeds and that not all harassment is associated with a stranding (*e.g.* feeding free-swimming animals is a form of HI, but not a stranding).
CBD/Other – occurs EITHER when non-natural lesions are on the animal, but it is unclear what type of human activity caused them OR when the type of HI is known, but is not specifically listed above such as vehicular trauma, a projectile other than gunshot (arrow or dart), oil or chemical spill, stabbing or clubbing, *etc*. Describe *Other HI* in the space provided.

42 **STRANDING EVENT HISTORY/CIRCUMSTANCES** – provide any information about the stranding event or circumstances surrounding the event that would be helpful in supporting the HI diagnosis (*i.e.* fishing, drilling, or other activities, oil spill, unusual mortality events, previous sightings of animal, unusual behavior prior to stranding, *etc*.). Note any objective details provided by the initial reporter, these may be answers to questions you have asked (*i.e*. Was there any blood in the water next to the animal? What did it look or smell like when you first observed it? How was the animal positioned (belly up, on its side) when you first observed it?).

If there is no physical evidence but harassment is suspected, objectively describe events in this section including names and contact numbers for witnesses and any authorities that were contacted.

43 **INITIAL HUMAN INTERACTION EVALUATION** – This section should be completed if you circled YES under *Findings of Human Interaction* (line #40). It should be completed after filling out the entire data sheet. This section is **subjective** and takes into account the animal's physical condition, gross necropsy findings, the timing of the human interaction with respect to the stranding, and the circumstances surrounding the stranding. **Most importantly, it takes into account the evaluator's level of experience. If you have not conducted many evaluations or are not familiar with the region, you may be unable to make an accurate evaluation and should conservatively circle CBD.** This section does not take into account results of level B and C analyses or review by veterinary pathologist which is why it is considered an **INITIAL** evaluation.

For this section, you are estimating how likely you think it is that the documented human interaction contributed to the stranding event. This opinion is expressed as a confidence interval on a scale of 0-3, as described below. Circle the most appropriate number. The higher the number, the more likely it is that the interaction contributed to the stranding. If you do not feel that you can provide an evaluation, circle 0 – Uncertain (CBD). [Note: We do not say that the human activity *caused* the stranding because the human interaction could have indirectly contributed to the event without being the direct cause of the stranding.]

0. *Uncertain (CBD)* - You cannot provide an evaluation of the likelihood that human interaction contributed to the stranding (*e.g.* a Code 4 carcass is found with propeller marks; it is too decomposed to determine whether the interaction was pre- or post-mortem).
1. *Improbable* - It is unlikely that the observed human interaction contributed to the stranding or there are other gross findings that suggest an alternative cause for the stranding (*e.g.* there are healed entanglement scars on the flukes of a known humpback whale that died with a full-term fetus; it is unlikely that the past entanglement contributed to the stranding).
2. *Suspect* – It is possible that human interaction contributed to the stranding, but the findings of HI are weak and/or there are other findings that may have caused the stranding (*e.g.* there is a small amount of plastic found in an animal's stomach, but you are unsure of its effect and the animal is very thin with a high parasite level. Did the plastic ingestion cause the animal's decline or was a declining animal eating anything it could get?).
3. *Probable* - It is very likely that human interaction contributed to the stranding (*e.g.* a robust animal with a full stomach, froth in the lungs, and marks that are consistent with entanglement and underwater entrapment).

44 **JUSTIFICATION** – Provide a brief justification of your answer for the *Initial Human Interaction Evaluation* score. Include information from all sources available to you.

Document developed by IFAW MMRR and VAQS (2012) with funding from the John H. Prescott Grant Program

RECENT TECHNICAL MEMORANDUMS

SWFSC Technical Memorandums are accessible online at the SWFSC web site (http://swfsc.noaa.gov). Copies are also available from the National Technical Information Service, 5285 Port Royal Road, Springfield, VA 22161 (http://www.ntis.gov). Recent issues of NOAA Technical Memorandums from the NMFS Southwest Fisheries Science Center are listed below:

NOAA-TM-NMFS-SWFSC-500 Marine mammal and seabird bycatch in California gillnet fisheries in 2011.
J.V. CARRETTA and L. ENRIQUEZ
(December 2012)

501 Assessment of the Pacific sardine resource in 2012 for U.S. management in 2013.
K.T. HILL, P. R. CRONE, N.C.H. LO, D.A. DEMER, J.P. ZWOLINSKI, and B.J. MACEWICZ
(December 2012)

502 Upper Klamath and Trinity River Chinook salmon Biological Review Team report.
T.H. WILLIAMS, J.C. GARZA, N.J. HETRICK, S.T. LINDLEY, M.S. MOHR, J.M. MYERS, M.R. O'FARRELL, R.M. QUINONES, and D.J. TEEL
(December 2012)

503 Proceedings of the National Marine Fisheries Service Productivity Workshop, Santa Cruz, California, June 11-12, 2012.
A.T. MAMULA and J.B. WALDEN
(December 2012)

504 U.S. Pacific Marine Mammal Stock Assessments: 2012.
J.V. CARRETTA, K.A. FORNEY, E. OLESON, K. MARTIEN, M.M. MUTO, M.S. LOWRY, J. BARLOW, J. BAKER, B. HANSON, D. LYNCH, L. CARSWELL, R.L. BROWNELL JR., J. ROBBINS, D.K. MATTILA, K. RALLS, and M.C. HILL
(January 2013)

505 Spawning biomass of Pacific Sardine (*Sardinops sagax*) off U.S. in 2012.
LO, N.C.H., B.J. MACEWICZ, AND D.A. GRIFFITH
(March 2013)

506 Probability of taking a western North Pacific gray whale during the postponed Makah hunt.
J. E. MOORE, and D. W. WELLER
(March 2013)

507 Report of the National Marine Fisheries Service gray whale stock identification workshop.
D. W. WELLER, S. BETTRIDGE, R. L. BROWNELL JR., J. L. LAAKE, J. E. MOORE, P. E. ROSEL, B. L. TAYLOR, and P. R. WADE
(March 2013)

508 Inferring trackline detection probabilities from differences in apparent densities of beaked whales and dwarf & pygmy sperm whales in different survey conditions.
J. BARLOW
(April 2013)

509 Evaluation of an automated acoustic beaked whale detection algorithm using multiple validation and assessment methods.
E.K. JACOBSON, T. M. YACK, J. BARLOW
(March 2013)

Appendix E: Selected MMHSRP Protocols

Administration of Medications

E-10: Implementation Strategy for Emergency Vaccination of Hawaiian Monk Seals (DRAFT)

Implementation Strategy for Emergency Vaccination of Hawaiian Monk Seals

(DRAFT)

Last updated June 29, 2014

Table of Contents

Background	3
Timeline	3
Overview	4
ICS	4
Design of Field Teams	8
Volunteer Roles	8
Marking Seals	8
Vaccination Protocols	9
Pre-vaccination Assessment Checklist	10
Post-vaccination Assessment Checklist	12
Live Animal Sampling Protocol	13
Dead Animal Sampling Protocol	13
Proper Disinfection and PPE	14
Island Specific Considerations	15
Budget	20
Supply Lists	20

List of acronyms

MSF	Monk Seal Foundation
DOCARE	Division of Conservation and Resource Enforcement (Hawaii)
OLE	Office of Law Enforcement (NOAA)
DAR	Department of Aquatic Resources (Hawaii)
WAQ	Waikiki Aquarium
SLP	Sea Life Park
USGS	US Geological Survey
USCG	US Coast Guard

DRAFT

Background

Triggers for vaccination of free-ranging Hawaiian monk seals (HMS) against morbillivirus or West Nile virus include suspected or confirmed cases as well as antibody detection through routine health surveillance. While the safety and efficacy of vaccines are evaluated in captive monk seals and a routine vaccination program is developed for the wild population, an interim response plan for emergency vaccination of wild monk seals is needed.

Core information on vaccines, their use in phocids, and the triggers for vaccination of wild Hawaiian monk seals are outlined in the *Hawaiian Monk Seal Vaccination Research and Response Plan (HMSVRRP)*.

The following outlines specific protocols and logistical considerations should any of these triggers be reached, with a focus on morbillivirus. This document focuses heavily on the main Hawaiian Islands (MHI) where outbreak detection and emergency response are most feasible, and may be refined for the Northwestern Hawaiian Islands (NWHI) where applicable in the future. Additionally, this document identifies current gaps in response capability and outlines a budget for increasing vaccination preparedness.

A project was undertaken in 2013 using long-term datasets from the NWHI to model the potential spatial and temporal progress of a morbillivirus outbreak in HMS. The objective is to obtain reliable estimates of how quickly an outbreak may spread in the MHI and in a subpopulation in the NWHI. Results of this study will allow us to estimate tactical approaches and time constraints on vaccination and other emergency responses (such as quarantine) in order to contain an outbreak and limit its impact. This information is especially important when considering the logistical difficulties of vaccinating seals at remote locations such as Kahoolawe, Niihau and Lanai.

While guidance from the effort described above is pending, it remains prudent to design the response plan to enable vaccination of as many seals as possible as soon as a trigger is identified. *Thus, this document was created under the conservative assumption that, if a trigger is met, vaccination efforts in the MHI will need to be instituted on many islands simultaneously.* This assumption therefore places a greater demand on personnel, travel and equipment resources, which may be revised after informed by the outcomes of the modeling project.

DRAFT

Implementation Plan Timeline

Now (Summer/Fall 2014):

- Continue prophylactic vaccination trials in captive HMS and continue to purchase items on supply list as funds become available
- Early July: circulate revised document for internal review and prepare for external comment at August workshop
- August 5-7: have document prepared to share at the Marine Morbillivirus Workshop in Princeton, NJ

Short-term (Fall 2014):

- Mid-October: Incorporate feedback from August workshop, finalize operational plan and circulate among volunteers (NOAA/MSF, TMMC), and staff (NOAA, TMMC) that may be involved in response
- Determine appropriate interim vaccine (if any) while waiting on Purevax availablity
- Develop training protocols for vaccination response activities and begin training of staff and volunteers (work w/ PIRO, MSF, TMMC)
- Complete modeling project and move to publication phase (Baker, Barbieri, Harting, Littnan, Robinson)
- Begin outreach to public, agency partners, legislature (See Appendix C)
- Generate additional discussion on routine vaccination of HMS
- Implement prophylactic vaccination trial for wild HMS (as soon as appropriate vaccine is available)

Long-term:

- Develop refresher training modules and provide refresher training to staff and volunteers.
- Expand planning to include other emerging disease threats as appropriate

DRAFT

Overview of Vaccination Response

First 24 hours after trigger identified:

- Appropriate parties will be notified (See Figure 1, Table 1, Appendix A).
- Mobilize on-hand vaccine stores and immediately order additional vaccine.

24-48 hours after trigger identified:

- Trained volunteer surveillance on each island will be activated in order to:
    - Report seal ID and location for all observed seals
    - Identify and report potentially sick seals
- Field Teams will be deployed to administer vaccines to seals as specified by the trigger (see HMSVRRP) and according to protocols below.
- Scientific and animal health professionals will be consulted for additional non-binding input as needed.

Biomedical Sampling:

- Concurrent with vaccination efforts and to the extent that veterinary staff availability permits, blood and nasal swabs will be collected opportunistically from select wild, healthy animals
- Follow up collection of blood and nasal swabs on vaccinated seals will be conducted opportunistically 6-12 months post vaccination. At least 25% of vaccinated animals will be sampled within 6 months of treatment and at least 50% of all vaccinated animals will be sampled within 12 months of treatment.

Incident Command Structure (ICS)

ICS will be used for mobilization, organization and implementation of the vaccination effort (Figure 1, Table 1). The ICS and roles contained herein are consistent with the guidelines being developed for National NOAA ICS as well as those in use for Monk Seal Emergency Responses. See Appendix A for contacts. Some individuals may fill multiple roles or serve on multiple teams.

DRAFT

Table 1. ICS Roles and Responsibilities for HMS Vaccination Event

Title*	Roles and Responsibilities
HMSRP Manager	• Authority to make program decisions
Incident Commander	• Assembles Planning Team (logistics team lead, data team lead, response team lead, and lead veterinarian) • Focal point for information flow up and down command chain • Informs and briefs program manager/senior management
Communications Coordinator	• Receives, collates and disseminates regular (at least daily) updates to/from on-site coordinators and team leaders
Public Information Officer	• Issues press releases • Serves as primary media point of contact • Coordinates with Program Manager for all public releases of information
Liaison Officer	• Liaises with external agencies (MSF, DOCARE, OLE, DAR, Zoo, WAQ, SLP, USCG, etc.) (See Appendix A) • Coordinates staff/volunteer support for facilities preparations • Keeps IC updated on status of support assets • Coordinates with Logistics lead on seal hospitalization needs
Planning Team Leader	• Develop response plan with IC • *Planning team*: logistics team leader, data team leader, response team leader, lead veterinarian
Lead Veterinarian	• Updates IC on response effort and requests for additional assets • Makes decisions on courses of action for response in consultation w/ IC • Is available to vaccination teams for immediate consultation during vaccination response • Receives and facilitates information sharing among veterinarians/veterinary teams deployed in field/hospitals
Veterinary Team	• Responsible for health and welfare of seals • May conduct sampling *and* vaccination at some sites • Provide necropsy oversight as needed • Provide animal care & husbandry assistance in hospital(s) • Provide veterinary guidance for decisions regarding movement of seals among facilities • *Personnel will be divided to maintain appropriate quarantine*
Response Team	• Leads on-site coordinators and response teams • Support Veterinarian Lead

DRAFT

Leader	• Responsible for safety of personnel and volunteers • If no Veterinarian Lead, updates IC on response effort and requests for additional assets
On-site Coordinator (OSC)	• One for each island • Coordinates and communicates with all vaccination teams on one island and reports back to the Response Team Leader on Oahu • May serve on vaccination response team
Vaccination Response teams	• 2-3 trained persons per team • Carry out vaccination and marking of seals • May conduct sampling of seals with members of veterinary team • Communicate progress to OSC daily
Logistics Team Leader	• Coordinate logistics for transport of animals, supplies, and personnel travel.
Supply coordinator	• Responsible for inventory of vaccines, response kits, quarantine items, necropsy gear, sampling supplies • Orders new supplies when response occurs • Facilitates proper sample handling and storage • Responsible for submission of samples for testing
Data Team Leader	• Stays at central headquarters to be available for assistance with ID of seals and other data needs during response • Compiles data at the end of each day/response to summarize seals vaccinated, sampled, etc. and communicates w/ IC
Logistics Team *May also be part of Field Operations Team*	• Coordinate with OSCs to ensure all supplies and assets are available (trucks, boats, cages, etc.) • Coordinates travel arrangements with assistance from administrative staff • De-mobilize response, ensures all assets are cleaned and stored at end of response
Field Operations Team	• Provide on-scene support for response efforts, including animal handling, transportation, boat operations, etc. • Assist Logistics Team de-mobilize response • Assist Veterinary Technician process samples

DRAFT

Figure 1. Incident Command Structure for HMS Vaccination Event

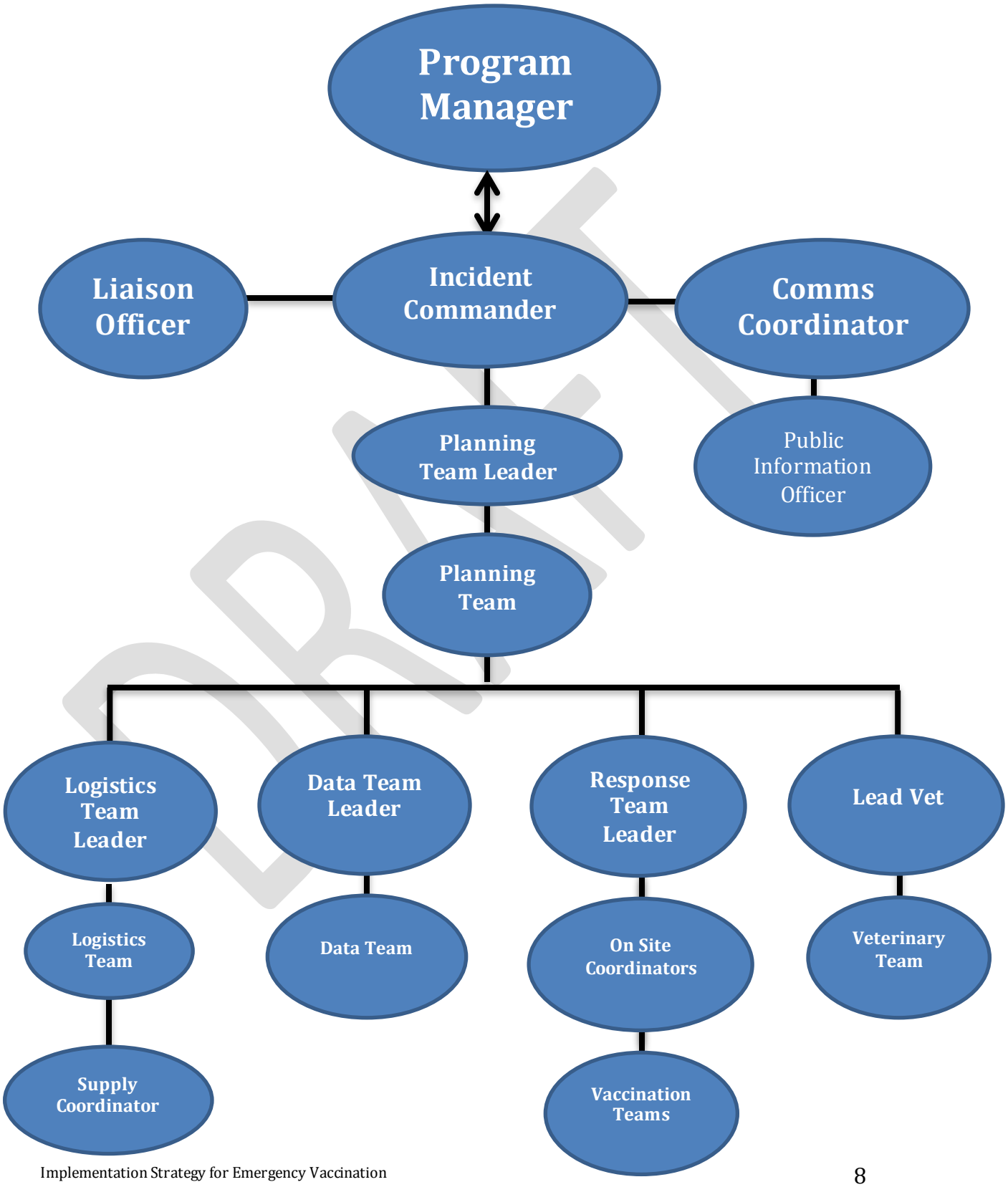

DRAFT

Design of Field Teams

Response vaccination administration will be accomplished by Field Teams. Field Teams will consist of staff (PIRO, PIFSC, Island Coordinators, State of Hawaii) and volunteers.

- **NOAA staff** will lead vaccination efforts, transport vaccination kits, maintain contact through the ICS and conduct training/refresher training.
- **Federal and state partners** may be asked to assist as needs arise, particularly in remote locations.
- **Volunteers** will conduct beach surveillance and provide real-time information on seal haulouts and identification. Trained volunteers may be asked to assist HMSRP staff in vaccination administration as needed.

Field Teams will not restrain seals and hence do not require a veterinarian or head handler (experienced and physically capable of leading capture and restraining head of large seals). Specific field team considerations relative to each MHI location are provided below (See "Island Specific Considerations").

Biomedical sampling (*i.e.*, blood and swabs) of healthy live seals may be elected in certain locations and a more robust Field Team with a head handler and trained biomedical sampling team will be necessary.

Volunteer Roles

Trained volunteers will:

- conduct surveillance for hauled out seals and sick seals,
- conduct post-vaccine monitoring of vaccinated seals.

Introductory training will be arranged through NOAA for key volunteers. Refresher and advanced training will be provided by NOAA staff on the ground. Volunteers trained by The Marine Mammal Center (TMMC) will be asked to assist with animal care and husbandry needs.

Upon administration of vaccines, volunteers may be asked to document the take of the seal with written notes and photographs. Volunteers may also be needed to assist with crowd control and outreach depending on the amount of people on the beach and the extent of animal handling.

Volunteers may be asked to assist in more advanced roles involving the use of crowding boards, playpens, restraint, and transport depending on needs of the vaccination team and level of training.

DRAFT

Marking Seals

Identifying individual seals that have been vaccinated is crucial to the implementation and assessment of the vaccination process. Most seals in both the MHI and NWHI can be identified by flipper tags, applied bleach marks, scars, and "natural bleach marks" (areas of lighter pelage). In the interest of safety, efficiency, minimizing seal disturbance, and improved public perception, HMSRP may decide to only apply a specific vaccination mark to seals that have not been previously identified and lack distinguishing markings. An applied bleach mark is the most efficient method for identifying seals with minimal disturbance. The HMSRP has trained Island Coordinators on bleaching seals for routine population assessment and will continue to support their bleaching efforts.

For seals that are *not* easily identifiable, vaccination marking will be necessary. The use of hair bleach used on sleeping seals may not be the most effective technique for marking vaccinated seals, as it requires a minimum of 4 minutes to take effect and requires the seal to be still and remain dry. HMSRP will test the use of colored epoxy as a potential marking technique.

Vaccination Protocols

The ideal vaccination schedule is as follows:

Day 0 – Initial vaccine
Day 28 (+/- 7 days)* – Booster vaccine
Day 365 – Booster vaccine

* Seals that do not receive a booster vaccine within 35 days of the initial vaccine may not develop sufficient immunity. Therefore, the vaccination sequence should be re-started for these individuals (*i.e.*, seals should receive a new "initial" vaccine at the next available opportunity and a booster 28 days (+/- 7 days) afterwards).

Table 2. Vaccination decision tree. The following table assumes that the trigger identified requires vaccination of both sexes. This may differ, according to the trigger. Refer to Vaccination Plan for specifics.

Scenario	**Vaccinate?**
Pregnant female (or suspect pregnancy)	Depends on type of threat and stage of pregnancy
Lactating female	Yes
Dependent (nursing) pup	**No**
Weaned pup	Yes
Adult male	Yes

Subadult or juvenile male	Yes
Sick/suspect sick seal	**No**
Molting seal	Yes
Seal vaccinated <21 days ago	**No**
Seal vaccinated +/- 28 days since initial vaccination	Yes
Seal not boostered in 35 days after initial vaccination	Yes; re-start vaccination schedule

Pre-vaccination Seal Assessment Checklist

1. Determine seal ID, age class and sex.
2. Is this seal of the appropriate sex for vaccination? (will be determined at time of response initiation based on particular vaccination trigger)
    a. If no, STOP – do not vaccinate.
    b. If yes, CONTINUE with assessment.
3. Has the seal been vaccinated previously? If so, how long since vaccination?
    a. If it has been < 28 days since initial vaccination, STOP – do not vaccinate.
    b. If >/= 28 days since initial vaccination, CONTINUE with assessment.
    c. If unknown, and of appropriate sex, CONTINUE with assessment.
4. Is the seal in a safe location to be vaccinated?
    a. If flushed, is there a safe escape pathway for the seal? Note rocky substrate or other hazardous structures, cliffs/edges or roadways on which the seal could endanger itself. If only escape route is through unsafe structures, STOP – do not vaccinate. Call lead veterinarian for guidance.
5. Complete the following visual health status assessment:
    a. Evaluate **nutritional condition**. If nutritional condition is emaciated, STOP – do not vaccinate. Complete remainder of visual health status assessment and then contact lead veterinarian.
    b. **Responsiveness**: Note any lethargy or lack of response to normal environmental stimuli. Do not approach seal to elicit response.
    c. **Respiratory rate (RR)** should be approx. 2-10 breaths per minute, depending on activity.
    d. **Respiratory effort/character**: Do you notice any straining to breathe? Any abnormal noise when breathing? (Occasional sneezing is normal)
    e. **Nasal discharge**: "Normal" nasal discharge is white/foamy and should not be pouring from the nares or exuded upon every

DRAFT

exhalation. Abnormal discharge is yellow, green, red and/or in great quantity.

f. **Ocular discharge and hydration**: Normal seals will have moist, clear eyes, sometimes with a small amount of wetness around them. Abnormal discharge around the eyes would be thick/viscous, yellow or green; the hair around the eyes may be matted. Dehydrated seals will have eyes that appear sunken back into the skull and dry, sometimes crusty ocular discharge around the eyes.

g. **External abnormalities**: is there any evidence of skin abnormalities or unhealed trauma, other wounds or abscesses?

h. **If any abnormalities are noted in steps a-g, STOP – do not vaccinate. Complete health status assessment and then contact lead veterinarian.** Continue to maintain visual on seal.

6. Has the vaccine been properly stored (fridge/ice packs)? If no, STOP.
7. If there are no contraindications as listed above, proceed with vaccination.

Important notes:

- Never vaccinate a seal that appears sick or otherwise debilitated.
- Vaccines must remain cold (refrigerated or on ice packs in a cooler) at all times.
- Do not draw up vaccine into syringe until it is ready to be used.
- Maintain sterility – never re-use needles. When in doubt about sterility, use a new needle.

Protocol for vaccination of single seal:

Vaccination may be administered without the use of crowding boards but personnel ("crowders") should be close by and ready to block seal from escape into water before vaccination or from dangers in the area. To minimize disturbance, a pole syringe will be used to eliminate the need for restraint. The vaccinator should try to approach without being detected, administer the vaccine, and quickly back away. Ideally the seal would not be flushed into the water allowing it to be observed from a distance.

1. Confirm seal ID, take photos and standard data; obtain ancillary video if it helps with identification or documentation.
2. Complete veterinary pre-vaccination checklist
3. Assign roles and brief on plan
4. Draw up vaccine and vaccinate using pole syringe
5. Record results and post-vaccination observations
6. Disinfect or dispose of gear that was in contact with seal

DRAFT

Protocol for vaccination of single seal & application of mark:
If the seal is unidentifiable, the team should take multiple photos and apply a vaccination mark immediately after successful vaccination. Crowding boards will be used to ensure that seals do not flush into the water after vaccination. If bleach marking must be used, it will be important for personnel using the crowding boards to maintain control of the seal to ensure it gets marked appropriately.

1. Confirm seal ID, take photos and standard data; obtain video if necessary.
2. Complete veterinary pre-vaccination checklist
3. Assign roles and brief on plan
4. Prepare marking materials
5. Draw up vaccine
6. Crowders gain control of seal
7. Vaccinate using pole syringe and mark seal
8. Record results and post-vaccination observations
9. Disinfect or dispose of gear that was in contact with seal

Protocol for vaccination when multiple seals are in the same location:
Ensure correct identification of seals, consider marking needs and develop strategy for vaccinating as many seals as safely possible. Consider: a) working as two teams on separate seals, or b) using extra crowders to "hold" a seal while another is vaccinated (crowders monitor waiting seal for signs of stress).

If only one seal needs a vaccination mark, it should be vaccinated and marked first. If both seals need vaccination marks, vaccinate seal with highest priority first. When crowding multiple seals, separate them to avoid injury and minimize stress.

1. ID seals, take pictures, and standard data; obtain video if necessary.
2. Decide on priority seals (female>male)
3. Veterinary pre-vaccination checklist
4. Assign roles and brief on plan
5. Prepare marking materials if necessary
6. Crowders gain control of seals
7. Draw up vaccine and vaccinate using pole syringe; apply mark if necessary
8. Record results and post-vaccination observations
9. Disinfect or dispose of gear that was in contact with seal

The above protocols are designed with the intent that vaccinations will be administered without handling of the seal using the pole syringe. If seals are handled for other reasons (epidemiology sampling, pole syringe malfunction),

a standard syringe and 18 gauge x 1.5" needle may be used to administer the vaccine by hand.

Post-vaccination Seal Assessment

1. **Responsiveness**: Note any lethargy or lack of response to normal environmental stimuli. Do not approach seal to elicit response.
2. **Respiratory rate (RR)** should be approx. 2-10 breaths per minute, depending on activity.
3. **Respiratory effort/character**: Do you notice any straining to breathe? Any abnormal noise when breathing? (Occasional sneezing is normal)
4. **Nasal discharge**: "Normal" nasal discharge is white/foamy and should not be pouring from the nares or exuded upon every exhalation. Abnormal discharge is yellow, green, red and/or in great quantity.
5. **Ocular discharge and hydration**: Normal seals will have moist, clear eyes, sometimes with a small amount of wetness around them. Abnormal discharge around the eyes would be thick/viscous, yellow or green; the hair around the eyes may be matted. Dehydrated seals will have eyes that appear sunken back into the skull and dry, sometimes crusty ocular discharge around the eyes.
6. **Injection site**: is there any swelling or discharge at the injection site? Do you see any external skin abnormalities, other wounds or abscesses?

DRAFT

Live Animal Sampling Protocol

Not all vaccinated seals will be sampled prior to vaccination. As time and logistical considerations allow, some seals may be sampled during the vaccination effort in order to assess possible exposure or to measure post-vaccination titers. All samples should be put in a cooler with blue ice in the field immediately. The following minimum samples should be collected during live animal sampling:

- Two red top tubes
- One EDTA/lavender top tube
- 4 nasal swabs
- Remainder of Epi Sampling Protocol as time permits

Table 3. Live Animal Sampling Requirements

Sample type	Minimum # of samples	Test	Laboratory	Storage
Serum (RTT)	2 mL	Serology (serum neutralization, PCV, CDV, CMV)	U of Georgia	-80°C
Serum (RTT)	1 mL	CBC	Idexx/Antech	Blue ice/ fridge; send out
Whole blood (LTT)	1 mL	Chemistry	Idexx/Antech	Blue ice/ fridge; send out
Nasal swab	1 swab in RNA later	PCR, sequencing	U of Florida	-80°C
Nasal swab	1 swab in VTM	PCR, sequencing	UC Davis	-80°C
Nasal swab	2 swabs in separate dry cryovials	Archive	Archive	-80°C

Dead Animal Sampling Protocol

Dead seals reported during an outbreak situation require immediate sampling and necropsy. The MHI Necropsy Protocol should be followed.

Top priority samples include: blood (serum, buffy coat), nasal swabs (in RNA later, VTM and dry cryovials), fecal swabs (dry cryovials) and paired samples of tissue (lung, pulmonary lymph node, liver, brain, CSF), one of which should be fixed in formalin and the other frozen at -80°C. An individual involved in a necropsy should not subsequently be in contact with live seals until in the person has undergone full disinfection (shower, complete change of all clothing and footwear).

DRAFT

Proper Disinfection and PPE

Over the course of vaccinating seals, it is possible that Field Teams will come across an infected seal shedding morbillivirus but not showing any clinical signs. Fortunately, morbillivirus survives poorly outside of a host. For disinfection purposes, conservatively assume that all seals and their body fluids are infective to other seals.

Fomites are objects that can carry infectious pathogens (germs) from one place to another. Likely fomites in a vaccination situation include clothing, dirty hands, footwear, and medical supplies. To avoid being a fomite (think "Typhoid Mary"), only take essential gear in the vicinity of seals. Always wear clean gloves and dispose of gloves between animals. Disinfect all gear that comes in contact with a seal or seal bodily fluid (urine, feces, blood) and do not allow "dirty" gear to come in contact with clean gear. Change into fresh coveralls if there is any chance that they may have contacted the animal or bodily fluids. Always dispose of sharp instruments properly in a designated container and do not reuse needles.

The preferred disinfectant is Accel (accelerated hydrogen peroxide). It can be used as a detergent and disinfectant for all types of gear, is environmentally friendly, nontoxic and is not affected by sunlight. Accel must remain on surfaces for a minimum of 5 minutes in order to properly disinfect. Organic material such as dirt can harbor germs, so always be sure to wash objects of debris *before* disinfecting.

An alternative disinfectant is dilute bleach, which must remain on surfaces for a minimum of 10 minutes to properly disinfect and can be inactivated by heat/light after 24 hours. Surfaces must be cleaned of all organic material before bleach is used as a disinfectant.

Do not allow any gear used in the field during vaccinations to come in contact with pets or livestock.

DRAFT

Island-specific Considerations

Information on survey sectors (adapted from the annual Monk Seal Count) and related volunteer contacts, accessibility and primary substrate type (rocky vs. sandy) is contained in Appendix B. Seal sighting data reported to HMSRP were used to calculate the number of individual seals sighted on each island in 2012 and are listed below ("Seal usage").

Kauai

With strong support on Kauai and many seals frequenting easily accessible beaches, the field team may only need a few days to vaccinate a large portion of the population and train local partners to take over. Revision: With strong support on Kauai and many seals frequenting easily accessible beaches, Island Coordinators and trained volunteers may not require as much additional staff support as other islands and can likely transition into a self-sufficient team in a period of days to weeks.

Access –Many areas are accessible by car/truck.
Surveillance - Well represented, with volunteers on all sides of the island
Personnel – Two Island Coordinators (J. Thomton, M. Olry) and many experienced volunteers
Seal usage – 46 individual seals were observed in 2012
Field Team requirements – Two teams (One staff and 2-3 volunteers per team) would provide adequate coverage. One HMSRP staff person would be a part of the team to provide initial guidance and oversight; this individual could provide a third team to speed the initial response.

Oahu

Access - No inaccessible areas. Kahuku, Kaena, Rabbit Island and other offshore islets are more difficult but possible.
Surveillance – Well represented with volunteers on all sides of the island
Personnel – Well-staffed
Seal usage - 42 individual seals observed in 2012
Field Team requirements – Two field teams would be needed to cover all areas and many seals in a short time. This presents hands-on training opportunities for staff and volunteers that could be deployed to provide assistance to other islands.

Molokai

Access - North shore areas are difficult
Surveillance – Moderate staff/volunteer coverage
Personnel – Diane Pike and volunteers (primarily topside); NPS staff in Kalaupapa.
Seal usage - 52 individual seals observed in 2012
Field Team requirements - Due to the remote nature of Kalaupapa and the west side of Molokai, deployment of three Field Teams would be preferred, if feasible.

> Three Field Teams would consist of:
> 1) Kalaupapa (one NOAA staff with ample assistance from NPS staff on-site). After 1-2 days, most seals in the area would be vaccinated and the NPS team would be well trained and able to continue vaccination and monitoring efforts without NOAA staff. The NOAA staff person could be deployed to one of the other two areas.
>
> 2) West side (1-2 NOAA staff, 1-2 volunteers): The West side team would have the most daunting task as there is relatively more ground to cover and likely more seals to vaccinate. They should receive support from the other Molokai teams after 1-3 days.
>
> 3) South and East sides (one NOAA staff person, two volunteers). The SE team is the lowest priority and, depending on resources, may not be deployed for long. If possible, the SE team should opportunistically cover the SW side from Hale o Lono to the last SW beach (Halawa).

Maui

Access - Hana side and Northwest areas could be difficult. Boat support would be required for access in some areas.
Surveillance – Few volunteers
Personnel – One Island Coordinator (N. Davis)
Seal usage - 15 individual seals observed in 2012
Field Team requirements - Minimally, two HMSRP staff would be needed to create two Field Teams that can divide among different sides of the island or between land-based and boat-based efforts.

DRAFT

Hawaii

On Hawaii Island, with minimal support, large areas, and few seals, the field team may need more time to find seals and train local partners.

Access - Many difficult regions and vast remote areas.
Surveillance - Minimal
Personnel – One part-time Island Coordinator (J. Viezbicke), few volunteers.
Seal usage - 7 individual seals observed in 2012
Field Team requirements - One to two Field Teams (1 staff person, 2-4 volunteers for training per team). Hawaii Island may not be top priority for HMSRP staff if proper advance training is provided to Island Coordinator and if adequate volunteer and partner support can be provided (The Marine Mammal Center).

Based on sparse seal sightings and limited accessibility, islands such as Lanai and Kahoolawe are a lower priority in a vaccination effort. Disease outbreak model may provide insight into if/how to prioritize efforts among these locations. Seals on these islands could be vaccinated when seen on Maui, Molokai and Oahu

Lanai

With accessibility issues and only 3 seals observed in 2012, the number of seals vaccinated per day on Lanai could be too low to justify effort, at least not at the expense of other islands. Depending on available resources and recent seal observations, effort on Lanai may be considered.

Access – Great difficulty in most areas
Surveillance – No volunteer surveillance in place
Personnel – No volunteers or staff on island; DOCARE provides occasional stranding assistance
Seal usage - 3 individual seals observed in 2012
Field Team requirements – one field team, composed of at least one staff person and volunteers that have been adequately trained on other islands

Kahoolawe

Access – Restricted due to presence of unexploded ordnances on island; escort required. Only a portion of the island is accessible by foot and many areas are steep cliffs that do not offer adequate haulout space for seals. Reaching some areas would require swimming or paddling into shore from a boat (additional logistical input needed). Travel to the island can be done by boat or helicopter (from Maui).

Surveillance – Minimal. There are two KIRC staff on island for a period of 3-4 days twice monthly. Seal surveys are dependent upon their other priorities and are not

guaranteed. Helicopter surveys of island could be conducted concomitant with personnel transport to the island.

Personnel – Visitors must fill out KIRC visitor form and keep it on file with KIRC. KIRC staff must escort visitors for all operations.

Seal usage – 13 individual seals have been observed over a period of years. Of these, 7 are also seen on neighbor islands (Maui, Molokai, Hawaii).

Contacts – KIRC Ocean Program Staff

Current gaps/needs - Permission and coordination with Kahoolawe Island Reserve Commission (KIRC) staff; Logistical considerations for accessing remote areas

Kahoolawe Map:
*yellow – accessible by vehicle/foot
*red = sheer/steep cliffs (exception Kanapou Bay), little to no haul out area

Niihau

Access – May vary. Dependent upon approval from Robinson family (owner), which will be coordinated through NOAA PIRO (POC: Jeff Walters)

Surveillance - Minimal. Unlikely chance of cooperation with Robinson family, but NOAA is making efforts to reach out again.

Personnel – The island is privately owned and there are no staff or volunteers

Seal usage – Including Lehua, this is likely the largest HMS population in the MHI, estimated at 50 to 100 seals, based on aerial survey data. Seals from this island may also use Kauai on a regular basis.

Contacts - NOAA PIRO POC to oversee contact w/ Robinsons

Vaccinating seals on Niihau is crucial to overall success as many seals are known to travel between Kauai and Niihau. In the recent past, NMFS access to Niihau has been very limited to few visits under unusual circumstances such as suspicious deaths and seals needing medical intervention. A positive relationship and high level of transparency should be maintained with Niihau contacts. They should be made aware of any plans to work around the island (Lehua) and also updated on important happenings on Kauai. NMFS should request input and suggestions from Niihau contacts on how to best vaccinate seals there. In addition, NMFS should thoroughly explain how vaccinating would benefit seals and the possible repercussions to the seal population if not allowed.

Current needs – Establish rapport with Robinson's via veterinarian (Barbieri) and other appropriate NOAA staff. Subsequently, send the Robinson's our vaccination plan and solicit feedback and ask for permission. Evaluate transportation options to/from Niihau, which may include Niihau helicopter (permissible?), vessel (Searcher, charter out of Port Allen, Capt. Tara).

- Port Allen to North Ni'ihau: 30 miles (1.5 - 3 hours, depending on conditions and vessel).
- Consider Lehua. Robinson's permission not required, but they should be notified.
- Searcher or similar charter would be most efficient and probably most attractive to Robinsons. It would also allow for work on Lehua without needing to camp.

BUDGET

Travel

Considerations:

- If training needs are addressed appropriately, it could increase reliance on local staff and volunteers and reduce the number and duration of HMSRP staff visits on other islands and ultimately minimize costs.
- Volunteers will be trained in advance and will receive on-the-ground training by staff so that they are able to assist. Trained and experienced volunteers from Oahu and Kauai may be used to provide support on islands with fewer volunteers, such as Molokai.
- Fed/JIMAR - Differences in per diem, overtime and budgets for federal and JIMAR staff should be considered.
- Duration of trip needed - One week or less should suffice for most islands. It may be possible to train local staff within a day or two and expect them to maintain efforts thereafter.
- Lodging - see Response Travel Info spreadsheet
- Transportation/rental vehicles - Rental vehicles will be necessary on all islands to transport the teams. Some islands will require 4WD vehicles.
- Sending gear - Multiple crowding boards, pole syringes, nets, cages, pens may be necessary on all islands.

General travel budget for 3 day trips with minimal expenses (excluding Lanai, Kahoolawe and Niihau):

Staff - 2 to Kauai, 2 to Molokai, 1 to Maui, 1 to Hawaii
Airfare - 6 x $250 = $1500
Gear transport/checked bags - 4 x $30 = $120
Vehicle Rental - 4 x $60 x 3days = $720
Lodging - 4 x $200 x 3days = $2400
Per diem - 6 x 110 = $660
Total = $5400

DRAFT

Supply Lists

The following supplies are recommended for purchase as funds allow:

50 vaccines to store on Oahu (in-date, at all times) $625/12-18 mo.

Vaccine: Merial recombinant canarypox vectored ferret CDV. A special order account has been set up through PIFSC, as this product is NOT stored on island. It is shipped directly from Merial. Per Merial, ordering 200 would not be expected to be problematic, though there is no guarantee. The product is currently on backorder; hence the desire to store at least 50 vaccines on island at all times.

- Shipping time: 2 days (when in stock)
- Shelf life: approx. 1 yr.
- Cost: $12.42 per dose

Dan Inject Jab Sticks $8000 (for 10)

Spring loaded pole syringes are preferable due to their ease of use and reliability. Currently, there are two on Oahu. Additional Jab Sticks have recently been purchased for Kauai, Molokai (topside) and Hawaii. In order to have the capacity to deploy more than one Field Team per island, additional pole syringes should be added to the supply cache whenever feasible. We desire up to 10 additional Jab Sticks at an estimated cost of $800 each.

Diagnostic screening supplies $500

- RNA later: 100 vials
- VTM: 100 1ml aliquots (in 2ml cryovials)
- Cryovials

Diagnostic tests *(depends on number of seals sampled)* **$5000**

- Serology
- PCR and genotyping
- Virus isolation
- Histopathology, immunohistochemistry
- Shipping

PPE $1000

- Gloves
- Adequate supplies of coveralls
  - Additional reusable coveralls ordered 8/2012
  - May supplement with disposable if needed
- Disinfectant for gear, coveralls, etc. between animals (Accel concentrate preferred)
- Spray bottles, buckets

Mobile devices for database access and data recording $TBD

- In development (Vikram's Tiger Team)

Marking supplies for each team $TBD

DRAFT

Veterinary supplies

The following supplies are regularly maintained in Honolulu:

- Blood and swab collection supplies (will be used for all sick seals; select healthy seals):
  - Vacutainer needles, hubs
  - Spinal needles and vacutainer adaptors for spinal needles
  - Vacutainer tubes (serum separator, EDTA, NaHep, PAX gene)
  - Sterile cotton tip applicators for nasal swabs
  - Centrifuge or access to one on each island
  - Cooler with blue ice and tube racks
  - Cryovials
- Assorted needles
  - 18 g x 2"
  - 18 g x 1.5"
- Assorted syringes for hand administration of vaccines if needed, blood collection, sedation
- Sedation drugs: Midazolam, Diazepam and Flumazenil reversal agent
- Crash kits (2)
- Telemetry supplies
- Supplies to pick up, transport, stabilize sick animals if encountered (crate, garden sprayer, fluids) and pen on beach
- Datasheets (write in the rain), clipboards, writing utensils
- Shipping supplies for specimen transport to HNL/laboratories

<u>Vaccine Kits</u>

Each kit will contain enough supplies for a Field Team to vaccinate 10 seals.

- Pole syringe
- 40 assorted needles (18g x 2", 18g x 1.5")
- 10 vaccines
- 2 ice packs
- cooler
- PPE
- Accel disinfectant
- Marking supplies
- Small sharps container
- Mobile device for database access (and photography) - TBD
- GoPro as supplies permit
- Satellite phone for teams in remote locations
- Hard copy datasheets on rite-in-the-rain paper, writing utensils
- Clipboard
- Copies of all protocols
- Copy of permit

DRAFT

Quarantine supplies

Quarantine of sick or potentially sick seals will be done initially using beach pens. Seals will be maintained on the island on which they were found. Transport of sick seals may only occur under veterinary discretion. These supplies will be transported by the field vaccination teams and the veterinary teams if/when the need arises:

- Playpen fencing and supports
- Bungee cords
- Animal husbandry supplies
- Controlled drugs for sedation (and reversal agent)
- Crash kit
- Medical supplies for supportive care/treatment of sick seals
- Disinfectant (Accel)
- Blood and nasal swab sampling kits
- FedEx labels, boxes for shipping samples to diagnostic laboratories

Necropsy supplies

If necropsy supplies are not already on each island at the time of a vaccination response, the vaccination teams will transport them to each island.

Additional needs

- Develop training presentation
- Drills to simulate vaccination scenarios and deploy personnel and supplies
- Supply purchases
- Rehab/sick seal disposition: discuss possible decisions on disposition locations for sick seals vs. seals admitted to rehabilitation for other reasons (trauma, malnutrition, etc.)
- Database for teams on seal ID's and demographics, tracking data collected
- Outreach and legislative briefing materials (in development)

DRAFT

Appendix E: Selected MMHSRP Protocols

Administration of Medications

E-11: Right whale sedation protocol for EG 3311

Sedation Protocol for Eg 3311 on 3-5-09 and 3-6-09

The discussion of the sedation group on 3-2-09 following the general disentanglement planning call and the previous results from use the lower levels of drugs noted below resulted in the following recommendation from the group:

Thursday
After new visual evaluation and body weight estimates the initial protocol includes the following possible range of drug use:

Butorphanol 0.0725 to 0.1 mg/kilo
Midazolam HCL 0.0725 to 0.1 mg/kilo both administered together.
At 0.0725 for each drug this would be one full dart. We are leaving in the option for a higher two dart administration at 0.1 mg/kg for each drug if changes in the animal's condition warrant a stronger approach.

Note that there is also midazolam from base stock available but it is not compatible with the concentrated butorphanol so it will need to be administered in a separate dart when used.
Post Injection
Wait 25 minutes for full drug effect observing swimming speed, respirations (surfacing interval) and any other behavioral changes from the plane and boats.
Then approach with small boat to gauge behavioral change and evidence of sedation. If positive in its response to approach, disentanglement personnel will be on board to cut the lines while in proximity.

If not adequate then regroup and decide whether to add on additional drug or hold off on any other administration till the following day.

Friday

The following plan is for an increase in the dosage level of the two drugs as below as dictated by the response the day before with 0.0725 mg/kg for each drug:

Butorphanol 0.1 mg/kg
Midazolam 0.1 mg/kg

Wait 25 minutes and evaluate with small boat approach and potential for initiating removal.

If unsuccessful and it is felt that this animal will perish without intervention then will look at adding on detomidine at 3 to 6 mcg/kg or can use dexmedetomidine if we lose the original drug in dart malfunction or misses.