Appendix E: Selected MMHSRP Protocols

Appendix E: Selected MMHSRP Protocols

Hazing

E-1: Supporting information for the Killer Whale Section of the Northwest Wildlife Response Plan, Chapter 9970 of the NWACP (available at: http://response.restoration.noaa.gov/sites/default/files/whale_response.pdf)

Supporting Information for the Killer Whale section of the Northwest Wildlife Response Plan, Chapter 9970 of the NWACP

I. This document is intended to provide contacts and supporting information for use by spill responders when implementing or testing the Killer Whale – Monitoring and Hazing Plan for Oil Spill Response. Tables 1. thru 3. contain contact information for knowledgeable personnel and equipment. This is followed by a practicality analysis that supports the hazing method priority table contained in the Monitoring and Hazing Plan and a section that describes the general advantages and disadvantages of each hazing method.

A. Table 1: Groups or individuals who are able to identify killer whales to ecotype, pod and individual

Name	Contact Number
Cascadia Research Collective	(360) 943-7325
Center for Whale Research	(360) 378-5835
Department of Fisheries and Oceans	(250) 729-8375
Lifeforce Foundation	(604) 649-5258
Northwest Fisheries Science Center	(206) 860-3220
Whale Museum	(800) 562-8832

B. Table 2: Regional whale sighting networks

Resource	Phone Number	Contact Person
BC Cetacean Sighting Network	(866) I-SAW-ONE	
Cascadia Research Collective	(800) 747-7329 or (360) 943-7325	John Calambokidis, Erin Falcone or Robin Baird
Center for Whale Research	(360) 378-5835	Ken Balcolmb

Fisheries & Oceans Canada – British Columbia Marine Response Network	(800) 465-4336	Marine Mammal Incident Coordinator
Lifeforce Whale and Dolphin Hotline	(604) 649-5258	Peter Hamilton
Northwest Fisheries Science Center	(206) 860-3220	Brad Hanson or Dawn Noren
Orca Network	(360) 678-3451	Susan Berta or Howard Garrett
Whale Museum Sighting Hotline and acoustic array	(800) 562-8832	Jenny Akinson or Amy Traxler
Pacific Whale Watch Association	(360) 661-5830 (cell) or (360) 293-2428 (office)	Shane Aggargard, President

C. Table 3: Resources available for deterring killer whales from an oil spill

Resource	Location	Contact Name	Contact Number
Oikomi Pipes (12)	NOAA Sand Point Facility	Brent Norberg or Lynne Barre	(206) 526-6550 or (206) 526-4745
Seal Control Devices	NOAA	Brent Norberg or Lynne Barre	(206) 526-6550 or (206) 526-4745
AHDs and ADDs	NOAA	Brent Norberg or Lynne Barre	(206) 526-6550 or (206) 526-4745
44' shallow draft boat with licensed captains and capabilities for safe use 24-7 (including night vision capability and underwater speakers with onboard amplifiers)	Global Research and Rescue	Bob Wood	(206) 954-5192
27’ Pacific aluminum skiff with center console	NOAA/NWFSC, Seattle	Dawn Noren	(206) 302-2439
26’ Olympic XL boat with cabin and cockpit	SeaDoc Society, Orcas Island	Joseph Gaydos	(360) 376-3910 or (360) 914-1083
24’ ProLine center console boat	NOAA	Brent Norberg or Lynne Barre	(206) 526-6550 or (206) 526-4745

19’ SAFE Boat	Whale Museum	Jenny Akinson	(800) 562-8832
18' rigid-hulled inflatable boats (n=2)	Cascadia Research, Olympia	John Calambokidis, Erin Falcone or Robin Baird	(360) 943-7325 or (360) 280-8349
18’ Campion boat with 150 HP outboard, large open cockpit with optional full canvas camper cover.	Lifeforce Foundation, Vancouver, BC	Peter Hamilton	(604) 649-5258
Killer Whale Call Recordings	Center for Whale Research	Ken Balcomb	(360) 378-5835
Killer Whale Call Recordings	Department of Fisheries and Oceans, BC	John Ford	(250) 729-8375
Underwater Playback Systems (n=2) and Killer Whale Call Recordings	Lifeforce Foundation, Vancouver, BC	Peter Hamilton	(604) 649-5258
Numerous boats of varying size	Whale Watch Operators Association Northwest	Shane Aggargard, President	(360) 661-5830 (cell) or (360) 293-2428 (office)

D. Hazing Method Practicality Analysis

As detailed in the table below a practicality analysis of the various hazing methods considered was conducted by enumerating values for the efficacy, speed of deployment, risk of injury to the whales, level of training requirements for crews using the method, number of people required to implement the method and equipment availability. There is no one hazing technique that will work in all situations. The potential benefit of employing a technique will be a product of the current circumstances, how the technique is employed, the experience of the people employing the technique and the degree to which whales are attracted to an area. The risk of killer whale exposure to oil must be considered relative to the risk associated with hazing.

Ranked Practicality of Various Hazing Methods							
Method	**Efficacy (double score)**	**Speed**	**Risk of Injury**	**Training Requirements**	**Personnel Required**	**Equip Available**	**Total**
Oikomi Pipes	4 (8)	3	4	3	1	4	23
Seal control devices	4 (8)	3	2	2	3	4	22
Aircraft	3 (6)	4	4	0 *	4	4	22
Experimental Methods	1 (2)	2	3	3	4	3 **	18

Acoustic Deterrent Devices	1 (2)	3	4	3	2	2	16
Fire Hoses	1 (2)	3	2	2	3	3	15
Acoustic Harassment Devices	1 (2)	2	2	2	4	2	14
Vessel Traffic	1 (2)	3	2	2 ***	2	3	14
Killer Whale Calls	0 (0)	2 to 3	3 to 4	0	4	4	13 to 15
Mid-frequency sonar	3 (6)	0	2	0	0	0	8
Air guns	1 (2)	0	2	0 ****	2	0	6

***Not hazing is always an option to consider**

Key to Values in Table:

Numeric value	Assessment of efficacy	Estimated time to deploy	Risk of injury to SRKW
0	Unlikely to work on SRKW	More than 48 hrs	Previously documented injuries
1	unknown efficacy	within 48 hrs	suspected injury
2	Judged likely to work	within 24 hrs	injury if misused
3	anecdotal evidence of efficacy	within 8 hrs	injury unlikely but not well studied
4	Documented experience of efficacy	within 2 hrs	injury unlikely
Numeric value	**Time required to train participants**	**# of people required**	**Equipment Availability**
0	Greater than one day	More than 50	Requires 3rd party approval (Navy, City, etc.)
1	1 day training	21 to 50	High cost
2	less than 2 hours training	11 to 20	No local vendor
3	verbal instruction given at time	5 to 10	Easily purchased or available locally
4	Non -required	1 to 4	Available in stock or stored

COMMENTS
Method
Oikomi Pipes - Limited number (12) stored, but materials for fabrication are readily available
Acoustic Harassment and Deterrent Devices - None stored
Speed
Killer Whale Calls - There are limited sources for recordings
Risk of Injury
Killer Whale Calls - Limited experience indicates that response is unpredictable and possibly aggressive

Training Requirements
*Aircraft - Operation of aircraft in pursuit of wildlife requires extensive training
****Air Guns - Operation of seismic exploration equipment requires extensive training
***Vessel Traffic - Assumes vessel operators are pre-qualified to drive boats
Mid-frequency Sonar - Operation of sonar equipment requires extensive training
Personnel Required
The number of personnel required is highly dependent on the scale of the exercise and basic work unit size must be defined for each method
Equipment Available
Aircraft - Assumes that aircraft used for reconnaissance are also available for limited hazing efforts
Acoustic Deterrent Devices (Pingers) - Recommend stockpiling a supply of these locally
** Experimental Methods - Highly dependent on technique

E. Hazing Method Advantages and Disadvantages

Potential deterrent options were evaluated by Killer Whale experts and oil spill response personnel (see More Detailed Information below) and are listed with their associated positive and negative benefits to provide a range of options to be considered under the circumstances. In addition to weighing the hazing options provided, the Wildlife Branch also must consider the costs and benefits associated with taking no hazing action.

i. Close-range hazing techniques

1. Oikomi Pipes: Oikomi pipes are reverberant metal; usually a pipe with a cap on the top. A handle on the top of the pipe and a cone at the bottom of the pipe improves reverberation. When numerous pipes are used in multiple lines, they have been effective at moving killer whales at close range.
   - Advantages: Oikomi pipes have been used and are very effective at herding whales. This is safe for the whales and would have a high public acceptance level.
   - Disadvantages: This technique would be most effective for herding of animals and might not be as efficacious for keeping animals out of a very large area (such as in the middle of Juan de Fuca Strait). Deployment requires coordination of multiple vessels and could be dangerous at night or during poor sea conditions.
2. Seal control devices: These are explosive devices that put out a pulse of noise and previously were used effectively to drive whales during the live captures in Puget Sound in the 1970's.

   a. Advantages: They worked from about 1 mile away during whale captures. They are not very expensive and readily available.

b. Disadvantages: There could be concerns about using these explosive devices where highly volatile oil was located. These could cause fish mortality.

3. Acoustic Deterrent Devices (ADDs): ADDs make sound not loud enough to cause pain, but which is audible to marine mammals. ADDs are often called net pingers.

    a. Advantages: They are readily available and could be easily deployed on oil booms or vessels.

    b. Disadvantages: They may not have sufficient power to deter whales and whales may habituate quickly.

4. Killer Whale Calls: Prerecorded calls can be played from a small boat to theoretically either attract whales away from an area or deter them from entering an area.

    a. Advantages: Prerecorded calls and broadcasting equipment are readily available and could be deployed from a highly mobile small vessel. This is not dangerous to whales or other species in the area. This technique needs further study.

    b. Disadvantages: There have been no rigorous studies showing that calls will consistently cause whales to avoid or be attracted to the source. It is likely that animals could habituate to this relatively quickly.

5. Vessel Traffic: The noise and motion of boat traffic could be used drive whales from an area or deter them from entering one.

    a. Advantages: Small boats are potentially available for this activity.

    b. Disadvantages: Boats have very little value in long-range displacement of killer whales, especially the highly conditioned southern resident killer whales.

6. Aircraft: Helicopters can generate a fair amount of noise and wave movement at close range and could produce a startle or avoidance response.

    a. Advantages: This might be very effective initially because whales are not used to it. It can be quickly mobilized and could provide real-time tracking of whales. Also, it could simultaneously be used to deploy additional deterrent devices such as seal control devices.

    b. Disadvantages: There is no guarantee that helicopters will be able to control whale movement and whales would likely habituate to helicopters quickly. Because of the above-water nature of this deterrent it would affect the behavior of birds and other animals in a way that might not be beneficial (i.e. scare birds off un-oiled shorelines with the chance they will land in oiled areas). If helicopter hazing were used in combination with other hazing methods, such as launching of explosives, then this would require the development of specific safety protocols and perhaps special safety equipment such as a launcher.

7. Fire hoses: Fire hoses could be used to direct streams of water at whales on the surface at extremely close range.

a. Advantages: Boats could be equipped with pumping capacity and deployed on fairly short notice. High powered fire monitors mounted on some regional tug boats can send a stream over water over 100 yards.

b. Disadvantages: There are no data on the effectiveness of this technique and it is limited to very close range (approximate 100 yards).

8. Strobe lights, bubble curtains, booms or other experimental methods: Theoretically these could provide a visual deterrent and perhaps prevent killer whales from entering a spill.

   a. Advantages: Theoretically these could be used to fence off an area without risk of physical harm to the whales.

   b. Disadvantages: Light and other visual stimuli will not penetrate water very far and no data are available on effectiveness. Similarly responses to bubble curtains and booms are not quantified.

ii. Longer-range techniques

1. Acoustic Harassment Devices (AHDs): AHDs produce noise loud enough that they are likely to cause pain in animals at a certain range (ADDs are not loud enough to cause pain, but can be heard). Airmar AHDs have a source level of 195 dB re 1 μPa_{RMS} and their peak energy at 10 kHz with higher harmonics. These are used at the Ballard Locks and they could be moved at low speed from small boats or could be hull mounted on boats to allow faster movement. They are designed with 4 transducers that alternate transmission. They can be battery operated, but need a continuous power source for long-term use.

   - Advantages: It would not take long to train people to use them. They may deter killer whales up to 3 km away. This would be publicly acceptable at long range because it is estimated that injury would not be likely at distances over 10 meters.

   - Disadvantages: The received levels needed to cause deterrence without acoustic trauma are unknown, however it is thought that killer whales react strongly at the 135 dB re 1 μPa_{RMS} received level. Additionally, it has been suggested that repeated exposures to AHD's in the same area could result in long-term displacement of killer whales from an area.

2. Air guns: This is a mechanical device that uses air that expands and contracts to give a strong pulse under water to map earthquake faults or for oil exploration. They are frequently used in arrays to give a higher source level. Depending on the size, the peak energy can be from 10 Hz to 1 kHz, but they produce broadband pulses with energy at frequencies ranging to over 100 kHz. The higher frequencies are less intense and attenuate faster. Intensity of output is controllable by the operator to account for distance from the subject.

   - Advantages: Harbor porpoise have been seen moving away from them at 70 km so they could have impacts at great distances.

- Disadvantages: Because mysticetes hear low frequencies better, there is more concern with their use around mysticetes than odontocetes. There are no data on effectiveness in deterring killer whales. These are generally a towed array that is deployed behind a ship like the University of Washington's *R/V Thomas Thompson* so securing a ship to tow the array could be an issue. Use of a single gun would not pose this problem. There is concern about acoustic impacts to killer whales and other species including fish.

3. Mid-frequency sonar: This has caused behavioral changes in killer whales in Haro Strait during the *USS Shoup* transit episode in 2003. The source level was approximately 235 dB (exact level is classified) and frequency was 2.6-3.3 kHz over 1-2 second signals emitted every 28 seconds.

    - Advantages: Mid-frequency sonar could be effective for over 25 km, which could be useful in a large spill and it can be operated at night.

    - Disadvantages: Received levels that were effective in causing a response during the USS *Shoup* incident are unknown. There are a very limited number of boats that have the capability to deploy this sonar and they are engaged in national security missions. Concerns with using sonar include the potential for acoustic trauma in killer whales and other marine mammals and a lower level of public acceptance as a deterrent device. Difficulty in limiting range makes this technique excessive for a small spill.

iii. Further Information: This information was gathered at a meeting jointly hosted by NOAA/NMFS, Northwest Region and the SeaDoc Society, a program of the UC Davis Wildlife Health Center, School of Veterinary Medicine. Detailed meeting notes including literature cited are available at: http://www.vetmed.ucdavis.edu/whc/seadoc/pdfs/kw_mtg_notes_oct07.pdf

Appendix E: Selected MMHSRP Protocols

Disentanglement

E-2: Large Whale Disentanglement Network Advancement Policies

Procedure for Consideration for Network Members for Advancement with the Network

*NOTE: All correspondence and advancement consideration materials listed below should be with or provided to the NOAA Fisheries East Coast Disentanglement Coordinator unless directed otherwise

I. Identification for consideration for promotion by the following means:
    a. Self nomination
    b. NOAA-identified nomination (based on the responder acquiring additional experience or training since last consideration)
    c. Third party nomination (*i.e.* PCCS staff nominates a Network responder)

II. Preparation of responder experience resume highlighting disentanglement experience (including support roles) and training, vessel operations around whales, whale research and any other pertinent information to the review panel
    a. This step is completed by the responder wishing to be considered for promotion consideration, in conjunction with other higher-level Network responders assisting the Network member, or nominator.
    b. It is highly recommended that the experience resume includes representative images and short video clips depicting the Network member's involvement in disentanglement responses and/or pertinent whale research, etc.

III. Internal review by the NOAA Fisheries East Coast Disentanglement Coordinator of experience files and documentation submitted for each responder to ensure adequate documentation was provided to proceed to the full review panel

IV. NOAA Fisheries and a panel of approximately 5 anonymous external Level 4 and/or 5 reviewers (see below for differences) are authorized to review supporting documents and video.

    a. For Level 4 candidates:
        i. The anonymous review panel is composed of internal NOAA Fisheries representatives from the NER and SER and a panel of at most 5 anonymous external Level 4 and Level 5 reviewers. Each panelist is required to share with the other panelists and NOAA Fisheries staff their thoughts on the skills, abilities and qualifications of each responder being considered as it relates to the skills, experience and other criterion identified for a Network Level 4 responder (see Appendix 1). Each panelist is then requested to provide a private, confidential email to the NOAA Fisheries East Coast Disentanglement Coordinator with their recommendation to advance or not and a brief description of their rationale behind that decision.
    b. For Level 5 candidates:
        i. The anonymous review panel is composed of internal NOAA Fisheries representatives and a panel of at most 5 anonymous external Level 5

reviewers. Each panelist is required to share with the other panelists and NOAA Fisheries staff their thoughts on the skills, abilities and qualifications of each responder being considered as it relates to the skills, experience and other criterion identified for a Network Level 5 responder (see Appendix 1). Each panelist is then requested to provide a private, confidential email to the NOAA Fisheries East Coast Disentanglement Coordinator with their recommendation to advance or not and a brief description of their rationale behind that decision.

V. NOAA Fisheries reconvenes the internal panel to tally the recommendations and based on the majority vote, including NOAA Fisheries staff recommendations, the preferred outcome for the advancement or not of the responder being considered is selected. If there is a tie or disagreement, the permit holder, Teri Rowles, or her designee, has the final decision-making authority for the advancement. Once the recommendations are finalized, they are submitted to the permitting office for advancement.

VI. Responders are contacted to advise of the outcome of the advancement consideration and any status change.

Appendix 1. Criterion for Level 4 and 5 Network Responders

<u>Level 4 Responder responsibilities and criteria (taken from permit language)</u>

Targeted Individuals: Current Network Level 3 responders

Responsibilities

Level 4 activities

- Report, stand by, assess, document, attach a telemetry buoy, consult on an action plan and lead a disentanglement on all large whales except right whales.
  - Report, stand by, assess, document, participate with a Level 5 responder and attach a telemetry buoy to right whales

-on a case by case basis and after consultation, certain cuts on known entangled right whales may be permitted at level 4 ***if the proposed action is first approved by level 5 disentanglers and NMFS.***

- Train, evaluate and promote candidates for Level 1-3 under approved training methods.

Please Note: Entangled whale behavior varies considerably by species. However, Level 4 Disentanglers should routinely be able to lead a disentanglement of all large whales other than right whales.

Criteria for certification

Basic or Advanced Level 3 Certification and:

· Direct experience in a supervised (by PCCS/Network coordinators or NOAA Fisheries) large whale disentanglement, documentation of that experience, and a positive evaluation from NOAA Fisheries using information provided by PCCS/Network Coordinators and any hard documentation (i.e. video)

· When possible, commitment to consultation as detailed in Level 5 requirements.

<u>Level 5 Responder responsibilities and criteria (taken from permit language)</u>

Targeted Individuals: Current Network Level 4 responders

Responsibilities

Level 5 activities

- Report, stand by, assess, document, attach a telemetry buoy, consult on or assist in developing an action plan and lead a disentanglement of all large whales including right whales

Please Note: Right whales have exhibited aggressive behavior and therefore generally considered the most difficult whales to disentangle. North Atlantic right whales are among the most critically endangered large whales in the world. Certification at this level is highly selective and specialized.

Criteria for certification

Advanced Level 4 Certification and:

- Experience w/ right whale behavior and/or includes a person on the team directly involved in the whale disentanglement (in the boat working directly with the whale) that is experienced in right whale behavior
- Documented participation in a right whale disentanglement and NMFS/Advanced Network Responder review of video of participation in a right whale disentanglement that followed NMFS protocols

Commitment to Consultation to Include:

- Immediate Consultation: When possible, use satellite/cell phone to bring in additional ideas/experience from other Level 5's (and veterinarians and behaviorists if appropriate) while on scene with an entangled right whale
- Action Plan Development: For a tagged right whale, consultation is required with NMFS, Level 5's (and 4's if appropriate), veterinarians, behaviorists, etc.

Rationale for consultation: First assessments and strategies almost invariably change with more discussion or information. Consultation will likely help to increase human safety and critical choices regarding risks to whale health must be made with the best available information.

Appendix E: Selected MMHSRP Protocols

Disentanglement

E-3: Alaska Department of Fish & Game Steller Sea Lion Disentanglement Response Protocol

Response Protocol and GO/NO-GO criteria

12 March 2013 – michael.rehberg@alaska.gov

Because disentanglement of Steller sea lions is a new technique we expect modifications will be needed as we gain experience.

Selection criteria – GO / NO-GO

ADF&G will assess the following criteria when determining whether to attempt disentanglement of Steller sea lions:

1. Is the entanglement caused by anthropogenic marine debris?
2. Will the entanglement cause adverse effect upon the animal without human intervention?
3. Is the location safely accessible for responders?
    a. Will large groups of spectators be drawn to the area?
    b. Will response interfere with Alaska Native subsistence hunts?
    c. Will response interfere with local fisheries or tourism?
4. Is the entangled animal alone or located favorably among non-target animals?
    a. Will response cause disturbance of mother-pup pairs <2 months old?
    b. Will large numbers of older pup (>2 months)/mother pairs be disturbed?
5. Can the animal be approached from a concealed location at an appropriate distance?
    a. Are wind speed and direction favorable for stealthy approach and accurate darting?
6. Will large numbers of animals be disturbed? If so, can they exit safely?
    a. Are there cliffs, pools, or obstructions to consider before approaching?
9. Are transient killer whales present?
10. Do predicted weather and ocean conditions favor safety?
11. Are sufficient qualified responders available?

Procedure to minimize disturbance

Because Steller sea lions are gregarious, social animals that haul out in large numbers, it will rarely be possible to capture and disentangle an individual without causing incidental harassment of other sea lions. The following protocol for approaching occupied rookeries and haulouts is adapted from our *NMFS Research Permit No. 14325* and *ADF&G IACUC Protocol #09-27R*:

- Disentanglement will not be attempted in locations within breeding rookeries that are likely to disturb mother/pup pairs.

- Initial survey of the scene and identification of target entangled individual will be made by skiff, first passing carefully far offshore to judge wariness of the hauled out sea lions, later passing closer if needed to better judge the scene.
- Approach to the haulout will be made by skiff from the most practical concealed direction.
- A small darting team will be landed at this location and stalk carefully, wearing camouflaging clothes and using natural cover, to within 5-20 m of the subject animal.
- After subject animal is successfully immobilized, the remainder of the team will join the darting team. In our experience, at haulouts consisting of a single, continuous slab or small area this will likely flush all animals. On haulouts broken up by terrain or water, this will likely flush animals from the local area with sea lions in other locations more likely to remain hauled out.
- Prior to darting or restraint of target animal, personnel will cease efforts if significant injury to target or non-target animals appears imminent.
- Count estimates of incidental harassment takes will be recorded at the time of disturbance and reported to NMFS.

Capture

Sea lions will be captured under the direction of a qualified veterinarian through the use of drugs delivered by propelled darts. On land, the darting team will identify the entangled individual and ensure it is not too close to the ocean shoreline or pools of standing water. The darting team will select a position 5-20 m from the target animal. This close range permits relatively low impact velocities thus reducing the startle effect of darting, facilitates more accurate animal mass estimates and allows quicker access to the animal once induction has occurred. The dart will be delivered by rifle (such as those manufactured by *Dan-Inject*) and inject drugs IM, preferentially over the hips and tibia lumbar muscle or into the muscle over the shoulders. Drug combinations (for details see *Attachment 1*) will be selected at the discretion of the attending veterinarian or trained ADF&G biologist. Dosages are based on visual estimates of body mass. We do not anticipate subsequently placing target animals under gas anesthesia because we expect the disentanglement process will be rapid. The majority of drugs used in these combinations are considered reversible, and loaded darts will be ready to reverse the target sea lion after processing is complete or in the event induction of the target sea lion is incomplete and it moves out of our reach.

In situations where manual capture and restraint is indicated (*e.g.*, small young-of-year pups), we will capture sea lions using hand-held nets if possible and conditions warrant.

Impede or restrain conscious animals

The drug combination and protocol currently in use has been demonstrated to permit sea lions that inadvertently enter the water prior to induction to safely remain at the surface, breathe and recover spontaneously. However, sea lions that evade capture prior to full induction and enter the water also cannot be approached for disentanglement. Thus it may be necessary to physically restrict the entangled animal's access to water prior to immobilization drugs being administered or while waiting for their full effect.

Prior to darting, co-investigators will determine the path the entangled sea lion will most likely take if startled by darting. If safe and practical without causing excessive disturbance to non-target animals, personnel may be placed between the entangled sea lion and its avenue of escape before, during, or after darting. In our experience, sea lion movements can be influenced or directed by human presence. Personnel may use visual deterrents (*e.g.,* plywood, poles, etc.) or temporary restraint (*e.g.*, nets) to encourage the entangled animal to remain on, or return to, shore until induction and subsequent removal of entanglement.

Disentanglement, treatment, sampling, measurement and marking

Entanglements will be removed by lifting the material off the animal if possible and by cutting with clean instruments if necessary. Ingested line will be cut to remove external trailing line, flashers or other objects. Biologists will assess the risk of disentanglement attempts against the benefit of disentangling each individual, and it is possible that we may abandon disentanglement attempts that, in our judgment, cannot be completed safely for staff or for the target animal. Because disentanglement of Steller sea lions is a new technique, we will modify our procedure as we gain experience. That said, we have observed and photographed hundreds of entangled sea lions and have a good understanding of the type and severity of entanglements we are likely to encounter, which will inform our decisions on scene.

Any sampling, measurement, marking or tracking done under this permit shall be strictly incidental to disentanglement attempts. Previously unbranded sea lions will receive temporary dye, cattle marker, hair clipping or similar markings on the fur to permit short-term resights. Where practical, unbranded sea lions will receive numbered flipper tags to permit long-term resights. The outcomes of marked, disentangled sea lions will be monitored during the regular ADF&G mark-resight program.

Provided satellite tracking tags are available, practical and safe to attach to disentangled individuals, we may affix satellite tags to the head or dorsal fur using epoxy following ADF&G sea lion tagging protocol.

The attending veterinarian may, at his or her discretion, provide additional treatment to captured sea lions. This may include, but not be limited to, injectable antibiotics, wound care and similar procedures.

Release

After handling, sea lions will be released to their natural habitat. Any confinement of sea lions or transport away from the capture site will be temporary. We will not transport entangled or disentangled sea lions for rehabilitation.

Emergency euthanasia

We are authorized for emergency euthanasia only. It is not our intent to identify free-ranging individuals for the purpose of selecting euthanasia candidates. Euthanasia shall be performed by the attending veterinarian or an ADF&G biologist acting under the direction of the veterinarian and follow the procedures outlined in our *ADF&G IACUC Assurance of Animal Care (# 09-27R)* and ADF&G memo *Veterinary prescribed procedures for field euthanasia of Steller sea lions* (12 February 2009). A complete necropsy will be performed on any euthanized animal.

Monitoring outcomes

Personnel will monitor sites to the extent practical without causing disturbance to determine if target animal has recovered, assess disturbance caused during the response and identify any potential incidental injury or observable abandonment. Steller sea lion researchers and cooperators will be notified that a disentangled individual has been released along with identifying information. We will request any sightings, including photographs, be forwarded to ADF&G. ADF&G will watch for disentangled individuals during our annual mark-resight program, which includes a standard summer range-wide survey and smaller, local surveys within southeastern Alaska and Prince William Sound during other times of the year. These surveys monitor survival, reproduction and entanglement of individual sea lions. We have staff and skiffs stationed in Juneau, Haines and Anchorage from which it is possible to investigate local sightings of disentangled individuals.

Reporting

ADF&G will provide to NMFS a report of each disentanglement attempt, including:

- Summary of direct and incidental take
- Narrative description of the attempt and lessons learned
- Location, sex, age and identifying features of the captured sea lion
- Summary of measurements and sampling made, including disposition of any samples taken

Incidental injury beyond minor skin scrapes and any mortalities will be reported to NMFS OPR as soon as possible.

Media contacts will be coordinated with ADF&G, the MMHSRP and NMFS Office of Public Affairs (*via* NMFS Alaska Region).

Appendix E: Selected MMHSRP Protocols

Diagnostic Imaging

E-4: Monk seal Radiography Safety Requirements and Protocol

Safety Requirements and Protocol for Radiography (X-ray) of Hawaiian monk seals

Radiation Safety

- All persons not needed for restraint or equipment operation should move **at least 6 feet** away from the beam during imaging.
- All persons essential for animal restraint or equipment operation must wear protective aprons and thyroid guards during imaging. This protection is absolutely is **required**.
- No person should *ever* place a body part in the direct line of the x-ray beam, *even* if protective attire is worn.
- Whenever possible but at veterinary discretion, sedation or anesthesia should be used to reduce the need for animal restraint during imaging.
- Every effort should be made to keep the number of radiographs taken to a reasonable but minimal level to reduce exposure for animals and staff. Be sure to double check positioning before shooting to reduce the need for duplicate exposures.
- In general, selecting a higher Kvp with an appropriate reduction in mAs can result in a reduced radiation dose.
- Dosimetry badges (small badges worn during imaging that track cumulative radiation dose and must be specific to each individual) are highly recommended and should be checked annually.
    - Wear only your own badge
    - Store it in a cool, dry place away from radiation when not in use
    - Do not take your badge home.
    - Do not launder the badge or get it wet.
    - Do not expose to heat, such as in a car in summer.

Radiograph Sampling

Select text below copied from "Description of Radiograph Sampling" for NMFS Permit 932-1905

Radiography (x-rays) may be conducted on animals captured during emergency response, animals undergoing rehabilitation; or, on any species in the wild, in rehabilitation, or in captivity during research studies. Animals of any age/sex could be radiographed, including pregnant females*, at veterinary discretion.

Radiographic methods used on Hawaiian monk seals include standard digital radiographs. Other radiographic methods (e.g., computed tomography (CT) magnetic resonance imaging (MRI)) are uncommonly used in monk seals and are not addressed in this protocol.

Standard radiographs may be used for a variety of reasons including, but not limited to, assessment of: entanglements, ingested foreign objects (e.g., hooks), wounds, lesions, detection of wounds/lesions/infection, pregnancy, and evaluation of cardiac function and other internal organs.

A dedicated digital, portable field x-ray unit is available exclusively for Hawaiian monk seal use in Hawaii. This unit is owned by The Marine Mammal Center. It typically resides on Oahu and is housed at the NOAA IRC so that it is available for emergency use by first responders. However,

when there are seal patients at TMMC's Ke Kai Ola facility in Kona, Hawaii, the unit will be housed in that location so that it is available in an emergency should one arise with seals in rehabilitation.

Chapter 25 of the *CRC Handbook of Marine Mammal Medicine* will be used as a reference for equipment and methods of radiography for marine mammals (Van Bonn et al. 2001). This reference is available in Michelle's office.

Sedation and/or general anesthesia may be necessary for the comfort of the animal and to limit movement; or, imaging may be conducted concurrently with other scheduled medical procedures requiring sedation or anesthesia. The level of sedation/restraint is at the discretion of the attending veterinarian and should consider animal size, sex and capacity of personnel on site. Animals will be monitored by veterinary staff during the procedure. Based upon the radiographic findings the animals may be admitted to rehabilitation or treated and released in the field.

Radiography may be used on carcasses at any time and at a minimum, its use is strongly encouraged for continuing practice with the equipment.

Only qualified veterinarians or other personnel with sufficient experience in the technique will be allowed to perform these procedures. Trained and experienced animal handlers would conduct capture and restraint activities. Care will be taken to minimize any impacts from capture and restraint. The attending veterinarian will sedate or anesthetize pinnipeds and cetaceans if deemed necessary to reduce stress and ensure the safety and welfare of the animal. Appropriate measures will be taken to mitigate any deleterious impacts of sedation/anesthesia if needed. Animals will be monitored for hyper and hypothermia and appropriate measures will be taken to mitigate either condition. Radiographic procedures will be discontinued if animals exhibit excessive stress, pain, or suffering during the procedure.

*There is little risk to the fetus when radiographing pregnant animals (Toppenberg et al. 1999; http://www.aafp.org/afp/990401ap/990401b.html). The accepted cumulative dose of ionizing radiation during pregnancy is 5 rad, and no single diagnostic study exceeds this maximum. For example, a fetus would receive a dose of 0.00007 rad from a two-view chest x-ray of a human mother (Toppenberg et al. 1999). Radiographs are often used in small animal practices to diagnose and stage pregnancies.

References

Toppenberg, K.S., D.A. Hill, and D.P. Miller. 1999. Safety of Radiographic Imaging During Pregnancy. *Am Fam Physician*. 59(7):1813-1818.

Van Bonn, W., E.D. Jensen, and F. Brook. 2001. Radiology, computed tomography and magnetic resonance imaging. In: *CRC Handbook of Marine Mammal Medicine*, Second Edition. L.A. Dierauf and F.M.D. Gulland, eds. CRC Press LLC, Boca Raton, FL, pp. 557-591.

Appendix E: Selected MMHSRP Protocols

Sample Collection and Analysis

E-5: Marine Mammal Necropsy: An introductory guide for stranding responders and field biologists (available at: http://hdl.handle.net/1912/1823)

WHOI-2007-06

Woods Hole Oceanographic Institution

Marine Mammal Necropsy:
An introductory guide for stranding responders and field biologists

by

Katie R. Pugliares[1]

Andrea Bogomolni[2]

Kathleen M. Touhey[1]

Sarah M. Herzig[1]

Charles T. Harry[1]

Michael J. Moore[2]

[1]The Cape Cod Stranding Network, Inc
P.O. Box 287
Buzzard's Bay, MA 02532
508-743-9805

[2]Woods Hole Oceanographic Institution
Biology Department
Woods Hole, MA 02543
508-289-3228

September 2007

Technical Report

Funding was provided by the National Oceanic and Atmospheric Administration
under Cooperative Grant No. NA05NMF4391165.

Approved for public release; distribution unlimited.

WHOI-2007-06

Marine Mammal Necropsy:
An introductory guide for stranding responders and field biologists

by

Katie R. Pugliares, Andrea Bogomolni, Kathleen M. Touhey, Sarah M. Herzig,
Charles T. Harry, and Michael J. Moore

August 2007

Technical Report

Funding was provided by the National Oceanic and Atmospheric Administration under Cooperative Grant No. NA05NMF4391165.

Reproduction in whole or in part is permitted for any purpose of the United States Government. This report should be cited as Woods Hole Oceanog. Inst. Tech. Rept., WHOI-2007-06.

Approved for public release; distribution unlimited.

Approved for Distribution:

Judith C. McDowell

Judith McDowell, Chair

Department of Biology

This page intentionally left blank.

TABLE OF CONTENTS

ACKNOWLEDGEMENTS……..…….……. 11

SECTION ONE: INTRODUCTION AND PRELIMINARY DATA…….…... 13
INTRODUCTION…….…… 13
SAFETY……..……... 14
PRELIMINARY DATA…… 14
ANIMAL HISTORY……. 14
HUMAN INTERACTION EVALUATION……. 15
MORPHOMETRICS…….…… 17
PHOTOGRAPHY……. 19

SECTION TWO: SAMPLE MANAGEMENT……..…….. 21
HISTOPATHOLOGY…….…….. 21
CYTOLOGY……. 22
VIROLOGY…….. 22
MICROBIOLOGY……... 23
PARASITOLOGY……... 23
CONTAMINANTS……... 23
BIOTOXINS……. 24
LIFE HISTORY AND GENETICS…….. 24
STORAGE……. 25
TRACKING…….. 27

SECTION THREE: PINNIPED NECROPSY TECHNIQUE AND ANATOMY……. 29
EXTERNAL EXAMINATION...…….. 29
CONDTION CODE…….. 29
NUTRITIONAL CONDITION……. 30
SEX DETERMINATION…….. 31
INTEGUMENT……. 32
SKIN & TEETH SAMPLING…….. 33
REMOVAL OF EXTERNAL LAYERS……... 34
SKIN & BLUBBER……... 34
SKELETAL MUSCLE…….. 34
INTERNAL EXAMINATION...…….. 35
SCAPULA AND PRESCAPULAR LYMPH NODE……... 35
THYROID…….. 36
THYMUS……... 37
REMOVAL OF RIB CAGE…….. 37
TRACHEOBRONCHIAL LYMPH NODE…….. 39
LUNGS…….. 40
TRACHEA……. 41
HEART MUSCLE & VALVES…… 41
DIAPHRAGM……... 43
LIVER……...……. 43

TABLE OF CONTENTS (cont.)

GALL BLADDER…… 43
SPLEEN…… 44
PANCREAS…….... 45
MESENTERY & MESENTERIC LYMPH NODE…….. 45
ADRENAL GLANDS……... 46
KIDNEYS…….. 47
URINARY BLADDER……. 47
OVARIES & UTERUS……..…… 48
TESTES……. 48
STOMACH…… 49
ESOPHAGUS…… 50
SMALL INTESTINE……. 50
LARGE INTESTINE……. 50
COLON…….. 50
REMOVAL OF THE BRAIN……... 51
EXAMINATION OF THE BRAIN……... 52
PITUITARY GLAND……... 52

SECTION FOUR: SMALL CETACEAN NECROPSY TECHNIQUE AND ANATOMY …… 53
EXTERNAL EXAMINATION...…….. 53
CONDTION CODE……... 53
NUTRITIONAL CONDITION……. 55
SEX DETERMINATION…….. 55
INTEGUMENT……. 57
SKIN & TEETH SAMPLING……... 59
REMOVAL OF EXTERNAL LAYERS……... 60
SKIN & BLUBBER……... 60
SKELETAL MUSCLE…….. 63
INTERNAL EXAMINATION…….. 63
SCAPULA AND PRESCAPULAR LYMPH NODE……... 63
REMOVAL OF RIB CAGE…….. 64
THYROID…….. 66
THYMUS……... 66
TRACHEOBRONCHIAL LYMPH NODE…….. 66
LUNGS…….. 67
TRACHEA……. 68
HEART MUSCLE & VALVES…… 69
DIAPHRAGM……... 71
LIVER…… 72
SPLEEN……. 73
PANCREAS……... 74
MESENTERY & MESENTERIC LYMPH NODE…….. 75
ADRENAL GLANDS……... 76

TABLE OF CONTENTS (cont.)

KIDNEYS…….. 77
URINARY BLADDER……. 79
OVARIES & UTERUS……. 80
TESTES & PENIS……. 82
STOMACH…… 83
ESOPHAGUS…… 85
SMALL INTESTINE……. 86
LARGE INTESTINE……. 86
COLON…….. 86
REMOVAL OF THE BRAIN……... 87
EXAMINATION OF THE BRAIN……... 88
PITUITARY GLAND……... 89
EAR EXTRACTION……. 89

SECTION FIVE: LARGE WHALE EXAMINATION AND NECROPSY …..……..…… 91
ON-SHORE NECROPSY……. 91
PLANNING & LOGISTICS……...……... 91
NECROPSY SITE LOCATION…..……...……... 91
DISPOSAL…….……... 91
TEAM MEMBER ROLES...……. 92
FLOATING CARCASS.……... 93
RELOCATION…….……. 94
TOWING……...…… 94
LANDING….…… 95
NECROPSY……...…… 95
CASE HISTORY……... 96
SITE SAFETY……... 96
EXTERNAL EXAMINATION……. 96
INTERNAL GROSS EXAMINATION…….……... 96
AT SEA EXAMINATION…….……... 97
NECROPSY LOGISTICS……. 97
DOCUMENTATION…… 97
CREW…….……... 97
SAMPLING…….…….. 97

APPENDICES……...……... 101
APPENDIX A: Gross Necropsy Report……... 101
APPENDIX B: Guidelines to Writing a Gross Necropsy Report…… 108
APPENDIX C: Human Interaction Evaluation Form & Instructions…….. 110
APPENDIX D: Equipment Necessary for a Complete Necropsy on Pinnipeds and Small Cetaceans …….…….. 121
APPENDIX E: Pinniped Morphometric Data Record ……... 122
APPENDIX F: Cetacean Morphometric Data Record …… 123
APPENDIX G: Blank Photo ID Card…….……. 124
APPENDIX H: Necropsy Sample Collection Inventory ……. 125

TABLE OF CONTENTS (cont.)

GLOSSARY OF TERMS……..…….....……. 127

RESOURCES……...……..…….…….. 131

LIST OF FIGURES AND TABLES

SECTION ONE

Figure 1-1: Incisions for blubber thickness…….. 18
Figure 1-2: Incisions for blubber thickness……. 18
Figure 1-3: Blubber thickness measurement…… 18

SECTION TWO

Table 2-1: Samples to collect according to decomposition code……. 21
Figure 2-1: Single tissue bagging and tagging……. 26
Figure 2-2: Multiple tissue bagging and tagging……. 27

SECTION THREE

Figure 3-1: Fresh pinniped carcass…….. 29
Figure 3-2: Moderately decomposed pinniped carcass…… 29
Figure 3-3: Advanced decomposition of a pinniped carcass……... 30
Figure 3-4: Mummified or skeletal remains of a pinniped carcass…….. 30
Figure 3-5: Robust pinniped…… 30
Figure 3-6: Emaciated pinniped……... 30
Figure 3-7: Male pinniped external ID…… 31
Figure 3-8: Female pinniped external ID……. 31
Figure 3-9: Fungal dermatitis with alopecia…… 32
Figure 3-10: Fungal dermatitis……. 32
Figure 3-11: Chronic dermal ulcer……... 33
Figure 3-12: Removal of lower left jaw……... 33
Figure 3-13: Removal of lower left jaw……... 33
Figure 3-14: Removal of lower left jaw……... 33
Figure 3-15: Removal of skin and blubber…….. 34
Figure 3-16: Reflection of blubber along the fascial plane…….. 34
Figure 3-17: Reflection of blubber along the fascial plane…….. 35
Figure 3-18: Normal blubber……... 35
Figure 3-19: Panniculitis…….. 35
Figure 3-20: Location of the prescapular lymph node in situ…….. 36
Figure 3-21: Normal lymph node……. 36
Figure 3-22: Lymphoid hyperplasia……. 36
Figure 3-23: Location of thyroid…….. 37
Figure 3-24: Normal thyroid with parathyroid…… 37
Figure 3-25: Lateral rib cage articulation…… 38
Figure 3-26: First view of exposed body cavity…….. 38
Figure 3-27: Location of the tracheobronchial lymph node…… 39
Figure 3-28: Lymphoid hyperplasia……. 39
Figure 3-29: Lung…… 40
Figure 3-30: Interstitial pneumonia……. 40
Figure 3-31: Pulmonary edema…… 40
Figure 3-32: Pulmonary abscess…….. 41

LIST OF FIGURES AND TABLES (cont.)

SECTION THREE (cont.)

Figure 3-33: Lobar pneumonia…… 41
Figure 3-34: Lung worms……..…….. 41
Figure 3-35: Structures of the heart (external)……. 42
Figure 3-36: Suggested pathway to open heart…… 42
Figure 3-37: Liver with intact gallbladder……... 43
Figure 3-38: Liver, stomach, spleen in situ…….. 44
Figure 3-39: Icterus or fatty change of the liver…….. 44
Figure 3-40: Spleen…….. 44
Figure 3-41: Mesentery and mesenteric lymph node……... 45
Figure 3-42: Reactive mesenteric lymph node…… 46
Figure 3-43: Location of the adrenal gland and kidney in situ…… 46
Figure 3-44: Normal adrenal glands…… 46
Figure 3-45: Reniculi……... 47
Figure 3-46: Location of urinary bladder in situ……. 47
Figure 3-47a: Stenosis of bladder…… 48
Figure 3-47b: Stenosis of bladder…… 48
Figure 3-48: Location of testes in situ……. 49
Figure 3-49: Normal testes……... 49
Figure 3-50: Stomach removed from cavity…… 49
Figure 3-51: Stomach mucosa……. 50
Figure 3-52: Separation of skull from atlas……. 51
Figure 3-53: Flensed skull…… 51
Figure 3-54: Exposed brain in skull……. 52
Figure 3-55: Brain hemorrhage…… 52

SECTION FOUR

Figure 4-1: Fresh cetacean carcass……... 53
Figure 4-2: Moderate decomposition of a cetacean carcass…… 54
Figure 4-3: Advanced decomposition of a cetacean carcass…… 54
Figure 4-4: Mummified or skeletal remains of a cetacean……... 54
Figure 4-5: Robust cetacean……. 55
Figure 4-6: Emaciated cetacean……... 55
Figure 4-7: Female delphinid……... 56
Figure 4-8: Male delphinid…….. 56
Figure 4-9: Fungal dermatitis……... 57
Figure 4-10: Lesions caused by a sea lamprey…… 57
Figure 4-11: Skin lesion……... 58
Figure 4-12: Tattoo lesion…… 58
Figure 4-13a: Dolphin pox……... 58
Figure 4-13a: Dolphin pox……... 58
Figure 4-14: Dermal papilloma…… 58
Figure 4-15: Skin sample……. 59
Figure 4-16: Removal of lower teeth……... 59
Figure 4-17: Removal of lower teeth……... 59

LIST OF FIGURES AND TABLES (cont.)

CHAPTER FOUR (cont.)

Figure 4-18: Removal of lower teeth……... 59
Figure 4-19: Multiple full blubber thickness incisions…… 60
Figure 4-20: Reflection of blubber along the fascial plane…….. 60
Figure 4-21: Reflection of blubber along the fascial plane…….. 60
Figure 4-22: Panels of blubber reflected away from carcass……... 61
Figure 4-23: Separation of skin from blubber…….. 61
Figure 4-24: *Phyllobothrium* sp. ……. 61
Figure 4-25: *Crassicauda* sp. …….. 61
Figure 4-26: *Monorygma* sp……. 62
Figure 4-27: Bubbles within the blubber/muscle fascia……... 62
Figure 4-28: Focal abscessation……... 62
Figure 4-29: Removal of the epaxial muscle mass…….. 63
Figure 4-30: Location of the prescapular lymph node in situ…….. 63
Figure 4-31: Removal of the scapula……... 63
Figure 4-32: Costal rib articulation…….. 64
Figure 4-33: Removal of ribs at the sternum articulation…… 64
Figure 4-34: Double-articulated rib……. 65
Figure 4-35: Viscera with the ribs removed……. 65
Figure 4-36: Location of the tracheobronchial lymph node…… 66
Figure 4-37: Lung removed from carcass…… 67
Figure 4-38: Lymphosarcoma—lung……... 67
Figure 4-39: Pleural fibrosis—lung……. 67
Figure 4-40: Aspergilloma—lung…… 68
Figure 4-41: Parasitic cyst—lung…… 68
Figure 4-42: Pulmonary abscess…….. 68
Figure 4-43: Pulmonary hemorrhage……... 68
Figure 4-44: External structure of the heart……. 69
Figure 4-45: Suggested pathway to open the heart…….. 69
Figure 4-46: Endocardium……... 70
Figure 4-47: Normal A-V valves…… 70
Figure 4-48: Valvular Endocardiosis……. 70
Figure 4-49: Fibrosis; arteriosclerosis; mineralization…… 71
Figure 4-50: Abdominal viscera in situ……... 71
Figure 4-51: Liver in situ……. 72
Figure 4-52: Fibrin tag……. 72
Figure 4-53: Lymphosarcoma—liver……... 72
Figure 4-54: Liver flukes……. 73
Figure 4-55: Location of spleen……... 73
Figure 4-56: Multifocal granulomas—spleen…….. 74
Figure 4-57: Normal spleen……. 74
Figure 4-58: Location of the pancreas……. 74
Figure 4-59: Normal pancreas…….. 75
Figure 4-60: Intraductal trematodes……. 75

LIST OF FIGURES AND TABLES (cont.)

CHAPTER FOUR (cont.)

Figure 4-61: Mesentery…… 75
Figure 4-62: Lymphosarcoma—mesentery……. 76
Figure 4-63: Lymphadentitis—mesenteric lymph node…….. 76
Figure 4-64: Follicular hyperplasia—mesenteric lymph node…… 76
Figure 4-65: Location of adrenal gland……. 77
Figure 4-66: Cortico-medullary adrenal hemorrhage…….. 77
Figure 4-67: Reniculi……... 78
Figure 4-68: Adrenomegaly……. 78
Figure 4-69: Renal lymphosarcoma……. 78
Figure 4-70: Inter-lobular renal fat; or steatosis—kidney……... 79
Figure 4-71: Bubbles within the renal capsule……. 79
Figure 4-72: Location of urinary blubber…… 79
Figure 4-73: Female reproductive tract…… 80
Figure 4-74: Stigma on ovary…….. 81
Figure 4-75: Corpus luteum hemorrhage……. 81
Figure 4-76: Ovarian cyst…… 81
Figure 4-77: Capsular fibrosis……. 81
Figure 4-78: Location of testes…… 82
Figure 4-79: Normal, immature testes……. 82
Figure 4-80: Cross section of the vas deferens…… 82
Figure 4-81: *Monorygma* sp……. 83
Figure 4-82: *Monorygma* sp……. 83
Figure 4-83: Stomach removed from carcass…….. 84
Figure 4-84: Fore stomach mucosa…….. 84
Figure 4-85: Main stomach mucosa……. 84
Figure 4-86: Adhesions of the omentum…….. 85
Figure 4-87: Lymphosarcoma—gastric……... 85
Figure 4-88: Stomach ulcer…….. 85
Figure 4-89: Stomach ulcer…….. 85
Figure 4-90: Intestine mucosa…….. 86
Figure 4-91: *Acanthocephalans* sp……... 86
Figure 4-92: Skull cap removed to expose brain tissue……... 87
Figure 4-93: Brain removed from skull……... 88
Figure 4-94: Internal structures of the brain…… 88
Figure 4-95: Parasitic abscess—brain…….. 88
Figure 4-96: Necrotizing encephalitis…….. 89
Figure 4-97: Meningoencephalitis and hemorrhage…… 89

SECTION FIVE

Figure 5-1: Line impressions around peduncle…… 94
Figure 5-2: Towing bridle…… 95
Figure 5-3: Heavy equipment on the beach……. 95

Acknowledgements:

We would like to thank the NOAA Prescott Program for support to do this work, and the CCSN volunteers who assisted though the many hours of necropsies, especially Joy Marzolf and Aelaria Rupploa (IFAW) for their photography expertise during such necropsies. A major thank you to Sue Barco and staff from the Virginia Aquarium Stranding Program, Greg Early of Mote Marine Laboratory, Steven Raverty from the Department of Fisheries and Oceans in Canada, David Rotstein from the University of Tennessee and Judy St Leger of Sea World, San Diego for their constructive edits on earlier versions of this manual.

This page intentionally left blank.

- SECTION ONE -
Introduction and Preliminary Data

Introduction

Necropsies are performed to get further insight into the cause of death: in the case of marine mammals this may establish the cause for stranding or other mortalities. The necropsy generates a series of gross observations that establishes a differential diagnosis. Subsequent investigations, such as histopathology, are then guided as the various potential diagnoses are eliminated until an etiology is established. Regardless of whether it is a common chronic disease, fisheries interaction, or an emerging zoonoses, by consistently conducting necropsies, trends in population health can be monitored.

This guide is designed to establish a base level of proficiency in marine mammal necropsy techniques. It is written for stranding network members who do not have a formal pathobiological training and have limited knowledge of anatomy. Anatomical and pathological jargon has been kept to a minimum.

This manual is divided into six sections: preliminary data, sample management, pinniped, small cetacean, large whale (at sea and on the beach), and multiple appendices (A-H). A well-illustrated, carefully written gross necropsy report is essential to an adequate diagnostic investigation. Gross reports with significant detail and description tend to engender useful histopathological findings. A sample blank gross necropsy report and guidelines in writing a report can be found in Appendices A & B.

Overall, this guide aims to lead the enquiring mind through the necessary steps to produce such reports. While this manual focuses on process and interpretation, it is important to understand that the gross necropsy is primarily about making detailed, descriptive observations without bias as to possible etiology. The necropsy should establish a list of differential diagnoses and the sampling be directed by an attempt to discriminate between them.

Throughout this manual there are images of both normal and abnormal tissues documented in cases of stranded marine mammals on Cape Cod, Massachusetts. These images serve to give the beginner an example of what normal and abnormal may look like. We do not encourage the prosector to utilize these photos as a way to identify a specific pathology. The most important part of a necropsy is to accurately describe what you see as you see it. If experience has allowed one to recognize specific conditions, this information may be added to the report **following** the initial gross description.

Note: To avoid confusion regarding the asymmetry of marine mammals, photos have not been arranged in the conventional manner with the cranial aspect to the left. Images are inserted into this manual as they were originally taken. Also, many of the images have been cropped for clarity, at times hiding the sample identification tag that should be included in every image.

A gross description and morphologic diagnosis and/or etiology are provided with the majority of gross images throughout this manual. The morphologic diagnosis reflects subsequent histological

observations where available which are designated with an asterisk. Where histology is not available for a particular gross lesion image, similar prior cases with histological analysis have been used to infer a morphologic diagnosis. In addition, many gross appearances and common pathologies are similar among marine mammal species and photos throughout this manual can be applied to all orders discussed.

This manual, although targeted for a US audience, has utility for any region of the world.

Safety

Harmful zoonotic organisms can be encountered within the carcasses of marine mammals, thus, personal and public safety precautions should be taken when handling dead marine mammals and tissues. Protective gear, such as disposable gloves, goggles, face masks, or splash shields should be worn to reduce the risk of contamination. All existing wounds should be well bandaged prior to beginning the necropsy and any injuries sustained during the necropsy should be thoroughly cleaned, bandaged and documented. Well stocked first aid kits should be on site at all times. If professional medical attention is required, be sure to inform the provider of your exposure to marine mammal diseases. Proper disposal receptacles for blades, knives, and needles as well as chemical spill treatment kits should be easily accessible. All chemicals should be handled in a well ventilated area. Exposed skin should be thoroughly scrubbed before leaving the lab or site. Equipment should be cleaned and disinfected. Disposal of the carcass should be well thought out as to not expose the general public to the potential hazards. Please refer to the Geraci and Lounsbury (2005) for proper disposal options.

Preliminary Data

Prior to commencement of a necropsy, all necessary equipment should be set up and accessible. A sample equipment list can be found in Appendix C of this guide.

Animal History

Strandings offer a unique opportunity to study marine mammals when observed and documented by bystanders and stranding network personnel. Knowledge of the animal's stranding history is helpful in evaluating the animal for evidence of human interaction and determining the cause and manner of death. It is imperative to remember that a thorough necropsy begins with the stranding event itself. Information that you should collect before the necropsy begins includes:

- Time and date of stranding. (Months are best written in words to avoid US/ European confusion of day and month)
- Environmental conditions prior to and at time of stranding
- Location of stranding, including GPS coordinates and topographic features
- Behavior prior to and during stranding
- Single or mass stranding (note single or multi-species)
- Time and date of death
- Euthanized or natural death
- If there is a current Unusual Mortality Event (UME) under investigation
- Mode of storage prior to necropsy*

Details of any rope or other gear or debris attached to the carcass during recovery, including gear no longer on the animal at time of collection/necropsy
Record of any trauma known to be inflicted (pre– or post mortem)

*If storage prior to necropsy is necessary, such as overnight, refrigerate the carcass as soon as possible. The carcass must be examined for evidence of human interaction and morphometric data collected before storage. Try to avoid freezing prior to necropsy, as this interferes with microscopic assessment of tissues.

Other information that may prove to be helpful is time lapse between first sighting and response as well as treatment or action plans undertaken during response. Also, request photo documentation taken by the first responder. These are often taken when a carcass is in better (fresher) condition than at the time of necropsy.

The life history stages of wild marine mammal populations have been a topic of focus for many marine mammal researchers. Age determinations for the two extreme stages, adulthood and neonate, are well understood, thus, estimations can be made for the various stages in between. Initial age classifications are based on total body length. Accurate classifications can be made through tooth (age), gonad (maturity) analyses, and, most recently, using amino acids in the lens of the eye. At the time of necropsy, the Cape Cod Stranding Network (CCSN) uses total body length to categorize both cetaceans and pinnipeds into the following categories: adult, juvenile, young of the year, and neonate. Please reference a marine mammal field guide for species-specific age estimations by length. Geraci and Lounsbury (2005) as well as Wynne and Shwartz (1999) have both proven to be helpful.

Human Interaction Evaluation

In the US, every stranded marine mammal is required to be examined thoroughly for evidence of human interaction. A complete guide to recognizing and documenting human interaction (HI) and an accompanying training program can be found in the *Handbook for Recognizing, Evaluating, and Documenting Human Interaction in Stranded Cetaceans and Pinnipeds (Barco and Touhey, 2007)*. Proper training is essential in conducting these examinations. The following general information is provided from the above mentioned handbook. Please see the reference material for data sheets, instructions, and complete training materials before conducting HI examinations. An additional HI Evaluation Form and complete instructions for filling out the form can be found in Appendix C of this manual.

Goals and objectives of the evaluation

The goal of the evaluation is to determine if signs of human interaction are present on the carcass. With proper training, the HI protocol can provide stranding network personnel with the tools needed to evaluate marine mammals for signs of human interaction (HI) and to collect HI data consistently in all regions of the United States. The protocol will yield two important pieces of information. The first is an objective evaluation of an animal or carcass that determines whether any signs of human interaction are present on the animal (regardless of whether they are pre- or postmortem, healed or recent). The second is a subjective finding in which the examiner uses all available information to evaluate the likelihood that any observed evidence of HI contributed to the stranding event.

Why evaluate stranded marine mammals for signs of human interaction?
When human interaction data are gathered objectively and consistently they can provide a solid scientific foundation for conservation and management measures. Documenting the types of interactions that take place and identifying the spatial and temporal patterns associated with the interactions can highlight resource use conflicts. With a better understanding of the interactions, appropriate measures can be taken to resolve conflicts. Furthermore, in the United States, the collection of human interaction data is mandated under the Marine Mammal Protection Act. The National Oceanic and Atmospheric Administration (NOAA) Fisheries Service requires that HI data be submitted with other basic information (such as species, stranding date and location, length, etc.) on each stranded animal.

Putting the data to use
Human interaction data are frequently and easily misinterpreted. In the United States, Level A Data, including human interaction findings, are collected from each stranded marine mammal. The Level A data sheet asks "Findings of human interaction?" with multiple choice answers of YES, NO, or CBD (Could not Be Determined). The federal instructions for the data sheet state that the question is designed to determine whether or not there are signs of interaction present on the animal. This does not necessarily mean the interaction caused the stranding or the death of the animal.

Tips for conducting an evaluation
- **Develop a routine** - follow it for every exam
- **Be conservative and objective**
- **Document everything**
  – Photograph (include tag & scale in every image)
  – Measure marks/lesions (all dimensions)
  – Sample (especially for histopathology)
  – Collect other evidence and maintain chain of custody
- **Interact with others** - share unusual cases and lesions with other stranding personnel, fishery managers, and veterinarians
- **Understand and acknowledge confounding variables** - decomposition, scavenger damage, sunburn, and logistics are all things that make HI evaluation difficult. Never be afraid to score something as CBD

The importance of being conservative
In addition to standardizing our protocols and maintaining objectivity when examining animals, it is essential to be conservative in our evaluations. Since these data may be used to generate policies and management strategies, they must stand up to scientific scrutiny. By making very conservative evaluations, we then ensure our data are robust and strong. Again, for the sake of consistency, we must establish what it means to be conservative. The most conservative diagnosis is always CBD (Could not Be Determined). This is a fundamental premise of this protocol. It is best understood by thinking of it this way: *every animal or carcass is a CBD until proven otherwise*. If evidence of human interaction is found, then the objective finding is YES, there were signs of HI. If the animal is thoroughly examined and no evidence of HI is found, then the answer is NO. However, if any factors compromise your ability to evaluate the carcass properly or thoroughly, then the finding must remain CBD. Factors that can affect your ability to

evaluate a stranded animal for signs of HI include, but are not limited to: decomposition, scavenger damage, predation, inexperience in conducting these exams, logistics (large animals that one cannot manipulate to examine both sides), etc. By standardizing the way we examine the animals, collect data, and document interactions, we ensure that we are not only answering the same question, but using the same basis to draw our conclusions. All organizations implementing this protocol and utilizing the data sheet will collect comparable data, affording the opportunity to analyze data on a broader scale. When collected carefully and consistently, these data can be used to describe the types of interaction taking place (e.g. monofilament vs. multifilament net entanglement, small or large vessel interaction, ingestion of debris, harassment, etc.). These data can provide a sound scientific basis for policy and management decisions, but the nature of strandings makes it inadvisable to use human interaction data to estimate mortality or changes in mortality rate due to human interaction.

Images and video

In addition to describing what you observe, it is very important to document your observations through images and video. Digital, 35mm, and slide images are excellent means of capturing your observations. If possible, video taping or digitally recording images can also provide an outstanding record of your observations. If you don't have the means to photograph or video the animal, sketch what you see. These images are important in the human interaction evaluation. Documenting the presence or absence of HI serves to support your evaluation and final diagnosis. In addition, proper documentation allows those analyzing or utilizing HI data in the future to better understand your conclusions.

When documenting your examination, remember these tips:

- Photograph/video everything – even if you don't see marks
- Always use a label and scale in all images – label should include Field #, date of stranding, species, organization; close-up shots should include the name of the lesion/body part
- Always take a wide angle image first to allow viewer to place close ups in context.
- Be aware of shadows, glare and fingers – eliminate anything that obscures image and take images from different angles
- Draw and describe all marks

Collecting physical evidence

In some instances, human interaction cases may be considered as enforcement cases in which law enforcement officers will pursue the interaction as a criminal or civil offense. For this reason, it is important to treat every HI case as a possible enforcement case. Consult with your local law enforcement officials to determine their requirements for evidence handling. Evidence, which can include gear or debris removed from the animal, photos, and tissue samples, etc., should be collected and handled in a systematic manner.

Morphometrics

Morphometric data allow for a better understanding of the relationships among age estimation, growth rate, reproductive status, and disease processes of marine mammal populations. For consistency, all measurements should be recorded in centimeters. The only exception is the measurement of blubber thickness (recorded in mm). Weight should be recorded as either an actual or estimated value in kilograms. Sample morphometric data sheets with a convenient

self-explanatory measurement diagram for both pinnipeds and small cetaceans can be found in Appendices E & F.

The procedure for collecting morphometrics is essentially the same for both small cetaceans and pinnipeds. All measurements, except for girths, should be straight measurements parallel to the long axis of the body, not following the contours of the body. A measuring tape should be set out flat next to the animal, the starting end of the tape should remain in a constant position for all the necessary measurements. This will ensure accurate and consistent data collection. For cetaceans, straight length is measured from the tip of the maxilla (upper jaw) to the fluke notch with the animal ventral side down. Pinnipeds are measured from the tip of the muzzle (nose) to the tip of the tail with the animal ventral side down. For pinnipeds, an additional measurement, curvilinear total length, is required. For this measurement, the tape should be laid on top of the animal's dorsal midline, starting at the tip of the nose and following the body contour along to the tip of the tail.

The procedure for measuring blubber thickness is the same for both cetaceans and pinnipeds. To measure blubber thickness, create three **separate** single 2" – 3" long dorsal to mid-ventral incisions through the blubber layer down to the blubber/muscle interface: one intersecting the dorsal midline, one intersecting the lateral midline, and one intersecting the ventral midline along the plane of the axillary insertion of the forelimbs (Figures 1-1 & 1-2). Place the ruler inside the incision and measure only the thickness of the blubber from the blubber/muscle interface to the skin/blubber interface (Figure 1-3). Do not include the thickness of the skin in the measurement.

Figure 1-1. Incisions for blubber thickness.



Figure 1-2. Incision for blubber thickness.

Figure 1-3. Blubber thickness measurement.

Photography

Photographs serve as the visual component to the written descriptions of each area examined on the carcass. They also allow pathologists to assess gross lesions/observations in relation to samples for analyses. When photographing during a necropsy, include a photo ID card with every picture displaying the following information:

Field number/ tag/paint stick number
Species
Date of death and necropsy
Location of stranding
Tissue/lesion

Be sure to also include a scale (cm) in each frame and make sure that the photo card, the scale, and the area of interest are all in focus and legible (watch for glare). Prior to beginning the necropsy, take photos of the external surface of the animal, with at least one full body shot of both the left and right sides of the carcass. In the case of lesions such as propeller cuts, where measurements may be taken from an image, arrange the camera to be perpendicular to the surface of interest. When photographing specific lesions, be sure to get a frame of the entire organ/tissue to reference the location of the lesion on the organ/body, as well as a closer shot to depict details of the abnormality. If the tissue has been removed from the body, rinse excess blood using a light stream of cool water to better capture the lesion. In the world of digital cameras, you can never take too many pictures. Any abnormality is worthy of a photo. A blank photo ID card is located in Appendix G.

This page intentionally left blank.

- SECTION TWO -
Sample Management

A necropsy should be driven by an accumulation of observations, leading to indicated diagnostic tests. Such tests drive the precise sampling regimen. Additionally, laboratories often screen specific tissues for a given suite of potential etiologies. It is important that, while meeting routine screening goals, samples should always to be taken to ensure a full differential diagnosis is considered. Thus this manual focuses on the routine screens undertaken on Cape Cod, but it should not limit the user to those goals. A necropsy sample inventory list is helpful during the necropsy to ensure that all the samples for required analyses have been taken and stored appropriately. A sample inventory list can be found in Appendix H.

The quality of samples collected diminishes with the progression of the condition code, creating greater uncertainty with results. (Determining condition codes for cetaceans and pinnipeds is discussed at the beginning of the relevant sections.) It is important to understand the priority of samples to be collected. When in doubt, collect it, and unnecessary samples can be disposed of at a later time. Table 2-1 outlines the samples of value according to condition code.

Table 2-1. Valuable sample analysis according to decomposition code.

Code 2 Fresh Carcass	Histology, Cytology, Virology (tissue), Microbiology (swabs or tissue for culture, tissue for PCR), Parasitology, Contaminants, Biotoxins, Life History, Genetics
Code 3 Moderate Decomposition	Histology (limited), Virology (PCR), Microbiology (PCR), Parasitology, Contaminants, Biotoxins, Life History, Genetics
Code 4 Advanced Decomposition	Histology (limited) Virology (PCR), Life History, Genetics
Code 5 Mummified/Skeletal Remains	Life History, Genetics

Sampling for Histopathology:

Histopathology is the microscopic examination of tissue in order to study the manifestations of disease. Histopathology is most effective when collected from the freshest (code 2) carcasses. Decomposition significantly affects the structures of tissue cells and diminishes the value of histopathology, thus only a limited reading can be expected from carcasses of a later code.

Two sets of samples are collected for histological analysis: one for the analysis, the other to archive. As a rule, the tissues should be fixed using a ratio of at least 10:1 of 10% neutral-buffered formalin to tissue. Anything less will prevent adequate fixation and the tissues will decompose. It is helpful to rinse excessively bloody samples with a light stream of water to allow for more efficient fixation. Plastic, wide-mouth, screw-top 1.0L+ jars (Nalgene™) are preferred for storing histology samples. Ideally, fixative is changed after the first hour of exposure (Luna 1992).

The histology column on the inventory list encompasses the majority of tissue requirements. Unless an abnormality is observed in lymph nodes in other locations throughout the body, only the tracheobronchial, prescapular, and mesenteric lymph nodes are suggested for histology. If tissues appear abnormal, be sure to obtain a single section that includes both normal and abnormal tissue and sample the full depth of the abnormality penetrating down to the normal tissue. It is helpful to the pathologist if a laundry tag is used to identify lymph nodes and abnormal tissue. For larger, major tissues (i.e. lung or liver) collect representative samples from all sections - caudal, cranial, medial or distal portions. Any additional tissues collected for histology should be listed at the bottom of the inventory list.

When sampling tissue for histological analysis, only a small 1 to 2 cubic cm sized section of the tissue is required. If a tissue must be larger, it is helpful to make 1 to 2 parallel incisions to allow the formalin to adequately penetrate and fix the tissue.

Try not to disrupt the surface layers or mucosa of the tissue intended for histology. Crush artifacts are easily noticeable under the microscope. The best way to ensure that the highest tissue quality is submitted for histology is to trim tissues on a cutting board with a sharp knife or scalpel, and to avoid significant pressure with forceps.

Sampling for Cytology:

Simple impression smears can give real time feed back in a variety of scenarios. Impression smears are collected by pressing a clean microscope slide on a cut surface of interest, dried and stained with one of a variety of common staining protocols. It can then be examined on site, if a microscope is available.

Sampling for Virology:

For most virology screening methods, the basic target samples are: serum, lung, liver, spleen, lymph nodes and brain. Additional samples may include skin, mucocutaneous junctions or the oral cavity, rectum, and urogenital tract. If a fetus is present, sample from the fetal tissues outlined above, as well as adrenal glands and placenta. Required tissues for morbillivirus screening are itemized on the sample inventory list provided in the appendix, along with suggested storage media. For other specific tests, consult the researcher or lab for required tissues and proper sample storage protocols (chill, fix, freeze and/or place in viral transport media).

The most accurate virology results are derived from code 2 carcasses. However, code 3 carcasses can be successfully screened for virology by Polymerase Chain Reaction (PCR) analysis. Fresh tissues should be stored in a sterile whirl pack bag or in viral transport media and transported on ice to the receiving laboratory as soon as possible. If fresh tissues will not be sent for analysis immediately, store samples at -80° C.

Virus isolation from frozen samples can be detected through PCR. Samples should be transported to the receiving laboratory on dry ice only.

With some pathogens, fixed tissues can also be utilized for specific antibody detection staining via immunohistochemical detection (IHC). Viruses may also be detected morphologically using

electron microscopy (Dykstra 1993). Use fixatives as directed by your EM laboratory.

Sampling for Microbiology:

Culture Swabs

Before establishing a bacteriology sampling protocol, discuss with your diagnostic service the nature of the swabs and media to be used to ensure a broad diagnostic capacity for aerobic and anaerobic bacteria. To prevent contamination of tissues intended for microbiology culture swabs, sterile procedures are required. External samples should be taken prior to opening the body cavity. Sample internal tissues immediately as they are exposed within the body cavity. Using a butane torch, flame a new sterile stainless steel scalpel blade rinsed in ETOH. Flame the intended incision site for 1 – 2 seconds. Make one straight incision into the tissue or cavity. Thoroughly swab inside the area with a sterile culture swab. Fluids may be aspirated into a sterile syringe and cytology, PCR, and cultures may be undertaken with the contained material. Contain swabs in appropriate transport media and seal as soon as possible to decrease chances of contamination. Swabs should be sent for bacterial and fungal (mycotic) analysis the same day. If the analysis must wait until the next day, store the swab at room temperature. Do not allow samples to freeze and do not refrigerate.

Results received from culture swabs should be interpreted with caution as bacteria tend to multiply and travel through multiple organs shortly after death. For this reason, culture swabs are preferably taken from early code 2 animals unless an unusual lesion is observed in a carcass of a later code.

Tissue Samples and PCR

Tissue samples can be taken for molecular analysis of microbial agents from carcasses of varying condition. Target tissues for this analysis vary by microorganism but can include: liver, kidney, lung, spleen, pancreas, gonads, brain, lymph nodes, conjunctiva, and mucocutaneous junctions of the oral and urogenital tracts. Consult the working researcher or lab in advance for required tissues. A small amount of tissue is needed and can be collected in centrifuge tubes or cryovials. Sterile dry swabs can also be used to collect DNA for analysis. Place swab in cryovial or collection tube. Store swabs and tissues at -80 C.

Sampling for Parasitology:

The collection of parasites is important not only for the species identification and documentation of specific parasites in marine mammals, they may also harbor pathogens and can be useful in viral isolation, such as morbillivirus. Dead parasites can be stored in ethanol at room temperature. It is always helpful to fully rinse the parasite with saline before storing in ethanol. If there is an in-house parasitologist that will look at the parasites while they are still alive, ideally within 24hrs, store samples in saline at room temperature. In any case, consult with your parasitologist for more specific guidance on sample preservation.

Sampling for Contaminants:

Toxins and other chemicals that exist in the marine environment, whether naturally occurring or

human produced, have the potential to be consumed by marine life and incorporated into their tissues. Contaminants can bioaccumulate in the tissues of marine life as they move up the food chain, and as top predators, marine mammals have the potential to retain high levels of toxins in their tissues. High contaminant levels can have numerous, negative impacts on the health of marine mammals, including compromising the immune system and affecting behavior and/or development through hormonal disruption (Geraci & Lounsbury 2005). Therefore, sampling tissues for the presence of contaminants can lead to a better understanding of the overall health and the factors involved in the animal's demise.

Blubber, muscle, liver, and kidney are tissues collected for analysis of contaminant levels. When collecting blubber, be sure to remove any skin or muscle attached. (Some laboratories may require skin and muscle to be attached to blubber. Check with receiving laboratory.) Each tissue section should be at least 100.0 grams and wrapped completely in acetone washed aluminum foil, shiny side away from the tissues. (Prior to wrapping the tissue sample, the side that will be in contact with tissue should be coated with a small amount of acetone and allowed to air dry.) The wrapped sample is then placed in a ziplock bag and stored in a –20 ° C freezer**.**

Sampling for Biotoxins:

Biotoxins are naturally occurring toxins produced by dinoflagellates and other marine algae that accumulate in animals as they are passed through the food web. Fish and invertebrates carry biotoxins that, when ingested in large quantities, prove to be harmful in larger predators, such as marine mammals. Common toxins found in marine mammals include domoic acid, brevetoxin, and saxitoxin, all of which are neurotoxins. See O'Hara and O'Shea (2001) for background. Biotoxin samples should be collected when an algal bloom is suspected in the surrounding area and/or the live animal exhibited neurological symptoms.

Biotoxin samples include tissues and fluids such as: liver, kidney, serum, aqueous humor, stomach contents, intestinal contents, feces, and urine. Tissue samples can be stored in plastic, ziplock bags. Stomach contents, intestinal contents, and feces can be collected into vials of appropriate size, usually 10-20mL containers will suffice. Collect 5—10mls of urine and 1—2 mls of aqueous humor, the thick, watery substance that is located in front of the lens of the eye, using sterile syringes and needles and store in vials of appropriate size. These samples should be stored in a –80 ° C freezer unless being shipped immediately on dry ice.

Life History and Genetics:

Many species that strand along the shore of Cape Cod are not resident or near-shore species, thus, little is known about their life history. Even for species where information on the local populations is sufficient, collecting and analyzing these data allow us to recognize changing trends. Age estimation, genetics, trophic position, habitat usage, and reproductive status of the stranding populations can be assessed through the collection of teeth, skin, stomach contents, gonads, and skeleton. This information not only helps us understand the dynamics of these specific populations but can also help us to interpret other findings, i.e. histopathology and contaminants, and we can recognize the impacts and vectors of potential threats to the marine environment at large.

Life History:

- The lower left jaw of a seal or 5–7 teeth from the mid-lower left mandible of an odontocete are collected into a ziplock bag and frozen at –20° C.
- Any discharge from the mammary glands can be collected into a >10.0ml tube and frozen at –20° C.
- Sections of the reproductive system should be fixed separate from all other tissues intended for histology. For females, collect both ovaries and a section of the uterine horn. For males, take a section of one testis with epididymus still attached. (Notch the left ovary and testis for differentiation).
- If a fetus is present and is not large enough to conduct an individual necropsy, open the abdomen and store the entire body in formalin.
- Stomach contents are to be put into an air-tight container, leveled off with water, and chilled at 38 ° F. If the samples can not be processed within 48hrs, contents alone, no water, can be frozen at –20° C. Diet scientists routinely request an unopened stomach. This however compromises the gross pathology data, disallowing examination and sampling of the inner surface. This protocol achieves a workable compromise.
- Retain entire skeleton for cleaning and museum archiving. A necropsy is incomplete until all cleaned bones have been examined. Store at –20° C until ready for cleaning.

Genetics:

Two, full thickness, skin samples are taken from each animal for genetic analysis. One sample (~1 sq. inch) is placed in a ziplock bag and frozen at –20°C. The other of similar size is diced into 1.0 mm cubic pieces and placed in 20% dimethylsulfoxide (DMSO) salt-saturated (NaCl) solution.

Creating Labels:

"Two is one. One is none." At first, the labeling system may seem a little redundant, but having <u>everything</u> <u>double</u> labeled not only ensures organization to the samples taken during the necropsy process, but it also helps identify samples in the future when retrieving them for specific research. A tissue without a legible label is useless. The "Two is one. One is none." motto means that each individual sample should have two labels: one inside the sample bag/ container and one on the outside of the sample bag/container. Please refer to the Figure (2-1) for further explanation on frozen sample storage.

The first label is written in black Sharpie on a 1 – 2 square inch piece of Tyvek tag, or other matter/chemical proof paper (Figure 2-1a). Include the animal's field number; genus and species ID, date of animal's death followed by how animal died if it is a code 1 (use E for euthanasia, D for natural death) or date of stranding (S) if code 2 or later, date of necropsy (N), location of stranding, and tissue type. Sometimes an animal may have a tag or paint stick number, be sure to include this information on all the labels as well. The Tyvek label (Figure 2-1a) goes into a 2 x 3 inch ziplock bag (tag bag) (Figure 2-1b) which then goes into a larger bag (Figure

2-1c) containing the individual sample. For virology samples, an ID tag (in a tag bag) can be inserted into the whirl pack bag once the tissue has been collected. The individual sample bag should be labeled in black Sharpie on the white space provided. All information should be consistent throughout the labeling process.

Figure 2-1. Single tissue bagging and tagging.

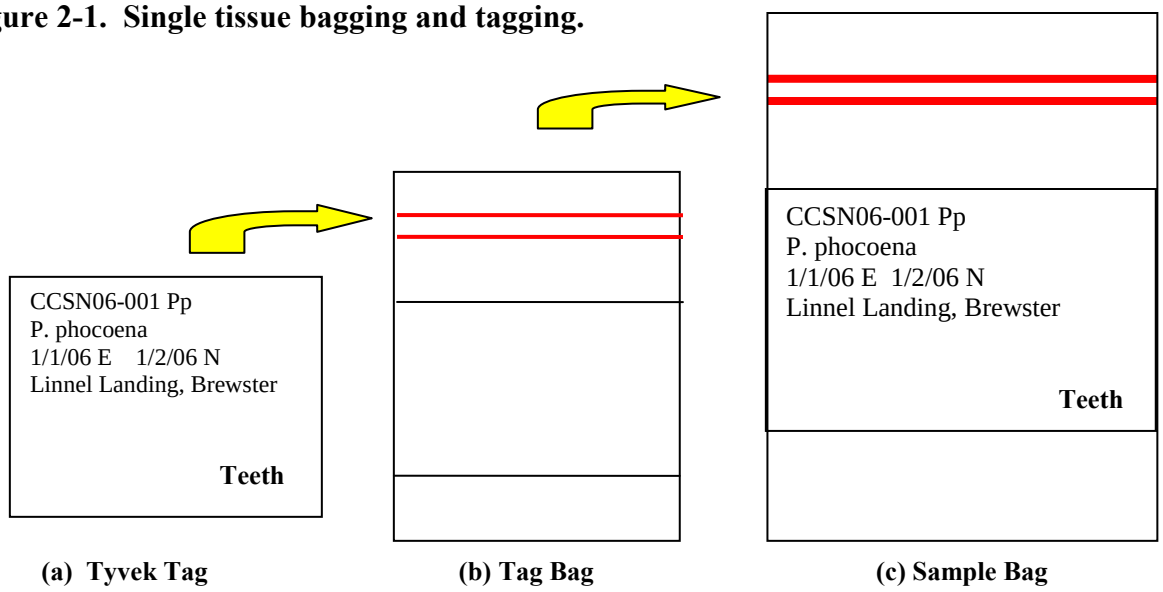

For histology samples, a label can be affixed to the outside of the jar using a black Sharpie marker on label tape. Clear packaging tape can be put over this label for reinforcement. The second label should be written on a 1 -2 square inch piece of Tyvek paper, using pencil, and placed inside the jar with the formalin and tissues.

Once all samples have been collected and placed in the appropriate bags, it is helpful to then store them in to a larger sample suite bag: frozen samples taken for life history and genetics can be put together into a larger (~ 8 x 10 inch) ziplock bag and appropriately labeled as life history and genetics; all samples for contaminants can go into a contaminants suite bag, and like-wise for herpes, morbillivirus, etc. (Figure 2-2). This is a very efficient system when retrieving samples for specific research.

The bagged sample suites can be placed together into one final large (9 x 13 inch or larger) ziplock bag and labeled appropriately, including sample suite types.

Figure 2-2. Multiple tissue bagging and tagging.

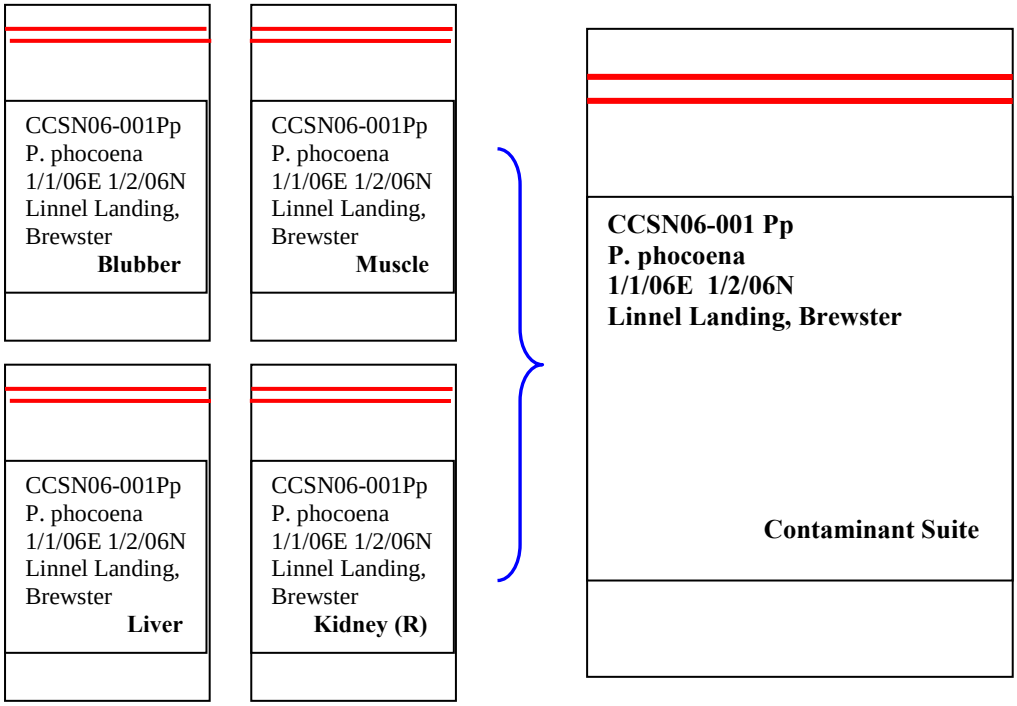

Tracking samples:

It is extremely important that all samples archived or sent for analysis are well documented. Marine mammals and their parts are federally protected and the reporting institution is legally responsible for knowing the location of each part. Where practical, samples and data should be archived using museum curation standards.

This page intentionally left blank.

- SECTION THREE -
Pinniped Necropsy Technique and Anatomy

As a reminder, it is helpful to have all necessary equipment and sampling needs set up and accessible prior to the start of the necropsy. A sample equipment list is provided in Appendix D of this manual

External Exam

Condition Code:

Before beginning the necropsy, carcass condition must be determined to decide what degree of sampling will be of greatest value. Preferably, necropsies are performed on fresh carcasses (within 48 hours of death); however, environmental conditions can greatly impact condition code. For example, very warm weather will accelerate carcass deterioration. If human interaction is suspected, or forensic data are of value, necropsies should be conducted irrespective of tissue quality. Carcasses are classified in one of five code categories based on specific levels of decomposition:

Code 1: Alive

Code 2: Fresh carcass (Figure 3-1); < 24 hours post-mortem; normal appearance, usually with little scavenger damage; fresh smell; minimal drying and wrinkling of skin, eyes and mucous membranes; eyes clear; carcass not bloated, tongue and penis not protruded;

Figure 3-1. Fresh carcass

Code 3: Moderate decompositions (Figure 3-2); Carcass intact, bloating evident (tongue and penis protruded) and skin cracked and sloughing; possible scavenger damage; characteristic mild odor; mucous membranes dry, eyes sunken or missing;

Figure 3-2. Moderate decomposition.

Code 4: Advanced decomposition (Figure 3-3); Carcass may be intact, but collapsed; skin sloughing; often severe scavenger damage; strong odor; blubber and muscle easily torn or falling off of bones; liquefied internal organs.

Figure 3-3. Advanced decomposition.

Code 5: Mummified or skeletal remains (Figure 3-4)**;** carcass desiccated; dry pelt may be left over bones.

Figure 3-4. Mummified or skeletal remains.

Nutritional Condition:

The nutritional condition of a pinniped can be assessed by looking at the pelvic and neck regions of the animal. A **robust** animal will have a rounded, fusiform body shape (Figure 3-5). Distinction of pelvic bones and neck will not be obvious. The pelvic bones and neck will be slightly visible in a **thin** animal. An animal that is **emaciated** will have obvious protruding pelvic bones, a visible neck and a possible visible outline of the rib cage (Figure 3-6).

Figure 3-5. Robust pinniped.

Figure 3-6. Emaciated pinniped.

Sex Determination:

To determine the sex of a pinniped you must examine the ventral surface of the animal. Male seals will have a penile opening on the ventral midline caudal to the umbilical scar (Figure 3-7). You can also feel for the os penis, or penile bone, through the skin. With lactating females, two horizontally spaced, off center teats will be visible caudal to the umbilicus. For non-lactating females, the teats will be less obvious and may appear as small areas of baldness (Figure 3-8). To differentiate male and female you can also examine the peri-anal region. Females will have two openings: the anus and the vagina. Males will have only an anal opening.

Figure 3-7. Male pinniped.



Figure 3-8. Female pinniped.



Integument:

Where collecting samples for analysis is prompted, please refer to Section 2: Sample Management .

An external examination should include the investigation and description of the eyes, ears, mouth, nostrils, umbilicus, genital aperture, anus, fur, and skin. When examining the eyes, look for discoloration, injuries, or discharge. Note any swelling or discharge around the surface area of the ear opening. Document any lesions, parasites, and the mucus membrane color in the mouth. Make note of worn or missing teeth. Describe color and amount of discharge from nostrils. Obtain nasal and/or ocular culture swabs as well as culture swabs of external lesions. PCR and electron microscopy samples can also be taken. Examine the umbilicus in neonates for signs of infection as well as degree of healing. Look for lesions such as ulcerations and erosions, as well as discharge, growths, or staining around the genital area and anus. If the animal has mammary glands, attempt to express milk and note color, consistency, and estimate amount in cc's. Milk can be expressed by pressing on the body about 10cm lateral and cranial to the mammary slits and massaging downward toward the slits. Evaluate quality of fur. Look for thinning or hair loss. Thoroughly examine and document any scars, abscesses, wounds, and parasites on the skin. Make note of the size (length x width x depth/height), shape, color, texture, location, and distribution of all abnormalities. Sample unusual findings as described in the Sample Management section. Pay particular attention to regions commonly affected by fishing gear interactions such as axilla, snout, oral cavity, neck and peduncle. Lacerations, strictures, hematomas and fractures are commonly associated with entanglement in fishing gear and other debris.

Figure 3-9. Gross Description: Multifocal fur loss disseminated over the dorsal trunk and head.

Morphologic Diagnosis: *Fungal Dermatitis with alopecia

Figure 3-10. Gross Description: Multifocal, 1.0x 0.3cm oval shaped, raised, orange, firm interdigital plaques.

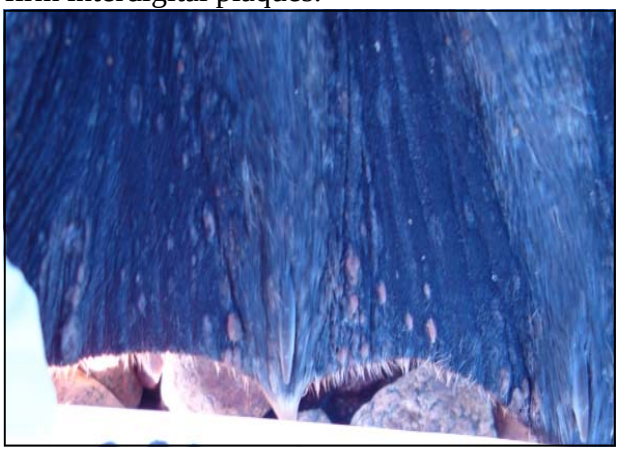

Morphologic Diagnosis: Fungal dermatitis.

Figure 3-11.

Figure 3-11. Gross Description: Large, chronic, 13.0cm circular 4.0cm deep ulceration on the caudal dorsal midline that is mottled light black to brown and has an irregular surface.

Morphologic Diagnosis: Chronic dermal ulcer.

Skin & Teeth Sampling:

Skin:
Using a scalpel blade, remove a two inch piece of skin from between the 1st and 2nd digit of the left rear flipper. Sample a section for genetics (frozen and DMSO) and histology.

Teeth:
The entire lower left jaw is removed for life history analysis (aging). This is done by first separating the right from left by cutting through the mandibular symphysis (Figure 3-12). The left mandible can be dislocated from the zygomatic arch (on the skull) by trimming away the connective tissue and muscle while rotating the bone in its joint (Figures 3-13 & 3-14). Try to avoid breaking the jaw bone during removal.

Figure 3-12. Removal of lower left jaw.

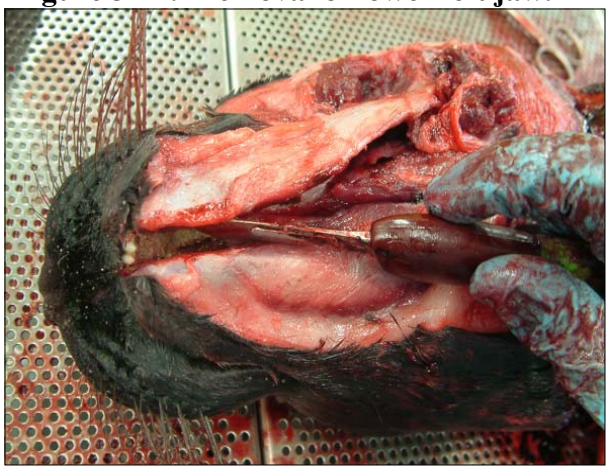

Figure 3-13. Removal of lower left jaw.

Figure 3-14. Removal of lower left jaw.

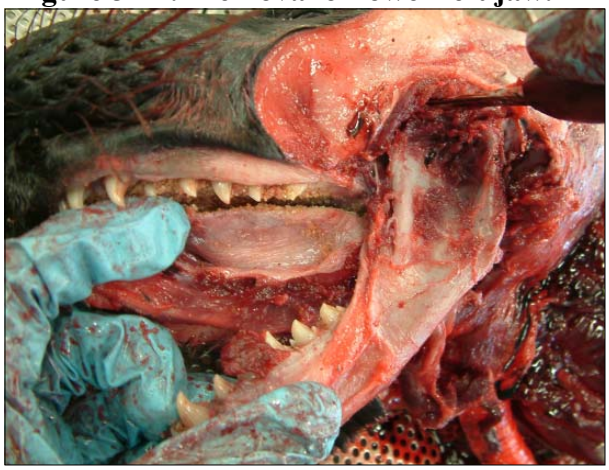

Removal of External Layers - Skin, Blubber and Muscle

Skin and Blubber:
To enter the cavity of the animal the skin, blubber, and muscle must first be removed. Begin with the animal ventral side up. With a scalpel blade, make the first incision, under the chin, near the apex of the throat, and continue down the midline to the anus. If the animal is male, course slightly left of the penile opening. The incision must incise down to the blubber/muscle interface. Do not penetrate the skeletal muscle. Next, make perpendicular incisions on either side of the midline incision approximately 15.0cm apart creating a series of panels down the length of the animal (Figure 3-15).

Figure 3-15. Animal in dorsal recumbence with numerous full blubber thickness incisions.

The blubber can easily be removed by cutting through the fascia plane and reflecting the sections of skin and blubber away from the body, in a ventral to dorsal manner (Figure 3-16) Again, do not penetrate the skeletal muscle, remain at the blubber/muscle interface (Figure 3-17). Note the thickness, texture, and color of the blubber layer. Look for parasites, bruising, and abnormalities within the blubber. Sample for histology and contaminants.

Figure 3-16. Reflection of blubber along the fascial plane.



Figure 3-17. Reflection of blubber along the fascial plane.

Figure 3-18. Normal blubber: Thick, firm, creamy white to light pink.

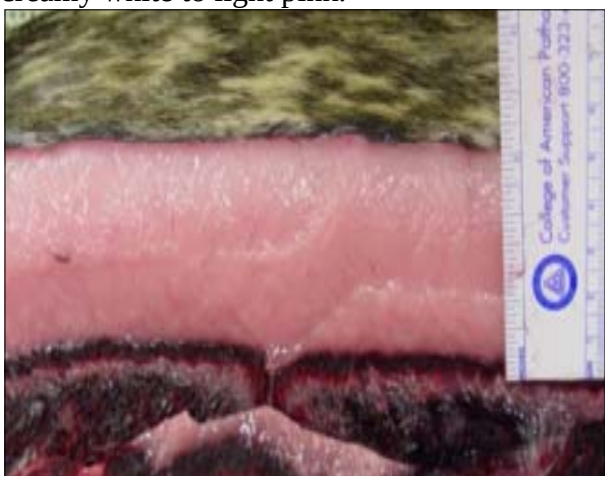

Figure 3-19. Gross Description: Several lesions spanning the thickness of the blubber of the caudal ventral abdomen characterized by cavitations and deep red, poorly demarcated edges with a green tinged center.

Morphologic diagnosis: *Panniculitis—inflammation/necrosis of subcutaneous fat.

Skeletal Muscle:
Remove the panels of blubber and skin from the carcass. Examine the quality of the fascia and muscle before removing it. Note the color, thickness, texture, and abnormalities of the muscle mass. Look for signs of bruising and hemorrhaging. Trim away excess muscle from the ventral and lateral surfaces of the rib cage. Be sure not to penetrate the body cavity. Obtain muscle samples for contaminants and histology.

Internal Examination

Removal of the Scapula and Prescapular Lymph Node:
With the animal still ventral side up, begin to remove both front flippers. Pull the appendage away from the body toward the table surface and carefully cut through the tissue that connects the flipper and scapula to the body wall. Locate the prescapular lymph node prior to the complete removal of the scapula. The oval, beige tissue is located between the scapula and body just cranial to the leading edge of the bone (Figure 3-20). Normal lymph nodes throughout the body usually share the same characteristics: a well defined round or oval shape, slightly firm texture,

color is diffusely beige to peach, with very slight differentiation between the cortex and medulla. If the lymph begins to vary from the homogenous peach to tan, it may be indicative of a reaction. Note the size, shape, color and texture of the prescapular lymph node. Be sure to distinguish changes of the cortex and changes of the medulla. Sample for histology, microbiology, molecular and other ancillary investigations.

Figure 3-20. Location of the prescapular lymph node in situ.

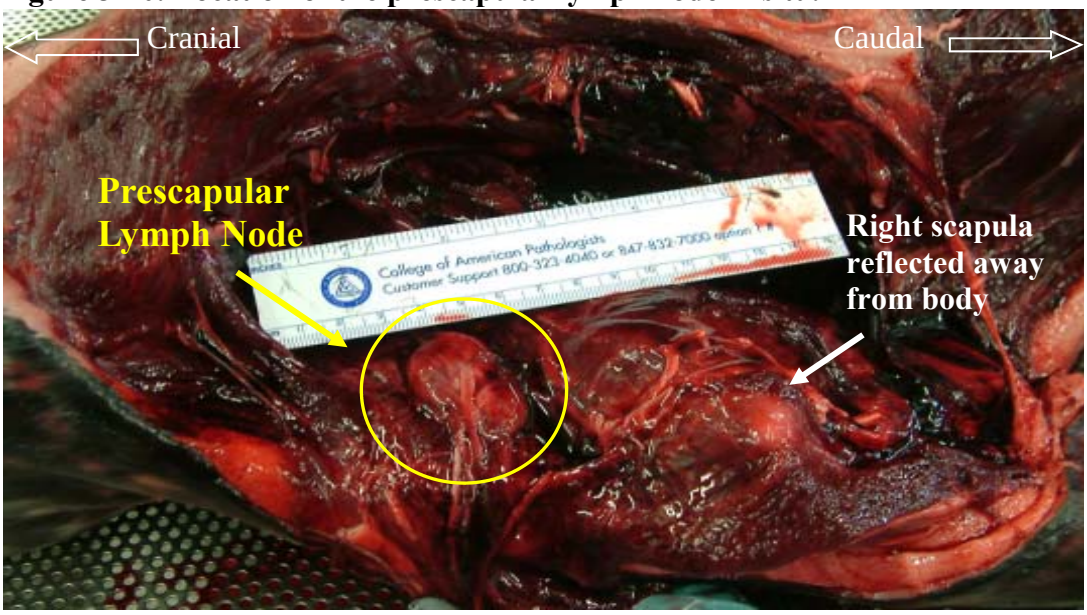

Figure 3-21. Normal lymph node

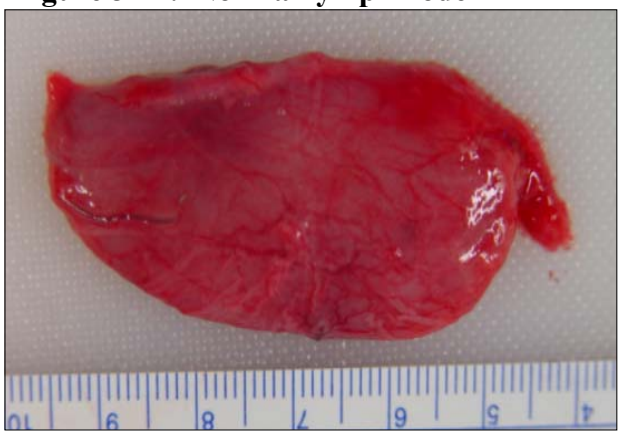

Figure 3-22. Gross Description: Connective tissue surrounding lymph node is dark red and edematous; cortex is slightly thickened; medulla is mottled light pink to purple.

Morphologic Diagnosis: Lymphoid hyperplasia.

Thyroid

Locate the paired, dark purple, discoid shaped thyroids located along either lateral side of the cranial trachea (Figure 3-23). The color and texture is often similar to smooth muscle. The parathyroid is a small, light colored tissue attached to the thyroid along the cranial margin of the thyroid

and can aid in correct tissue identification, if it can be found (Figure 3-24). Remove the tissue and describe its size, shape, color and texture. Sample for histology.

Figure 3-23. Location of thyroid; ventral side up.

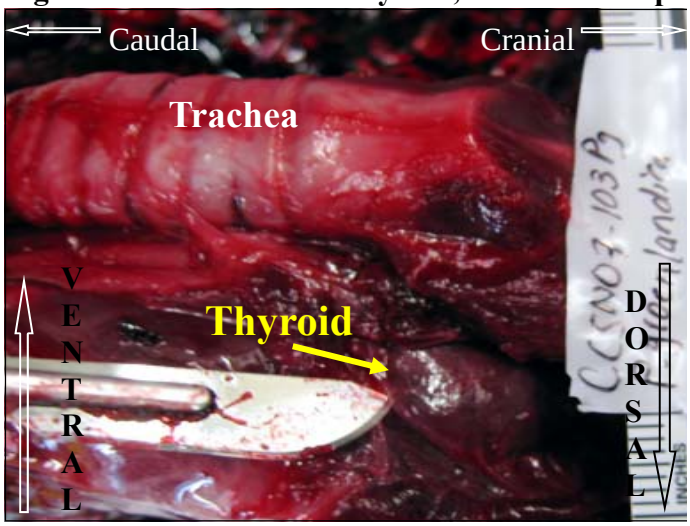

Figure 3-24. Normal, paired thyroid with parathyroid attached.

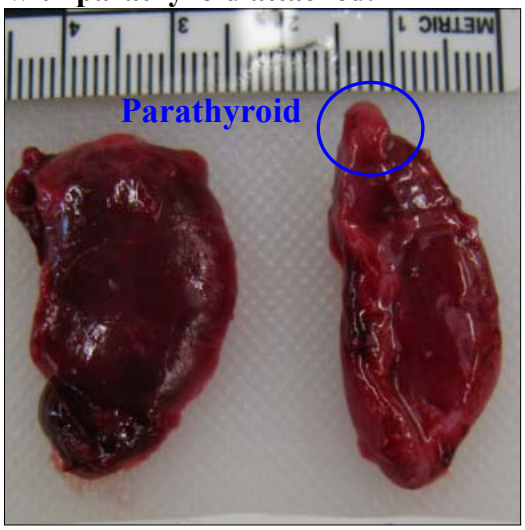

Thymus:
The thymus, a large, lymphoid organ, is primarily found in neonates and some juveniles. It is situated at the base of the thoracic inlet, cranial to the anterior margin of the heart. The primary function of this organ is to generate T-cells. The thymus is absorbed with time after weaning, thus is not usually visible in adult marine mammals. Examine the tissue externally and internally. Note the size, shape, color and texture. Sample for histology, microbiology, molecular and ancillary investigations.

Before cutting into the body cavity of an animal, to obtain uncontaminated bacterial and viral samples from the thoracic and abdominal cavities, sear a section of the body surface with a flame (such as from a propane torch), then, with a flamed blade, incise into the body cavity and insert a swab.

To expose the abdominal organs, incise the abdominal wall from the last rib mid-ventral to the hip. Extend the most cranial cut laterally along the thoracic arch and reflect the abdominal musculature to expose the internal tissues. Visually assess the orientation of the organs and collect any free fluids aseptically in a sterile syringe prior to proceeding with the internal examination.

Removal of the Rib Cage:
Before collecting any samples or cutting the ribs, the diaphragm should be punctured with a scalpel or scissors and deflation should be noted. If the diaphragm is already deflated, it is possible that a pneumothorax or severe pneumonia may be present. To open the thoracic cavity, feel for where the muscle attaches to the rib and trim away excess muscle without penetrating the diaphragm. Without breaking the bones, remove the rib cage by cutting through each thoracic rib mid-articulation, or “sweet spot”. The “sweet spot” is the cartilaginous flex point that allows movement of the rib cage during inhalation and exhalation and can be felt upon palpation. To

note, age and disease may effect the way joints disarticulate. As you move cranially and are able to reflect the rib cage away from the cavity, look at the internal surface of the rib cage and you can easily see each articulation in line with another (Figure 3-25). Using this visual guide, the ribs should easily separate without breaking. Continue to remove the rib cage by reflecting back toward the cranial end of the body. Once the ventral cartilaginous rib cage is removed, examine the thoracic cavity with all organs in place (Figure 3-26). Note any discoloration, lesions, adhesions, odor, or fluid.

Figure 3-25. Lateral rib cage articulation can easily be seen from within the cavity.

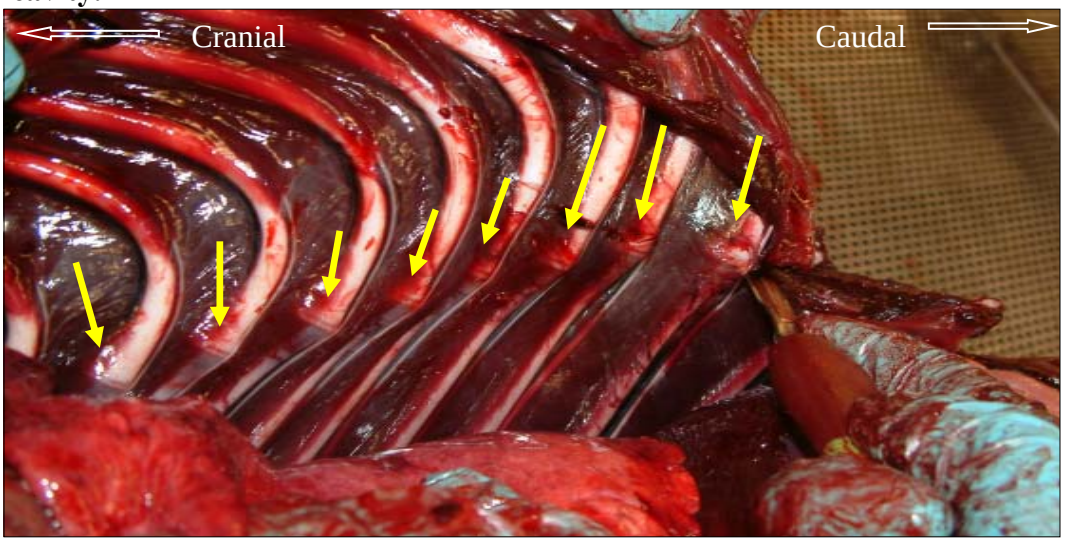

Figure 3-26. First view of body cavity with rib cage and diaphragm removed.

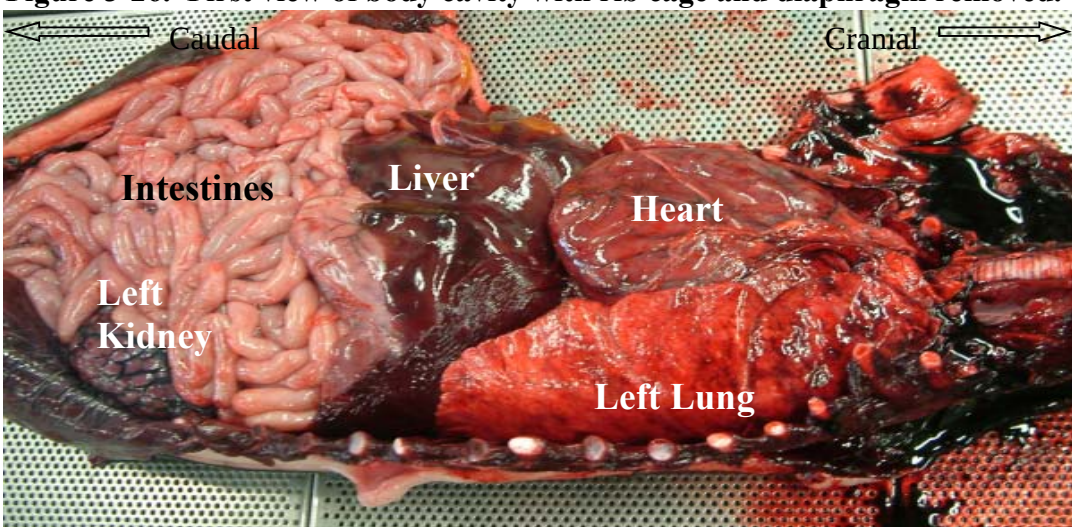

At this point, a systematic examination of the internal tissues needs to be followed. The organs may be removed as a pluck (organs still attached to one another), or may be removed one by one. The method of sampling can be guided by sampling needs, condition code, and personal preference. For microbiology sample collection, it is recommended that internal fluids, such as those in the gastro-intestinal system do not contaminate other tissues.

Tracheobronchial (TB) Lymph Node:
The TB lymph node is located proximal to the bifurcation of the trachea. It can easily be located by reflecting the cranial lung tissue away from the cavity and palpating the connective tissue between the lung and trachea bifurcation (Figure 3-27). It is recommended that this tissue be identified and removed prior to removal of the lung or trachea, as it can be easily lost without anatomical landmarks. Examine the lymph node externally and internally. Note the size, shape, color, and texture. Sample for histology, microbiology, molecular and ancillary investigations.

Figure 3-27. Location of the TB lymph node.

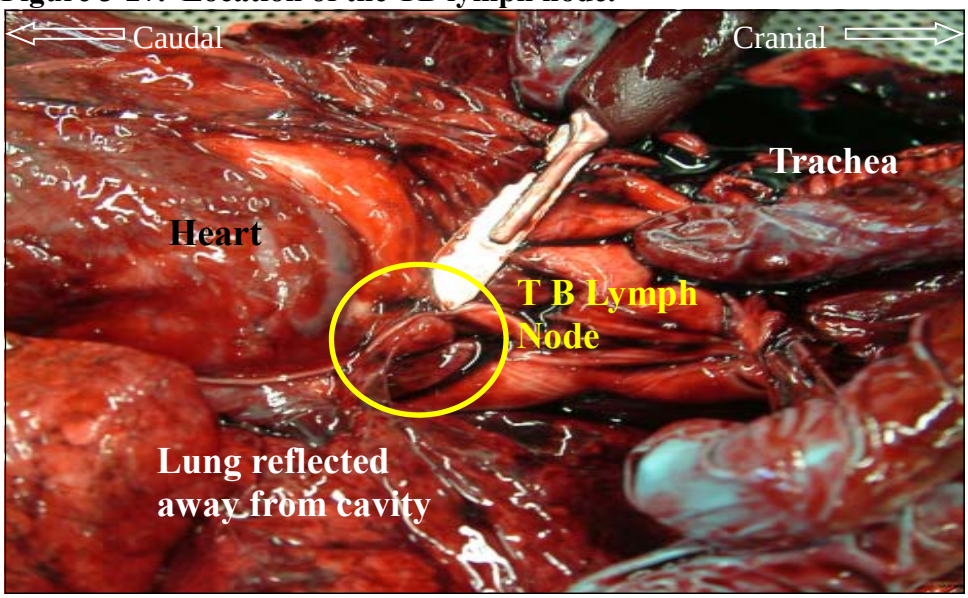

Figure 3-28. Cross section of the TB lymph node.

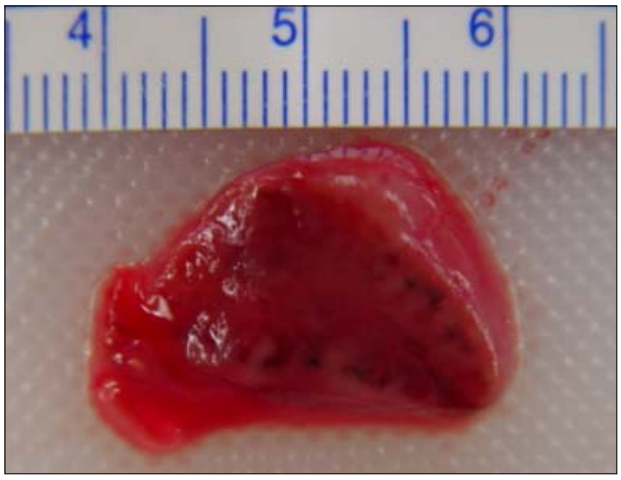

Figure 3-28. Gross Description: Multifocal, black, focal spots along the cortico-medullary junction of the TB lymph.

Morphologic Diagnosis: Multi-focal, pigmented lymphoid hyperplasia.

Lungs:
The lungs dominate the thoracic cavity and are the large, normally bright pink tissue with a consistent sponge-like texture. Detach the lung from the trachea at the bifurcation. Examine the pleural surface: note color pattern, and texture. Normal, air-filled lung tissue should bounce back immediately after being depressed with a finger (like a sponge) and float when placed in water or formalin. Seal lungs are comprised of a number of lobules, joined by a normally thin, translucent connective tissue which can become gas filled (emphysematous). To examine the internal structure, using scissors, trace the trachea from the bifurcation along the bronchi and into the bronchioles of each lung. Note whether fluid, froth, and/or parasites are present and describe (amount, color, etc.). Next, make serial cuts into the tissue by "bread-slicing" (making multiple, full thickness, parallel slices into the tissue) perpendicular to the long axis of the body. This is best done with a long knife using a single sweeping cut in order to avoid tearing or serrating the lung tissue. Examine the parenchyma and note color pattern and texture. Sample for histology, microbiology, molecular and ancillary investigations.

Figure 3-29. Three distinct lobes of the lung. Note the mottled pink to purple pattern on the surface.

Figure 3-30. Gross Description: The pleural surface is mottled pink to maroon; peripheral lobes are diffusely dark red.

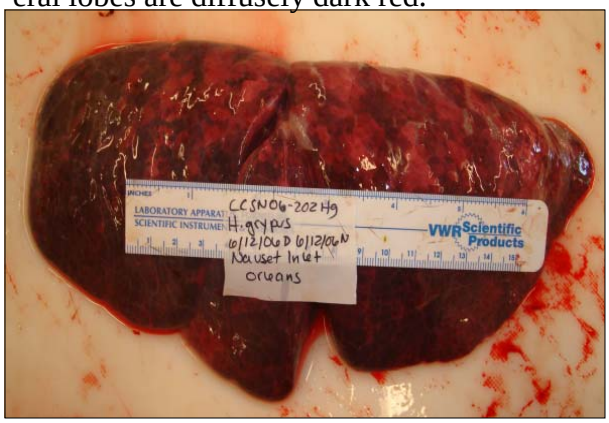

Morphologic Diagnosis: *Interstitial pneumonia

Figure 3-31. Gross Description: Multifocal areas of gelatinous, deep red tissue throughout the parenchyma.

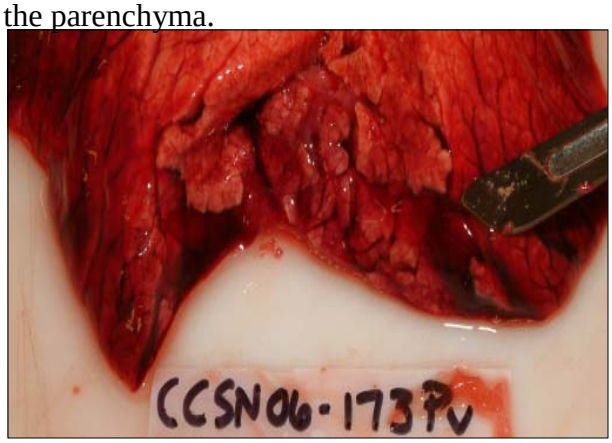

Morphologic Diagnosis: *Diffuse, interlobular pulmonary edema

Figure 3-32. Gross Description: Large (4.8 x 5.0 x 2.5cm), firm, multinodular mass with focal areas of hemorrhage within the parenchyma of the lower proximal margin.

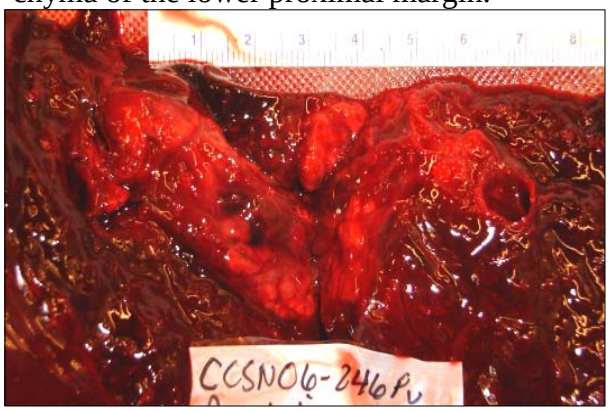

Morphologic Diagnosis: Pulmonary abscess.

Figure 3-33. Gross Description: Focal, 6.0 x 4.0 x 2.0cm area of fibrous consolidation.

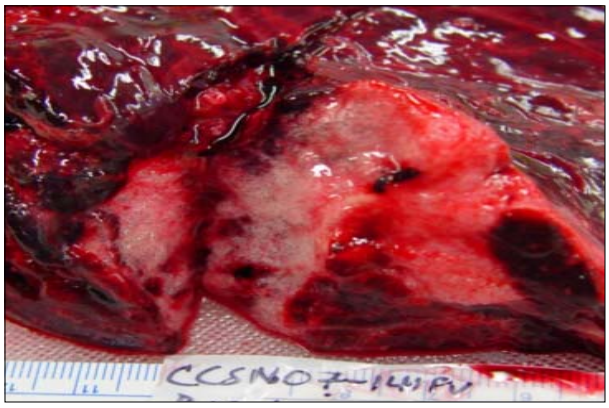

Morphologic Diagnosis: Chronic, resolved lobar pneumonia.

Figure 3-34. Opened bronchioles.

Figure 3-34. Gross Description: >1.0cm long, round white worms throughout the bronchioles with luminal mucus.

Morphologic Diagnosis: Verminous catarrhal (mucoid) bronchitis.

Trachea:
The trachea is a long, firm, off-white, flexible, ridged, tubular organ. Using scissors, cut through the entire length of the trachea from the bifurcation up to the apex of the throat. Examine the mucosa and identify contents (froth, fluid, blood, color, etc.). Sample for histology.

Heart Muscle and Valves:
Before handling the heart, observe and describe the pericardium. There should be a small amount of clear fluid within the pericardium to allow for lubrication. Note if there is excessive fluid and describe the characteristics. Also, note the presence of gas bubbles within the pericardium and note thickness of the tissue. Trim away the pericardium and observe the epicardium (external surface of heart) in situ. Note size, color, and texture of the right and left atria and ventricles, aorta, pulmonary valve, as well as the mitral and tricuspid valves. (Figure 3-35). Remove the heart by cutting transversely across the aorta and pulmonary artery leaving approximately 6.0 cm of each vessel still attached to the heart muscle. There are number of techniques for examin-

-ing the internal structures of the heart. One way is to use scissors to make a small opening in the right atrium and cut down along the peripheral edge of the right ventricle down to the apex. Continue cutting along the right ventricle side of the septum until this chamber joins the pulmonary artery and cut up through this vessel. Next, snip the left ventricle side of the apex, cut through the muscle along the septum, and continue through the aorta (Figure 3-36). This process leaves both sides of the heart intact.

Figure 3-35. External view of the heart.

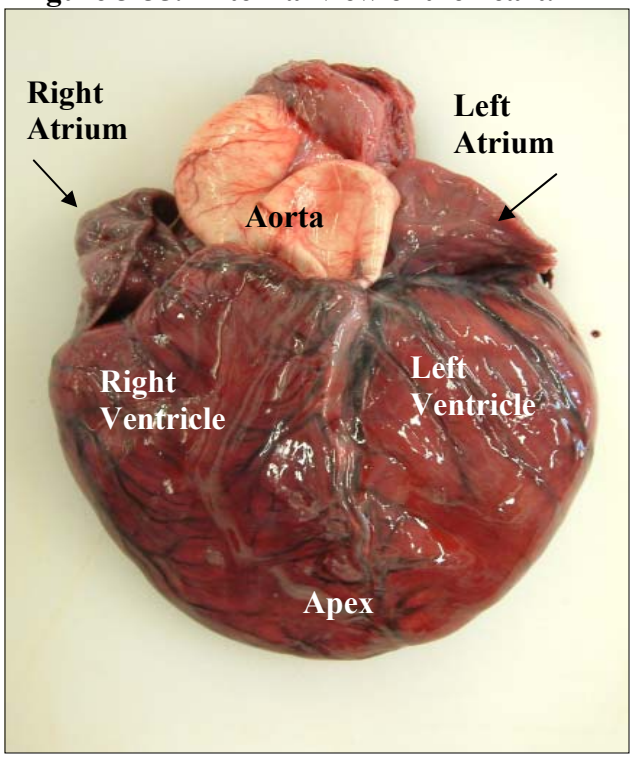

A simpler way to examine the endocardium (inner surface of the heart) is by slicing the organ completely in half starting at the apex going laterally toward the vessels, so that it opens up like a book. Examine each chamber for the presence of worms or other foreign matter. Note the size/thickness of each atrium and ventricle, as well as color and texture. The left ventricle should be substantially thicker than the right (~2:1 ratio). Thoroughly examine the interior of the valves for a change in texture or the presence of lesions. Normal mitral and tricuspid valves should be thin and slightly opaque. Once the endocardium is examined, bread-slice the ventricles to examine changes in the myocardium. Sample the left and right ventricles and atria, septum, apex, and aorta for histology.

Figure 3-36. Incision pathway to open the heart.

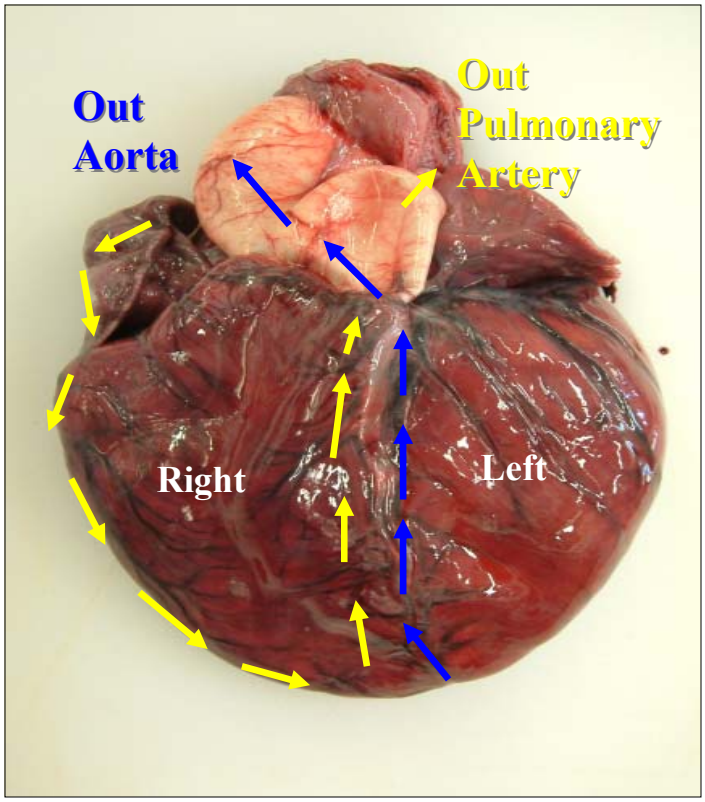

Diaphragm:
The diaphragm is the thin, smooth textured, dark maroon, expandable muscle that is attached to the caudal rib cage and separates the thoracic and abdominal cavities. Note the texture and color as well as any tears or adhesions. White striations over the surface of the diaphragm are normal. Trim away the diaphragm enough so that there is complete access to the abdominal organs. Sample for histology.

Liver:
The multi-lobular, diffusely maroon liver is quite large in pinnipeds and lies over the stomach, dominating most of the abdominal cavity (Figure 3-38). Once removed from the abdominal cavity, examine the parietal (toward the body wall) and visceral (toward the organs) surfaces of the liver and note color pattern, texture and size of the lobes (Figure 3-37). Examine the parenchyma of the liver by bread-slicing through the tissue. Again, note the color and texture within. Examine bile ducts for presence of parasites. Sample tissue for contaminants, histology, microbiology, molecular and ancillary investigations.

Figure 3-37. View of the parietal surface of a multicolored, multilobular liver with the gallbladder intact.

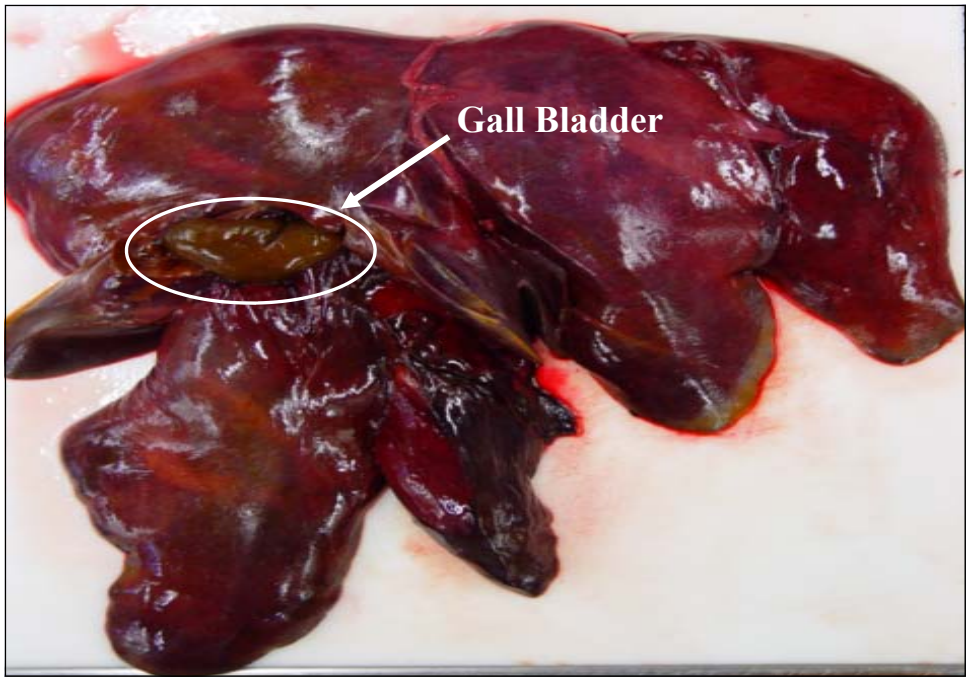

Gall bladder:
The gall bladder is a green, round, thin walled sac and can be viewed ventrally between the right and central lobes of the liver (Figure 3-37). To check for duct patency, cut into the duodenum, and observe bile flow. Aseptically collect bile for contaminants using a sterile syringe and needle. The gall bladder can be further sampled once the liver has been removed from the cavity and examined. This technique prevents contaminating the surface of the organ and remaining tissues with dark green to orange bile once punctured. Examine the gall bladder for stones and parasites. Sample for histology.

Figure 3-38. View of liver, stomach, and spleen in situ.

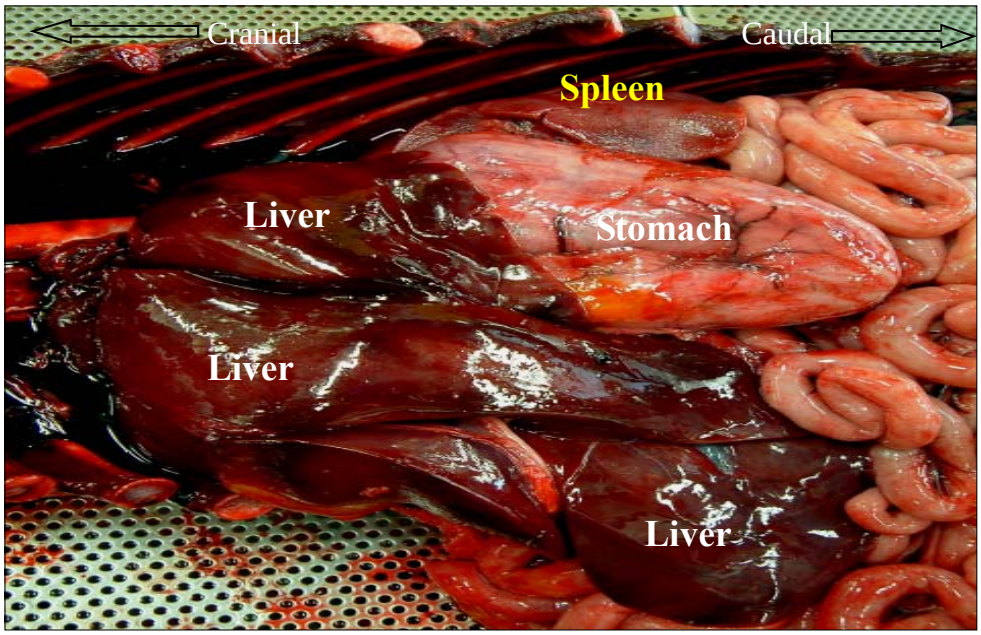

Figure 3-39. Liver removed from carcass.

Figure 3-39. Gross Description: Diffusely yellow/orange liver.

Differential Diagnosis: Icterus or fatty change.

Spleen:
The spleen is a flattened, oblong, mottled purple to white organ (Figure 3-40) located underneath the stomach along the left body wall (Figure 3-38). It is common for pinniped spleens to have irregular, serrated margins. Remove the spleen by detaching it from the omentum tissue. Note size, shape, color, and texture of both the surface and the parenchyma of the spleen. Examine the internal structures by bread-slicing. Sample for histology, microbiology, molecular and ancillary investigations.

Figure 3-40. Slightly pale, but otherwise normal, spleen.

Pancreas:
The pancreas is a peach colored, irregularly shaped, lobulated, softer tissue that is attached to the mesentery and sits in the curve of the duodenum. Remove the pancreas from the cavity by detaching it from the mesenteric tissue. Note the size, shape, color and texture of the surface. Cut into the parenchyma and note changes in color or texture. Examine ducts for parasites. Sample for histology, microbiology, molecular and ancillary investigations.

Mesentery and the mesenteric lymph node:
The mesentery is the window-pane-like connective tissue band attached to the intestines (Figure 3-41). This connective tissue should be translucent and show some resistance when attempting to bluntly dissect. Examine the mesentery for any abnormal adhesions as well as congestion or thickening of the vessels. If the lymphatic vessels are distended with milky fluid it is a sign of recent feeding. Note thickness and opacity of connective tissue. The mesenteric lymph node is a finger-like, gray to tan colored, larger lymph node that is centrally attached to the mesentery (Figure 3-41). Remove the lymph node from the mesentery. Note the size and shape of the mesenteric lymph node. Examine the exterior and interior aspects for changes in color and texture. Unlike previous lymph nodes discussed, the mesenteric lymph node tends to have a more defined cortex and medulla and can be a light shade of gray. Be sure to describe these structures separately . Sample for histology, microbiology, molecular and ancillary investigations.

Figure 3-41. Mesenteric lymph node in situ attached to the mesentery.

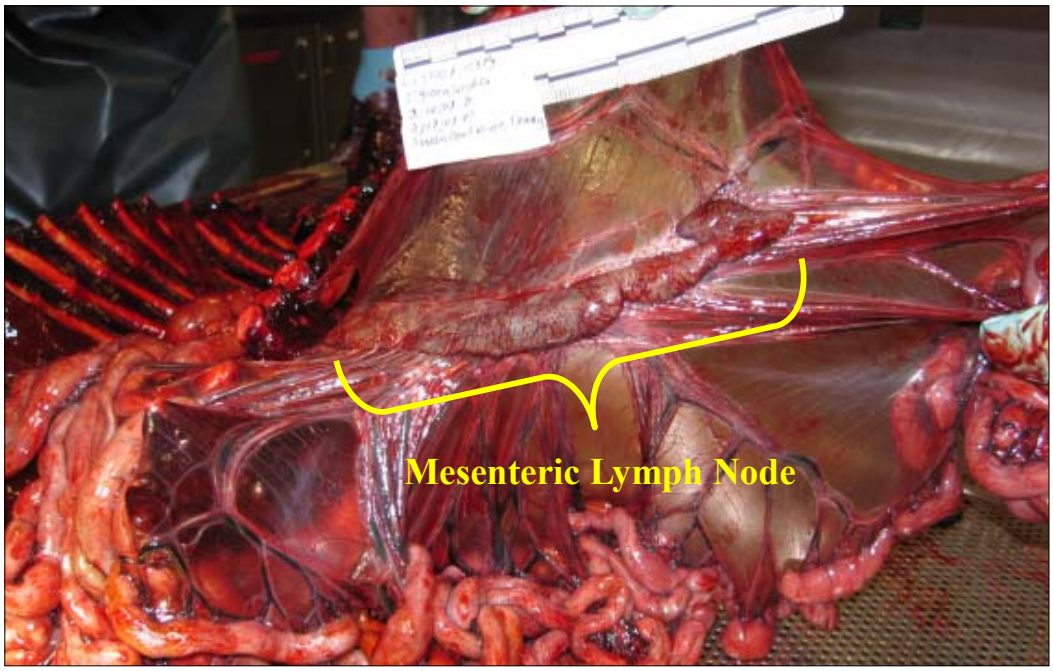

Figure 3-42. Cross-section of the mesenteric lymph node.

Figure 3-42. Gross Description: Lymph node is slightly enlarged and firm; cortex is thick and pink with a slight lobular pattern that infiltrates the medulla; medulla is soft and purple.

Morphologic Diagnosis: Reactive lymph node.

Adrenal Glands:

The right and left adrenal gland are located just anterior to the cranial pole of each kidney and are adhered to the dorsal abdominal wall (Figure 3-43). The adrenals are small, oblong, light maroon tissues possessing irregular furrows over the surface (Figure 3-44). Locating and extracting the adrenals prior to removing the kidneys is highly recommended, as they can be difficult to locate without the kidneys as an anatomical reference. To remove the adrenals, grasp and pull the tissue away from the body wall and cut the surrounding connective tissue. Before sectioning, measure (LxWxH) and weigh each adrenal. When cut in half, a normal adrenal will present a distinct darkened center (medulla) with a lighter perimeter (cortex). Note size, shape, color and texture of the external and internal tissue. Also, note relative size of the aperture, or opening in the medulla, which would indicate usage of the vessel. Normal apertures should be no larger than the tip of a pin. Sample each adrenal gland for histology.

Figure 3-43. Location of adrenal in relation to the kidney; adrenal is pale

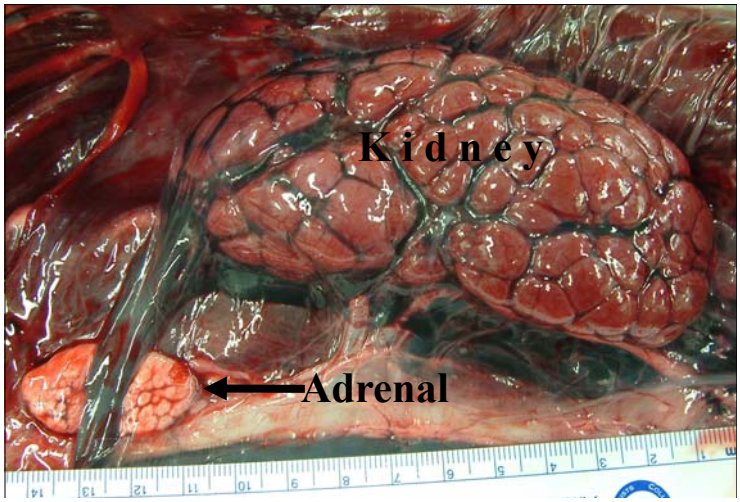

Figure 3-44. Normal adrenals; left is visceral surface, right is the parietal surface.

Kidneys:

The left and right kidneys are dark maroon, ovoid, tissues comprised of numerous, clustered reniculi (miniature kidneys) and are attached to the caudal dorsal abdominal wall (Figure 3-43). Examine the capsule (connective tissue surrounding the kidney) for the presence of fluid or bubbles and note color, thickness, and opacity. Remove the renal capsule by making a longitudinal incision and reflect each half away from the kidney to examine the internal surface of the capsule. Detach the kidney from the abdominal wall. Note the size, shape, external color and texture of each kidney. Examine the internal structure of each kidney by bread-slicing. Note color and presence of stones. Observe the degree of differentiation between the cortex and medulla as well as the medulla:cortex ratio within each reniculi (Figure 3-45). Each reniculi should be well demarcated but clustered together within the kidney itself. Sample for contaminants, histology, microbiology, molecular and ancillary investigations.

Figure 3-45. Close up of reniculi.

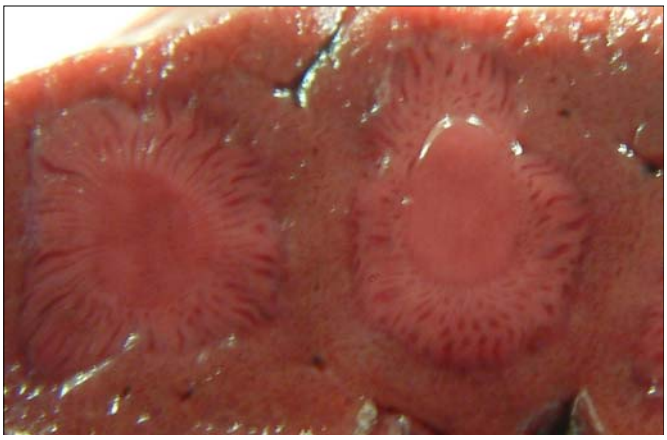

Urinary Bladder:

The bladder is a smaller, light pink, organ that is found just anterior to the pelvic bone along the ventral body wall (Figure 3-46). The organ often appears as a thick walled muscular organ, but if distended with urine, the walls may be thinned and semi-translucent. Before removing the bladder from the body, extract contents using a sterile syringe and medium gauge needle. If none are available, be sure to clamp the bladder using a hemostat before removing the organ in order to retain urine. Note color, consistency, and amount of urine. Remove the bladder and examine internally by cutting along the length of the organ to expose the mucosal surface. Note color and texture of the mucosa. Sample the cranial tip of the bladder for histology.

Figure 3-46. Location of bladder in situ.

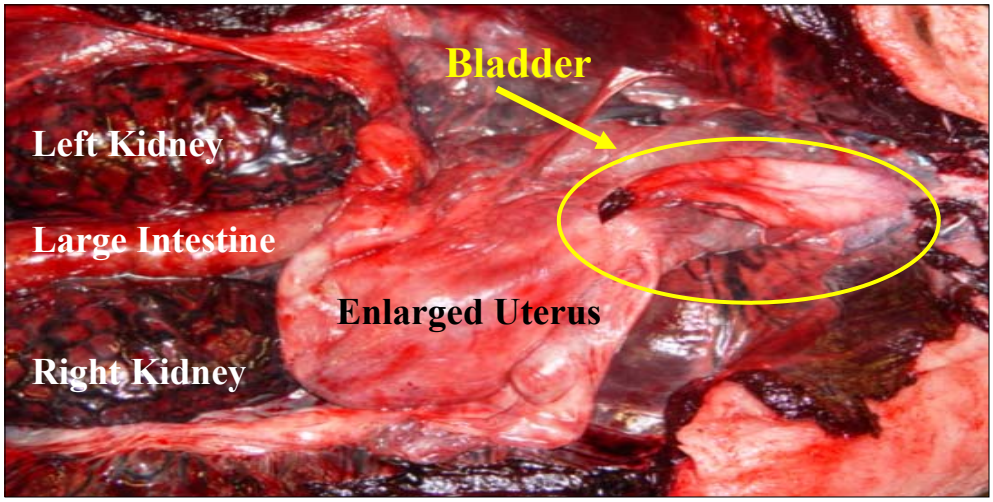

Figures 3-47a & 3-47b. Gross Description: Obvious stricture of the bladder wall in the middle of the organ; caudal serosa is dark red and gelatinous; cranial bladder wall is thickened; mucosa of the caudal end is dark red to purple;

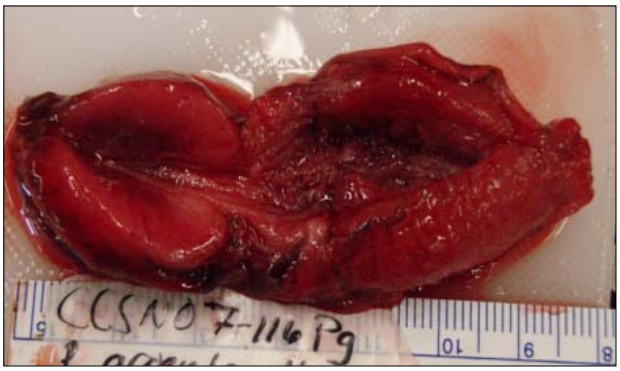

Morphologic Diagnosis: Stenosis, or narrowing, of the bladder with associated hemorrhage of the serosa and mucosa of the caudal end.

Reproductive tract:

<u>Female</u>- Ovaries and uterus

The uterus and ovaries can most easily be identified by following the reproductive tract from the vagina to the uterus where it bifurcates to a right and left horn, each ending at the attachment of the ovaries. The uterus is a tan to pink tissue that will vary in size and thickness depending on the maturity of the animal and its reproductive history. Note size, shape, color, and texture of the external and internal surfaces of the organ. If a fetus is present and is too small for a sufficient individual necropsy, incise the abdomen, collect microbiology and molecular samples, then preserve fetus whole in formalin. If the lung tissue floats in formalin (or water), this signifies that bronchiole expansion of the fetal lungs has occurred.

An off-white spindle-shaped ovary is attached to the end of each uterine horn. Detach the organ from the uterus and examine the external surface. Note size, shape, color and texture. A mature ovary will possess random darkened notches or scars (corpus albicans) which signify previous ovulations. The ovary of a pregnant female will posses a corpus luteum, or a large yellow mass attached to the ovary. Before internal examination, measure (LxWxH) and weigh each ovary. Also count and note the number of scars and presence/absence of a corpus luteum. Examine the tissue internally and note color and texture. Sample both the uterus and ovaries for life history, histology, microbiology, molecular and ancillary investigations.

<u>Male</u>- Testes

The elongated, spindle shaped, off-white paired testes are located outside of the abdominal cavity along the ventral body wall proximal to the ventral hip bones (Figure 3-48 & 3-49). Remove the testis, with the epididymus attached, from the body and obtain the measurements (LxWxH) and weight of each. Examine the size, shape, color, and texture externally and internally. Section epididymus for presence/absence of sperm. Obtain samples of each testis for life history, histology, microbiology, molecular and ancillary investigations.

Figure 3-48. Location of testes outside of the abdominal wall.

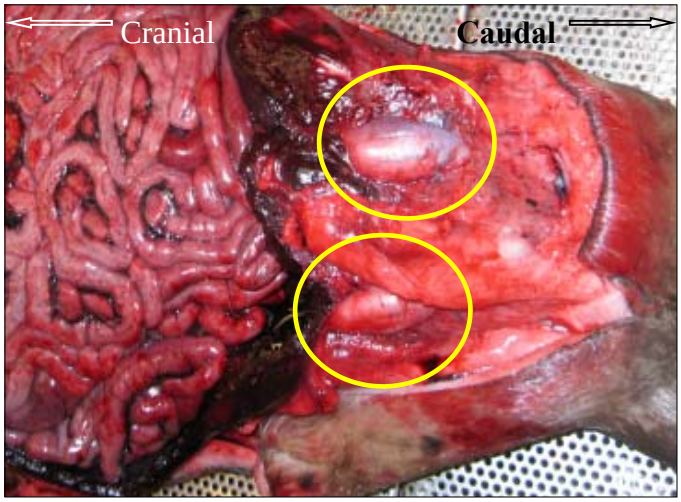

Figure 3-49. Normal, immature testes; left is visceral surface; right is the parietal surface.

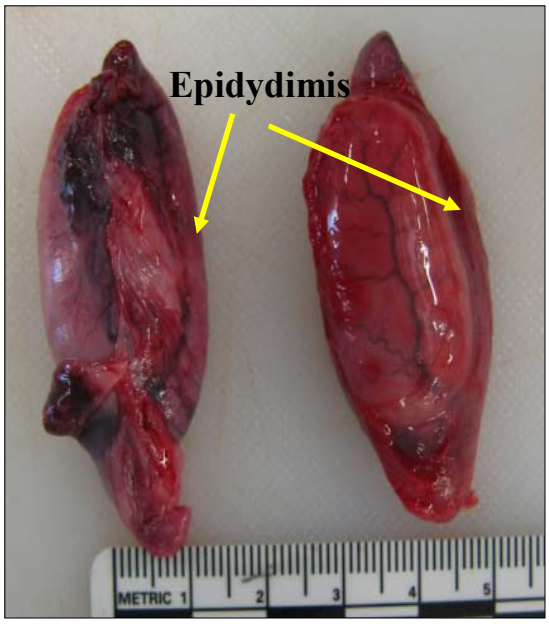

Stomach:

To ensure a thorough analysis of stomach contents, it is necessary to tie off both ends of the stomach prior to extracting, so that no material is lost during the removal process. With some twine, tie a tight, secure knot at the location of the attachment of the esophagus to the stomach. A second piece of twine can be tied just below the base of the stomach where the small intestine begins. Remove the stomach from the carcass by cutting beyond both knots. Examine the serosal (external) surface of the stomach for discoloration and lesions. If an internal pathology is present, the perigastric lymph nodes attached to the stomach may be noticeably enlarged and reactive. Sample the lymph node for histology and make note on the sample inventory sheet. Otherwise, remove all excess attached tissue from the exterior of the stomach and weigh the stomach full. Using a scalpel, make an incision through the wall along the greater curvature large enough to allow examination of the contents and entire mucosal surface (Figure 3-50). Note the composition of stomach contents (fluid; whole or partially digested fish; fish bones; parasites; foreign objects). Be sure to describe amounts, color, and texture. Before further manipulation, collect a sample of contents for biotoxins. The remaining contents can be emptied and rinsed into a sieve to ensure solid materials are not lost and are thoroughly

Figure 3-50. Stomach removed from carcass.

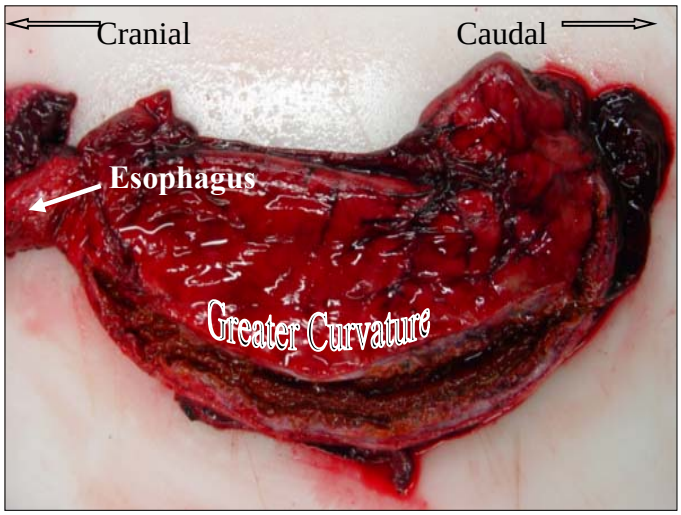

examined. Photograph and save all foreign objects for human interaction documentation. Collect and store the remaining solid materials as outlined in the Sample Management section (Section 2) of this manual.

Once empty, examine the lining of the stomach (Figure 3-51). Note the color and texture of the mucosa. Look for ulcers, areas of discoloration, parasites (such as the nematodes shown in this image), and other lesions. Weigh the stomach empty. Sample for histology.

Figure 3-51. Stomach is incised along the greater curvature and reflected to demonstrate prominent folding of the lining (gastric rugae).

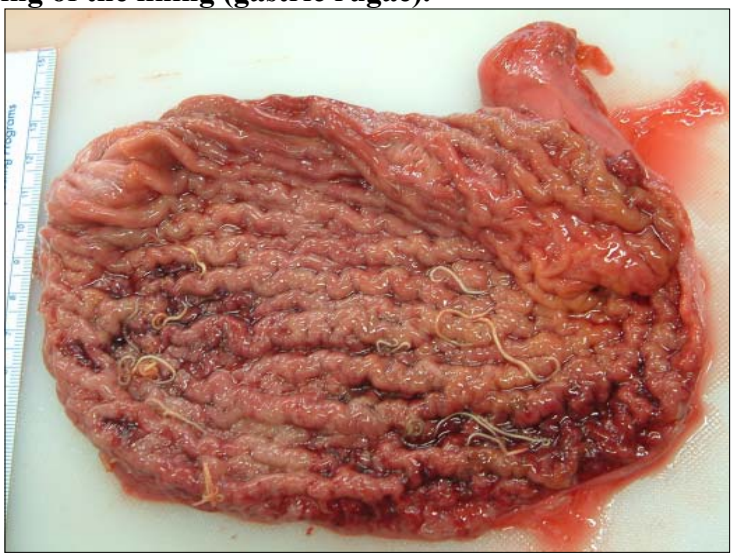

Esophagus:
Trace the esophagus from the exposed caudal end to the mouth. Open the esophagus in the same manner as done with the trachea. Observe the lining of the esophagus. Note, color, texture, and contents. Sample for histology.

Small intestine:
Examination of the intestines is preferably left until the end of the necropsy so as to not contaminate the other organs. Examine the serosal surface of the small intestine first. Look for areas of hemorrhaging or discoloration as well as parasites. The inside of the small intestine can be examined by spot checking: at 5 – 10 random, separate areas, using scissors to cut about 10.0 cm down the length of the lumen. Note color, consistency and amounts of contents as well as thickness of the lumen and texture and color of the mucosa. Sample several sections for histology, microbiology, molecular and ancillary investigations.

Large intestines:
To locate the beginning of the large intestine, look for the ileo-ceco-colic junction, which usually is a ridged junction between the smaller diameter small intestine and the larger diameter large intestine. The large intestines can be examined in the same manner as the small intestines. Note any discoloration or the presence of parasites externally. Describe the color, consistency and amounts of contents. Note the thickness of the lumen as well as texture and color of the mucosa. Sample for histology, microbiology, molecular, and ancillary investigations.

Colon:
Examine the serosal surface of the colon for areas of discoloration. Cut through the lumen of the colon from the anus to the large intestine. Describe the color, consistency and amount of contents. Note the thickness of the lumen as well as texture and color of the mucosa. Sample for histology. Collect feces for biotoxin analysis.

Removal of the Brain:
The brain is the most fragile and easily disrupted tissue in the entire body, thus extreme care must be taken when removing the brain from the case. Before removing the head, cerebrospinal fluid (CSF) can be collected for cytology and culture. To do so, remove the overlying soft tissue at the back of the head and neck to gain access to the atlanto-occipital joint. Insert a sterile needle and syringe and collect the clear, viscous CSF.

The head must first be detached from the body to safely remove the brain. Do so by cutting behind the base of the skull down between the occipital condyles and first vertebra (Figure 3-52). It is easier to separate at this joint while pulling the muzzle toward the ventrum. Once separated, remove all excess skin, blubber, muscle and connective tissue from around the dorsal and caudal skull. Then, using a Stryker saw or a hacksaw, make cuts from left to right through the middle of each occipital condyle, then up along the left and right lateral skull, and then across the dorsum, just caudal to the marked transverse ridge at the apex of the skull (Figure 3-53). The connecting cuts on the surface of the skull will create the shape of a pentagon (Figure 3-54). Be sure to fully penetrate the bone, but avoid penetrating the brain tissue. This can be very difficult, so proceed with caution. It will take some practice to successfully remove the cranium without penetrating the brain. Carefully place a chisel between the cut bone and turn the tool to crack the remaining bone until the back of the skull comes away in one piece. Be careful to pull it off evenly, without using one edge as a lever, otherwise the bony shelf (the tentorium cerebellae) that is positioned between parts of the brain will penetrate the tissue and damage the brain. Using your fingers to bluntly dissect, gently tease the meninges away from the skull, and work under the brain to sever each cranial nerve. Inversion of the head often allows the brain to gently descend into the palm of your hand.

Figure 3-52. Separation of the skull from the first vertebrae.

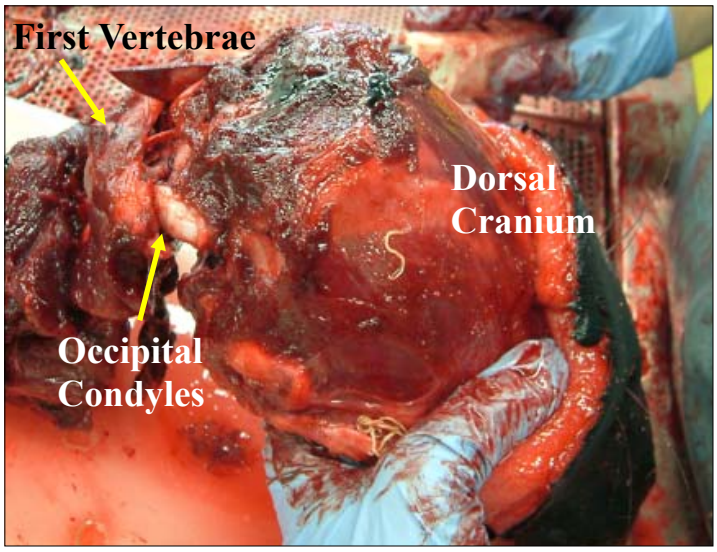

Figure 3-53. Left lateral view of the flensed skull.

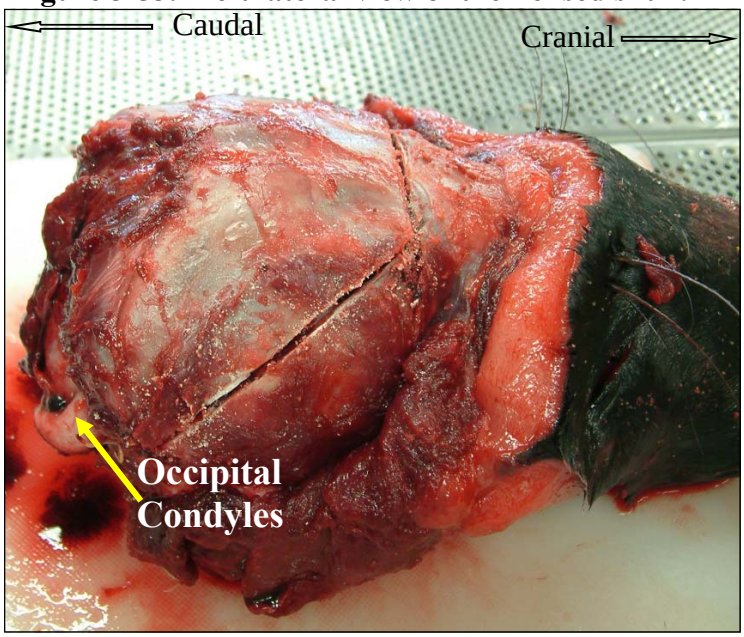

.

Examination of the Brain:
Again, the brain is the most delicate tissue in the body and will fall apart if handled excessively. Observe the external surface of the brain and note symmetry of each distinct structure, color, texture, and presence of worms or lesions. Cut through the brain, cranial to caudal, separating the two hemispheres. Again, note symmetry, color, texture and the presence of worms or lesions. Each section of the brain has a diffusely distinct pattern. The cerebrum is comprised of two separate lobes and is the most anterior section of the brain. The cerebellum is the most caudal portion and sits dorsal to the brain stem. The brain stem originates from the ventral midline of the brain and extends into the spinal cord. Sample the cerebrum, cerebellum, brain stem and spinal cord for microbiology, molecular and ancillary investigations. Fix the remaining brain tissue in formalin for histology. It is important to include a sample of normal and abnormal meninges in the histology sample set.

Figure 3-54. Incised skull with reflection of the cap to expose the brain in situ.

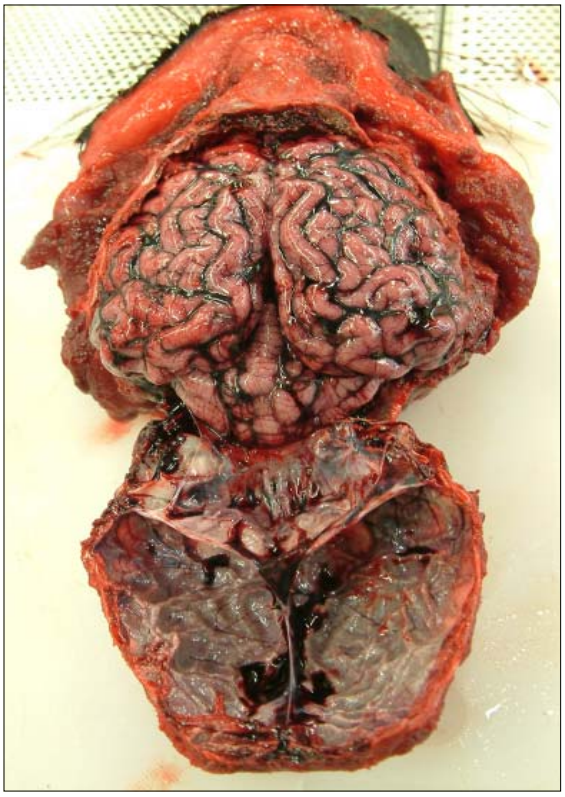

Figure 3-55. Gross Description: Thick, dark blood within the folia of the cerebellum.

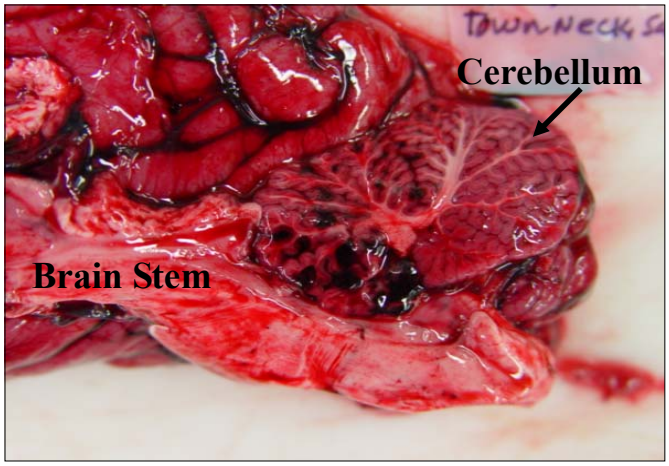

Morphological Diagnosis: Punctate foci of acute hemorrhage.

Pituitary Gland:
Once the brain has been removed, immediately under the crossover of the optic nerve, the usually small pituitary gland can be extracted after incision through the overlying dura. The organ is within a bony recess and has to be lifted out using a scalpel blade and small forceps. Sample for histology and other priority testing.

- SECTION FOUR -
Small Cetacean Necropsy Technique and Anatomy

As a reminder, it is helpful to have all necessary equipment and sampling needs set up and accessible prior to the start of the necropsy. A sample equipment list is provided in Appendix C of this manual

Stranded cetaceans are out of habitat and undergo resultant pathology simply by the stressful act of being ashore. Such changes include epidermal lacerations and tendon, ligament, blubber and muscle bruising. Lungs and other major organs are also compressed and may contain abnormal amounts of fluid, especially on the dependent side. These factors should be considered throughout the exam.

External Exam

Condition Code:

Before initiating the necropsy, carcass condition must be determined. Preferably, necropsies are performed on fresher carcasses (within 48 hours of death); however, environmental conditions can greatly impact condition code. For example, very warm weather will accelerate carcass deterioration. If human interaction is suspected or forensic data are of value, necropsies should be performed irrespective of tissue quality. Carcasses are classified in one of five code categories depending on the level of decomposition:

Code 1: Alive

Code 2: Fresh carcass (Figure 4-1); < 24 hours post mortem; normal appearance, usually with little scavenger damage; fresh smell; minimal drying and wrinkling of skin, eyes and mucous membranes; eyes clear; carcass not bloated, tongue and penis not pro-

Figure 4-1. Fresh carcass

Code 3: Moderate decomposition (Figure 4-2); Carcass intact, bloating evident (tongue and penis protruded) and skin cracked and sloughing; possible scavenger damage; characteristic mild odor; mucous membranes dry, eyes sunken or missing;

Figure 4-2. Moderate decomposition

Code 4: Advanced decomposition (Figure 4-3); Carcass may be intact, but collapsed; skin sloughing; often severe scavenger damage; strong odor; blubber or muscle easily torn or falling off bones; liquefied internal organs.

Figure 4-3. Advanced decomposition.

Code 5: Mummified or skeletal remains (Figure 4-4); often with dried skin draped over bones; completely desiccated.

Figure 4-4. Mummified or skeletal remains.

Nutritional Condition:

The body condition of a cetacean can be assessed by looking along the dorsal axis of the animal. The dorsal muscle mass (epaxial muscle) to either side of the dorsal fin of a **robust** animal will be rounded, or convex (Figure 4-5). A **thin** animal will have a slight loss in epaxial muscle girth and could have a minor sunken aspect to the dorsal-lateral body. An **emaciated** animal (Figure 4-6) will have a greater loss of epaxial muscle girth and will be concave down the dorsal-lateral body. Emaciated animals may also have a more prominent indentation at the nape.

Figure 4-5. Robust cetacean

Figure 4-6. Emaciated cetacean



Sex determination:

To determine the sex of a small cetacean, examine the ventral midline of the animal. Both male and female cetaceans possess a genital slit between the umbilicus and anus. For female cetaceans, there should generally be less than 10 cm distance between the centers of the anal opening and the genital slit (Figure 4-7). Whereas with a male, the distance between the anus and genital slit is much greater (Figure 4-8). The distance between the genital slit and anus is most pronounced in the male harbor porpoise, in which the genital slit lies closer to the umbilicus than to the anus. A single short mammary slit can be seen on either side of the genital slit in most female cetaceans, though some males may also possess this feature. A more definitive method to sex a cetacean is by blunt-probing the genital slit. If the probe angles forward it has entered the vagina and is, thus, a female. If the probe angles backward it has entered the penile opening of a male (often the distal end of the penis can be felt as well). When probing, be sure that your finger has penetrated past the first knuckle in order to ensure accurate sex determination. It is important to note also, that different species are easier to probe than others; common dolphins are often quite difficult to accurately probe due to very small genital apertures. Final confirmation of gender will always be a result of internal examination.

Figure 4-7. Female delphinid

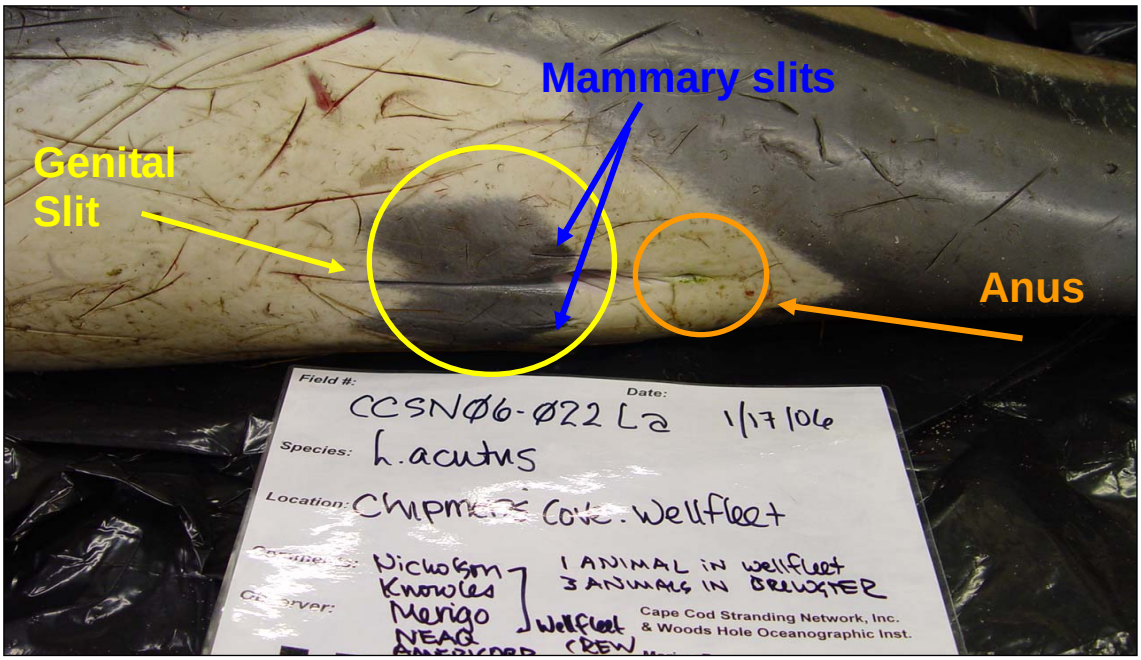

Figure 4-8. Male delphinid

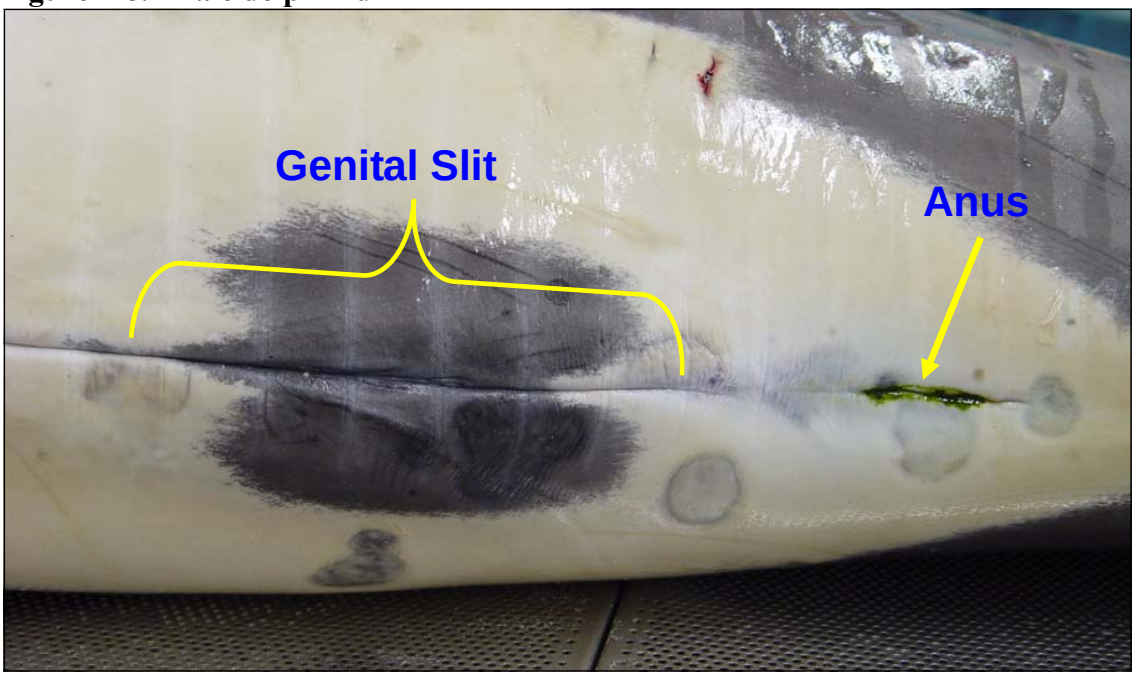

Integument:

Where collecting samples for analysis is prompted, please refer to Section 2: Sample Management.

An external examination should include the investigation and description of the eyes, mouth, blowhole, umbilicus, genital opening, anus, and skin. When examining the eyes, look for discoloration, injuries, or discharge. Document any lesions, parasites, and the mucus membrane color in the mouth. Make note of worn, broken, or missing teeth. Describe color and amount of discharge from blowhole as well as the presence of parasites or obstructions. Obtain culture swabs. Examine the umbilicus in neonates for signs of infection and degree of healing. Look for lesions, discharge or growths around the genital opening and anus. Obtain samples of abnormalities for histology, microbiology, molecular and ancillary investigations. If the animal has mammary glands, attempt to express milk and note color, consistency, and estimate amount in cc's or mls. Milk can be expressed by pressing on the body about 10cm dorsal and cranial to the mammary slit and massaging downward toward the slit. Thoroughly examine and document any scars, abscesses, ulcerations, erosions, wounds, and parasites on the skin. Make note of the size (length x width x depth/height), shape, color, texture, location, and distribution of all abnormalities. Sample unusual findings as described in Section 2: Sample Management .

Figure 4-9.

Figure 4-9. Gross Description: Multifocal to coalescing, demarcated 0.5-3.0cm circular, yellow depressions over the caudal ventral skin.

Morphologic Diagnosis: *Granulomatous dermatitis or fungal dermatitis.

Figure 4-10.

Figure 4-10. Gross Description: Multifocal to coalescing, circular, 0.1cm pits of the epidermis with central ulceration of the wound in the left example and scarring in the right example.

Morphologic Diagnosis: Peracute, acute, and chronic lamprey bites.

Figure 4-11.

Figure 4-11. Gross Description: Focal 0.5-4.5cm well demarcated light gray depressions of the dermis proximal to the genital region

Morphologic Diagnosis: Dermatitis and panniculitis with intralesional cestodes; Etiology: *Monorygma sp.*

Figure 4-12.

Figure 4-12. Gross Description: On the dermis of the lateral left body there is a dark gray to black, stippled pattern with a well demarcated, irregular perimeter, multifocal to coalescing.

Etiologic Diagnosis: Pox-viral dermatitis (tattoo lesion).

Figure 4-13a. **Figure 4-13b.**

Figures 4-13a & 13b. Gross Description: Multifocal 0.2 - 0.4cm, circular, volcanic lesions disseminated over the dermal surface; some depressions are ulcerative.

Etiologic Diagnosis: Dolphin pox

Figure 4-14.

Figure 4-14. Gross Description: Epithelial proliferation characterized by multiple fungiform, pappillomatous, semi-firm, tan to brown projections; cyamids attached.

Morphologic Diagnosis: Dermal papilloma with secondary cyamadiasis.

Skin & Teeth Sampling:

Skin:
Remove about two inches of skin from the tip of the dorsal fin (Figure 4-15) or flukes for genetic (frozen and DMSO) and histology samples. A skin sample with no blubber attached is preferred. Trim the skin as cleanly as possible from the other tissue. (Be sure all morphometrics have been completed before collecting this sample.)

Figure 4-15. Skin is removed from the dorsal fin tip for sampling.

Teeth:
Teeth from the center of the lower left mandible are collected for life history analysis. Using a scalpel blade, transversely cut in between and around 5 -7 teeth (Figures 4-16& 4-17). Teeth can be extracted by inserting tooth extractor or a flat head screwdriver in the incision made between the teeth and wiggling the tool down to the base of the mandible until the entire, undamaged, tooth becomes loose (Figure 4-18). Avoid snapping or crushing the tooth, as such damage can render the sample useless for analysis. In some species and in older animals, a sturdy knife may be advisable over a scalpel to avoid breaking the blade.

Figure 4-16. Removal of lower left teeth.

Figure 4-17. Removal of lower left teeth.

Figure 4-18. Removal of lower left teeth.

Removal of the External layers –Skin, Blubber, Muscle

Skin & Blubber:

The first step to examine the body cavity of the animal is removal of the blubber. Position the animal left side up. Using a scalpel blade or knife, start just left of the dorsal midline posterior to the blowhole and make a longitudinal incision down the length of the animal ending at the dorsal tail stock. Do not penetrate into the skeletal muscle, cut only through the skin and blubber layers. Next, make a dorso-ventral incision perpendicular to the previous body length incision just cranial to the anterior insertion of the left pectoral flipper. Continue making perpendicular incisions down the length of the animal that are ~ 10 inches apart, creating a series of panels along the lateral body (Figure 4-19). At the top of each panel begin to separate the blubber from the muscle by cutting through the fascia, or connective tissue (Figure 4-20). If you remain between the blubber/ muscle interface (fascia) and reflect the panel of skin down and away from the body, in a dorsal to ventral direction, the blubber should easily separate from the muscle (Figures 4-21 & 4-22).

Figure 4-19. Animal in lateral recumbency with numerous transverse, full blubber thickness incisions.

Figure 4-20. Reflection of the blubber along fascial plane.

Figure 4-21. Reflection of the blubber along fascial place.

Figure 4-22. Panels of blubber reflected away from carcass.

Note the thickness, color, and texture of the blubber. Look for parasites and abnormalities within the blubber layer. Obtain blubber samples for histology and contaminants. When collecting these samples, be sure to collect blubber without any skin (Figure 4-20) or muscle attached and be sure to take the sample from the same location on each carcass, generally from the dorsal mid-thoracic region. Once the blubber has been examined, make a cut along each reflected panel at the ventral midline and discard the blubber.

Figure 4-23. Separation of skin from blubber.

Figure 4-24. Gross Description: Multifocal, spherical, white to yellow cysts.

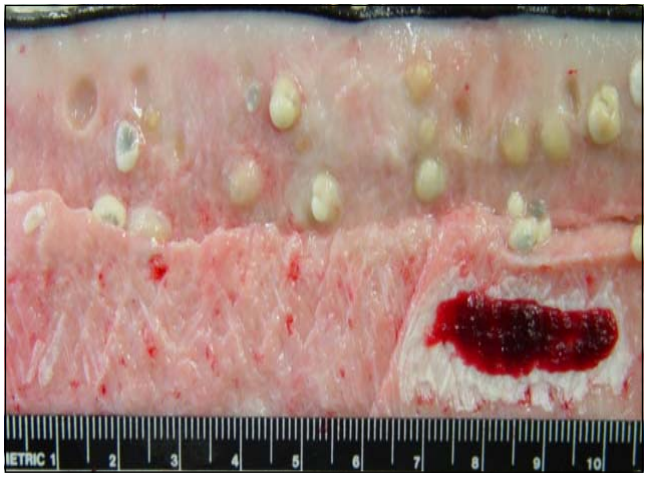

Morphologic Diagnosis: Pannicular parasitic cysts; **Etiology**: *Phyllobothrium sp.*

Figure 4-25. Gross Description: Light yellow to brown worms within the blubber-muscle fascia with associated tissue necrosis.

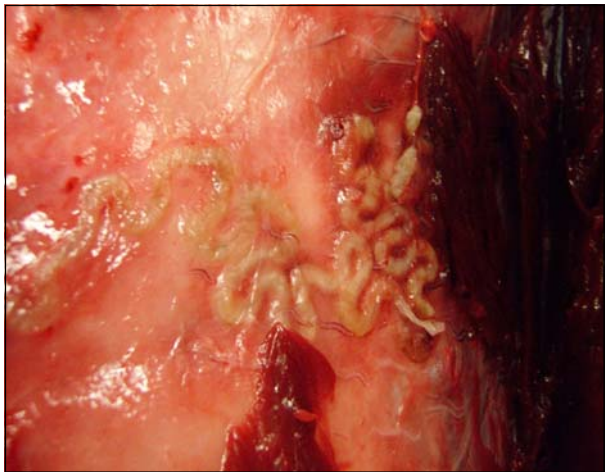

Etiologic Diagnosis: Fascial nematodiasis; **Etiology:** *Crassicauda* sp.

Figure 4-26.

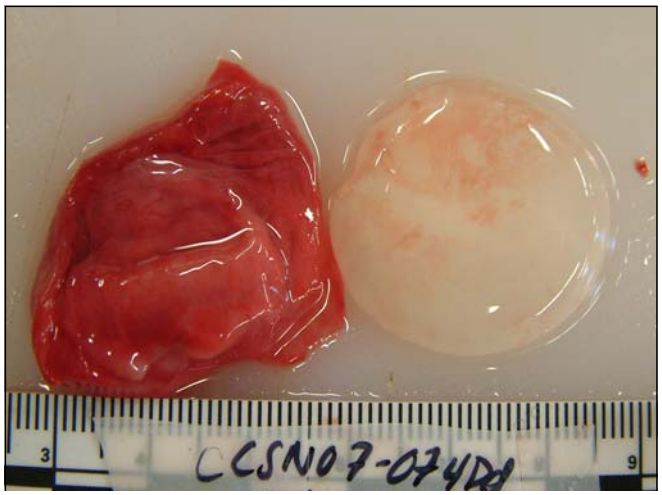

Figure 4-26. Gross Description: 3.0cm spherical pink sack attached to external abdominal muscle; contains an opaque white, gelatinous circular structure.

Etiologic Diagnosis: *Monorygma sp.*

Figure 4-27.

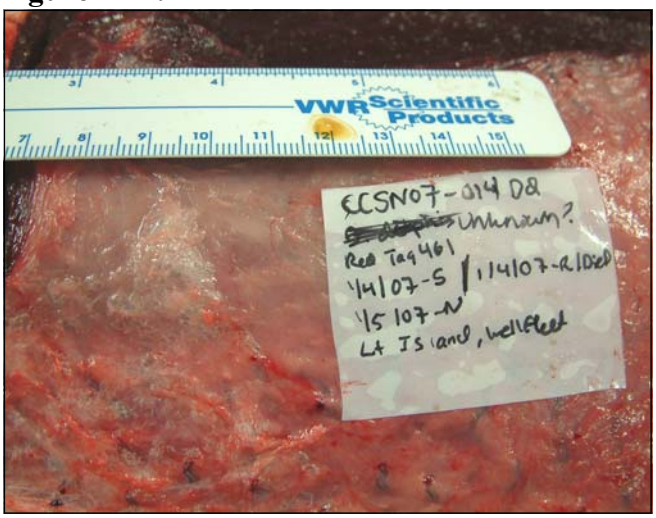

Figure 4-27. Gross Description: Multifocal to coalescing bubbles within the blubber-muscle fascia.

Morphologic Diagnosis: Most commonly gas produced by bacteria during decomposition; can also be localized gas emboli.

Figure 4-28.

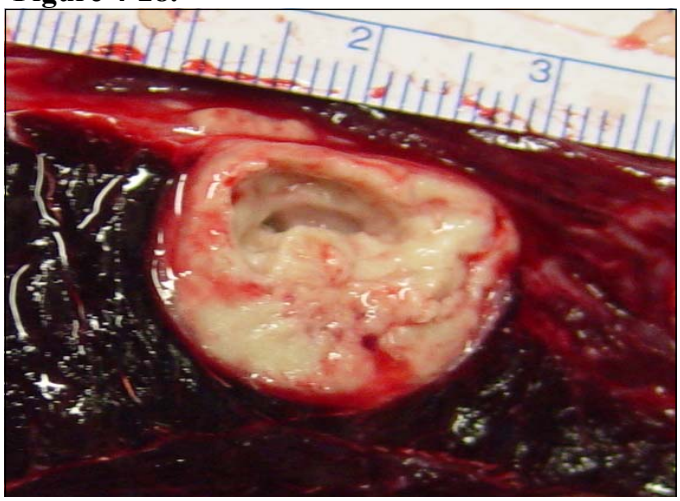

Figure 4-28. Gross Description: 2.0cm spherical abscess within the ventral midline muscle layer slightly penetrating the abdominal wall; abscess is comprised of light green caseous material.

Morphologic Diagnosis: *Focal abscessation;

Skeletal Muscle:
Examine the quality of the fascia and muscle on the body before removing it. Note the color, texture, thickness and abnormalities. Look for hemorrhage, post mortem pooling of blood in vessels (hypostasis or post mortem lividity) and bruising (hematoma). Bruising usually has a gelatinous texture and is deep maroon to purple. Remove the large dorso-lateral muscle mass, or epaxial muscle that spans from the occipital ridge down to the tail stock (Figure 4-29). Use the dorsal and lateral spinal processes as landmark boundaries for this muscle. Trim away as much muscle as possible from the backbone and ribs. Obtain muscle samples for histology and contaminants.

Figure 4-29. Removal of epaxial muscle mass.

Internal Examination

Removal of the Scapula and Prescapular Lymph Node:
Locate the prescapular lymph node prior to the complete removal of the scapula. The oval to triangular shaped, beige to peach tissue is located just underneath the cranial corner of the scapula, proximal to the location of the external ear (Figure 4-30). Normal lymph nodes throughout the body usually share the same characteristics: a well defined oval shape, slightly firm texture, color is diffusely beige to peach, with very slight differentiation between the cortex (outer layer) and medulla (center area). If the tissue begins to vary from the homogenous peach to tan it is indicative of a reaction. Note the size, shape, color and texture of the prescapular lymph node. Be sure

Figure 4-30. Location of prescapular lymph node in situ.

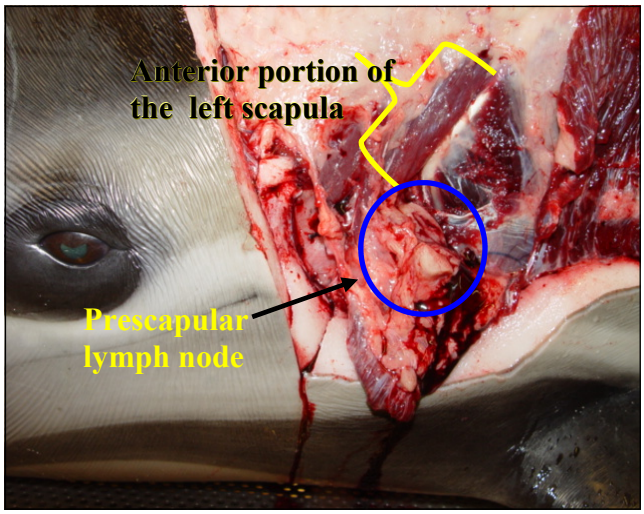

Figure 4-31. Removal of scapula.

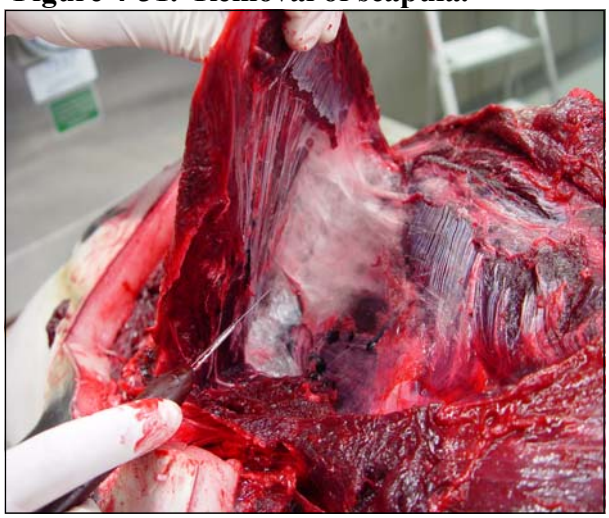

to distinguish changes of the cortex from changes of the medulla. Sample for histology, microbiology, molecular and ancillary investigations. Remove the left scapula and appendage by cutting through the connective tissue and muscle just underneath the bone. If you pull the scapula ventro-laterally, reflecting it down as done with the blubber layer, the scapula will detach easily (Figure 4-31). You should hear a crackling sound as you pull and cut indicating that you are in the correct spot between muscle groups.

Before cutting into the body cavity of an animal, to obtain uncontaminated bacterial and viral samples from the thoracic and abdominal cavities, sear a section of the body surface with a flame (such as from a propane torch), then, with a flamed blade, incise into the body cavity and insert a swab.

Removal of the Rib Cage:

Before collecting any samples or cutting the ribs, the diaphragm should be punctured with a scalpel or scissors and deflation should be noted. If the diaphragm is already deflated, it is possible that a pneumothorax or severe pneumonia may be present. To open the thoracic cavity, start at the caudal end of the left rib cage and feel for the articulation between each individual rib and vertebrae. The ribs and vertebrae should easily separate, without breaking, if you cut through the articulation, or "sweet spot", with a scalpel blade or small knife (Figure 4-32). Also to note, age and disease may effect the way the joints disarticulate. Move cranially from rib to rib maintaining a constant angle with your scalpel as you cut and moving the rib to find the articulation (Figure 4-33).

Figure 4-32. Separation of the ribs at the costal articulation.

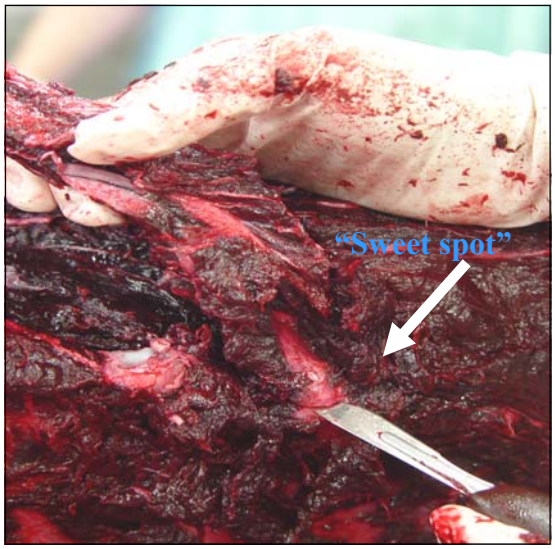

Figure 3-33. Removal of ribs at sternum articulation.

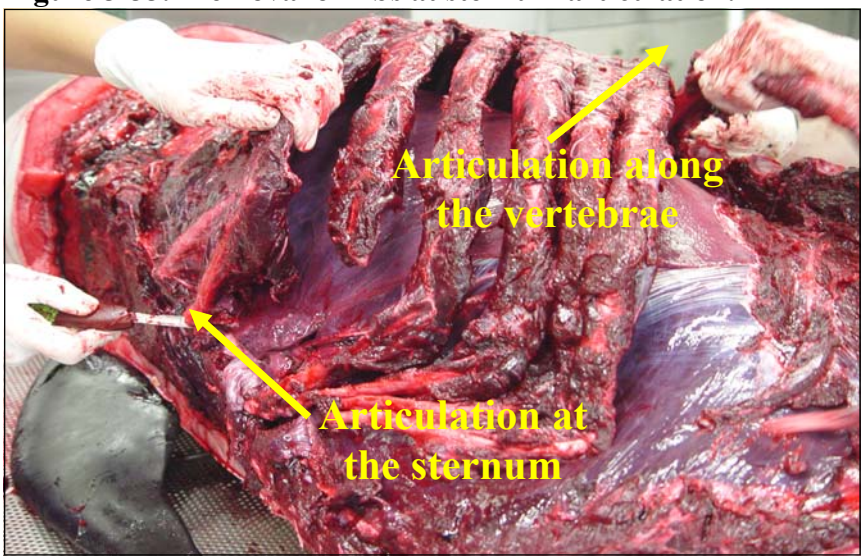

Note that the most cranial ribs are double-headed along the vertebrae (Figure 4-34). The double-headed ribs can be removed by first severing the first articulation, then by sliding the scalpel along the inside of the second head to reach its articulation with the spine. The articulation can be cut by sweeping the scalpel parallel to the long axis of the animal. The rib articulations should feel smooth, not granular. Feel for fractures and bone spurs on the rib cage. Removed in this manner, the skeleton may be of more value for future bone pathology studies, educational outreach or as museum specimens. Once the rib cage is removed, examine the body cavity with all organs in place (Figure 4-35). Note any discoloration, lesions, adhesions, odor, or fluids.

Figure 4-34. Double articulation along the vertebrae.

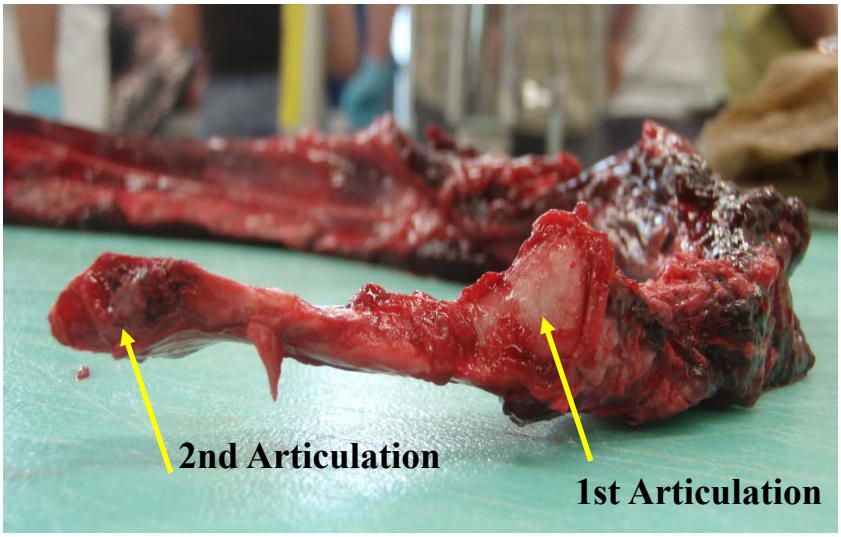

Figure 4-35. View of viscera with ribs removed.

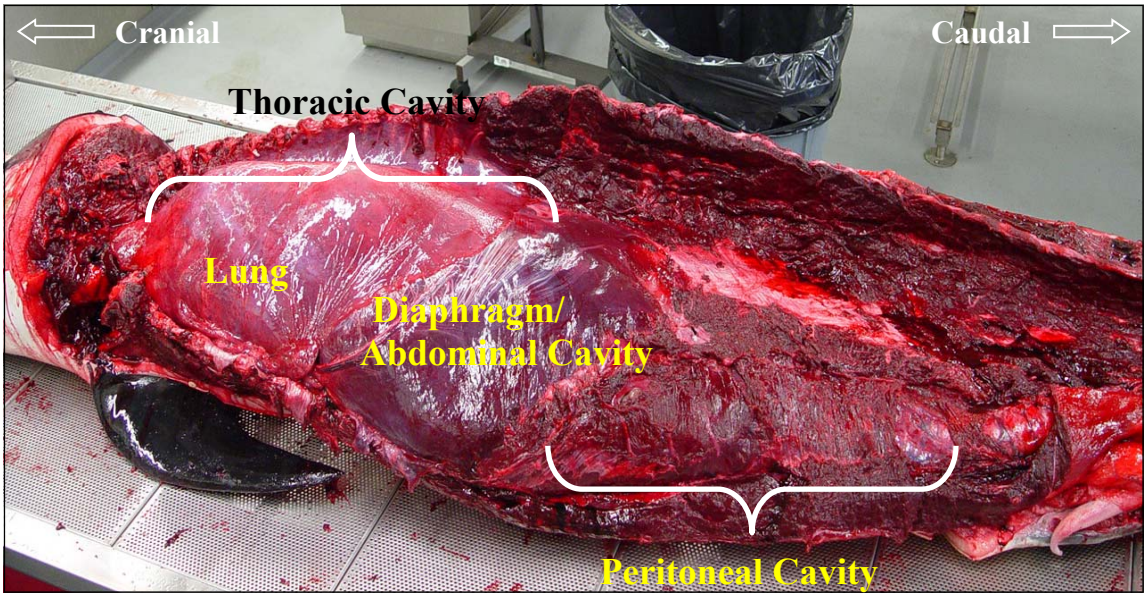

At this point, one needs to adhere to a systematic examination of the internal tissues. The organs may be removed as a pluck, or may be examined in situ. The method of sampling can be guided by sampling needs, condition code, and personal preference. It is recommended that internal fluids, such as those in the gastro-intestinal system do not contaminate other tissues.

Thyroid:
The thyroid sits ventrally on the cranial trachea and spans the width of the trachea. The thyroid is one of the more difficult tissues to locate and identify. The color and texture are often similar to smooth muscle. The parathyroid is a small, light colored tissue attached to the thyroid along the cranial margin of the thyroid and can aid in correct tissue identification if it can be found. Examine the tissue externally and internally. Note the size, shape, color and texture. Sample for histology, microbiology, molecular and ancillary investigations.

Thymus:
The thymus is a large, lymphoid organ, that is primarily found in neonates and some juveniles. It is situated at the base of the thoracic inlet, cranial to the anterior margin of the heart. The primary function of this organ is to generate T-cells. The thymus is absorbed with time after weaning, thus is not usually visible in adult marine mammals. Examine the tissue externally and internally. Note the size, shape, color and texture. Sample for histology, microbiology, molecular and ancillary investigations.

Tracheobronchial (TB) Lymph Node:
The TB lymph node is located along the distal cranial ventral surface of the lung proximal to the bifurcation of the trachea. It can easily be located by reflecting the cranial lung tissue away from the cavity and palpating the connective tissue between the lung and anterior to the trachea bifurcation (Figure 4-36). It is recommended that this tissue be identified and removed prior to removal of the lung or trachea, as it can be easily lost without anatomical landmarks. Examine the lymph node externally and internally. Describe any differences between the cortex and medulla. Note any other changes in size, shape, color and texture. Sample for histology, microbiology, molecular and ancillary investigations.

Figure 4-36. Location of the TB lymph node in situ.

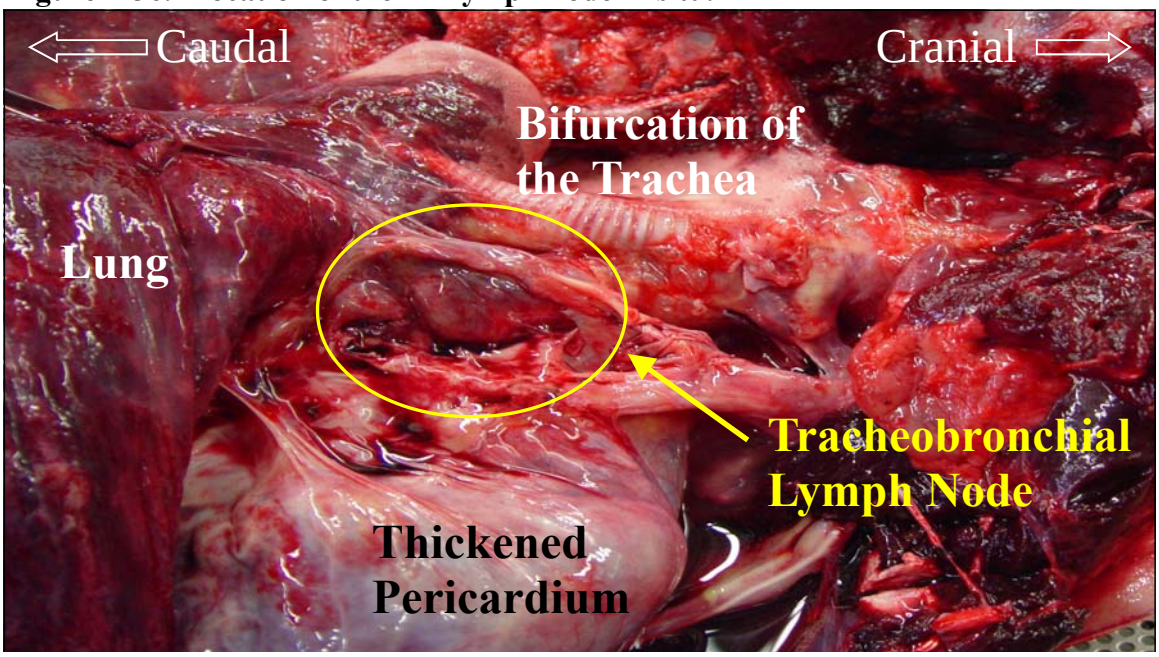

Lungs:
The lungs occupy the majority of the thoracic cavity and are the large, normally bright pink, tissue with a consistent sponge-like texture (Figure 4-37). Detach the lung from the trachea at the bifurcation. Examine the pleural surface: note color pattern, and texture. Normal, air-filled lung tissue should bounce back immediately after being depressed with a finger (like a sponge) and float when placed in water or formalin. To examine the internal structures, using scissors, trace the trachea from the bifurcation along the bronchi and into the bronchioles of each lung. Note whether fluid, froth, and/or parasites are present and describe amount, color, *etc*.). Next, make serial cuts into the tissue by "bread-slicing" (making multiple, parallel slices into the tissue) perpendicular to the long axis of the body to examine the parenchyma. This is best done with a long knife using a single sweeping cut in order to avoid tearing or serrating the lung tissue. Examine the parenchyma and note color pattern and texture. Sample for histology, microbiology, molecular and ancillary investigations.

Figure 4-37. Pleural surface of the removed lung.

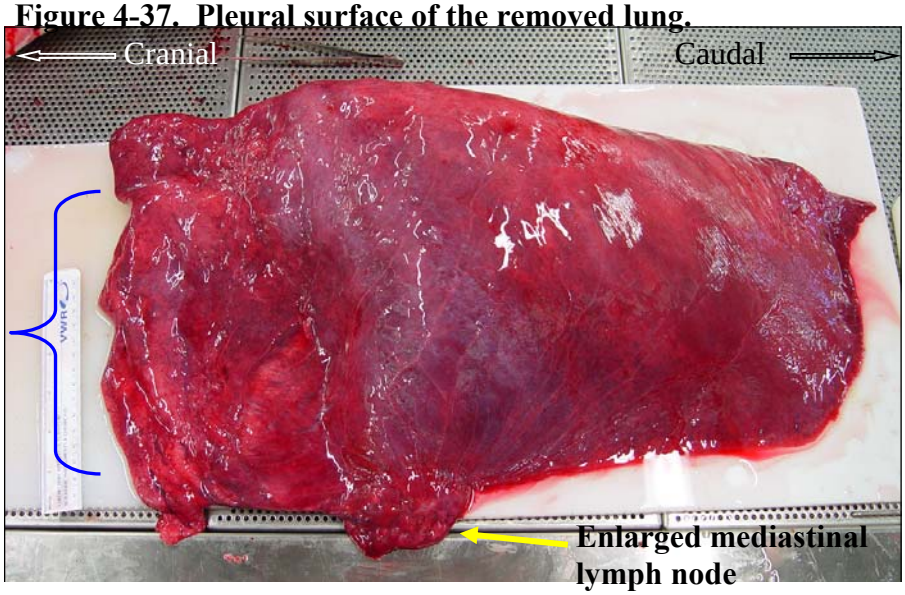

Figure 4-38. Gross Description: Multifocal, firm, light gray, variably sized nodules throughout the tissue.

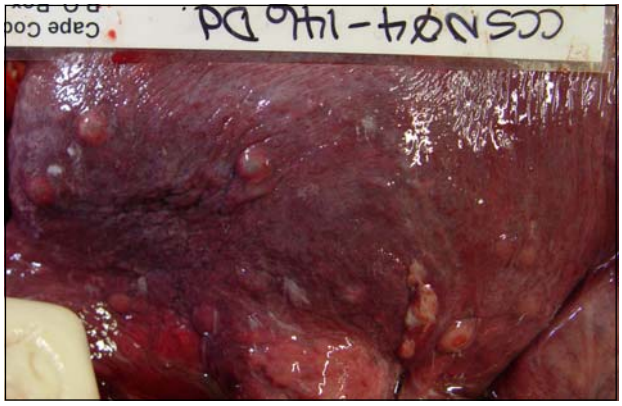

Morphologic Diagnosis: *Lymphosarcoma

Figure 4-39. Gross Description: Thick, opaque, elastic consistency of the pleura (external surface of lung).

Morphologic Diagnosis: Pleural fibrosis.

Figure 4-40. Gross Description: Distinct, firm walled, 4.5cm spherical capsule with an irregularly textured internal surface containing light green caseous material.

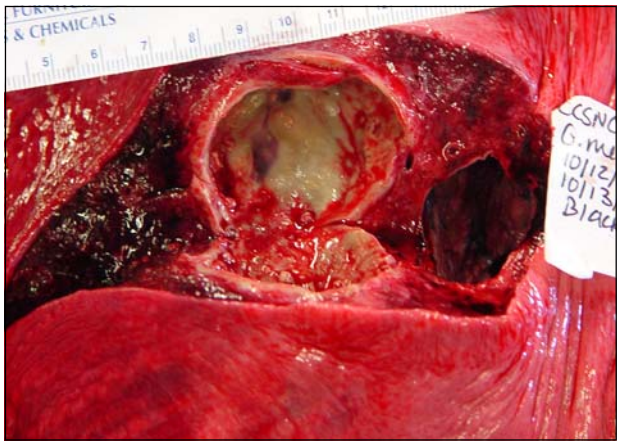

Morphologic Diagnosis: ***Aspergilloma; **Etiologic diagnosis: pulmonary aspergillosis.

Figure 4-41. Gross Description: Single, focal, well demarcated, 1.0 x 0.5 cm oval, white capsule within the lung parenchyma (internal structures).

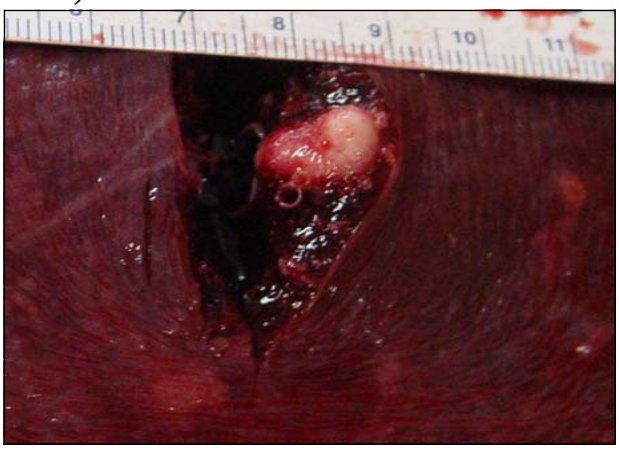

**Morphologic Diagnosis: ***Parasitic cyst

Figure 4-42. Gross Description: Large (4.5 x 4.9 1.4cm), raised, firm, light pink, capsule that contains light green muco-purulent fluid with white caseous material.

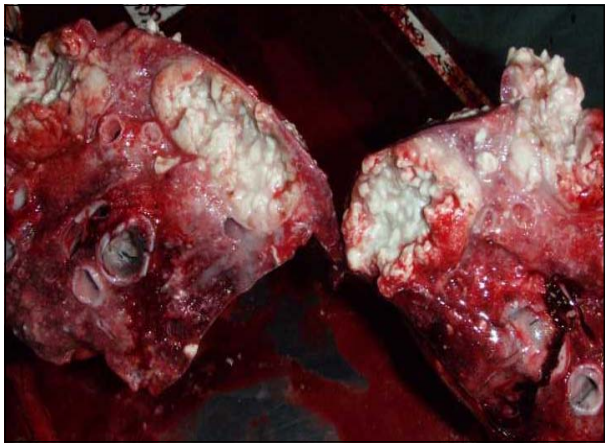

Morphologic Diagnosis: Pulmonary abscessation.

Figure 4-43. Gross Description: Multifocal, poorly demarcated, dark red tissue within the parenchyma proximal to the bronchioles.

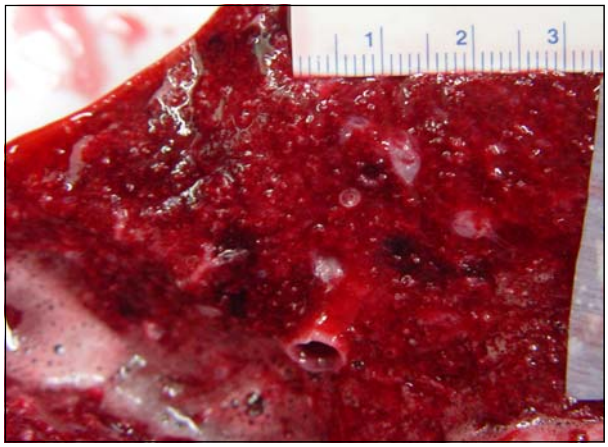

Morphologic Diagnosis: Pulmonary hemorrhage.

Trachea:

The trachea is a long, firm, off-white, flexible, ridged, tubular organ that extends from the larynx to the tracheal bifurcation. Using scissors, cut through the entire length of the trachea from the bifurcation up to the apex of the throat. Examine the mucosa and identify and describe contents (froth, fluid, blood, color, etc.). Sample for histology.

Heart Muscle and Valves:
Before handling the heart, observe and describe the pericardium. There should be a small amount of clear fluid within the pericardium to allow for lubrication. Note if there is excessive fluid and describe the characteristics. Also, note the presence of gas bubbles within the pericardium and vessels and note thickness of the tissue. Trim away the pericardium and observe the epicardium (external surface of heart) in situ. Note size, color, and texture of each structure (right and left atria and ventricles, aorta, and pulmonary vessel) (Figure 4-44). Remove the heart by cutting transversely across the aorta and pulmonary artery leaving approximately 6.0 cm of each vessel still attached to the heart muscle. There are varying techniques for examining the internal structures of the heart. One way is to use scissors to make a small opening in the cranial right atrium and cut down along the medial edge of the right ventricle down to the apex. Continue cutting along the right ventricle side of the septum until this chamber joins the pulmonary artery and cut up through the vessel. Next, snip the left ventricle side of the apex, cut through the muscle along the septum, and up through the aorta (Figure 4-45). This process leaves both sides of the heart intact.

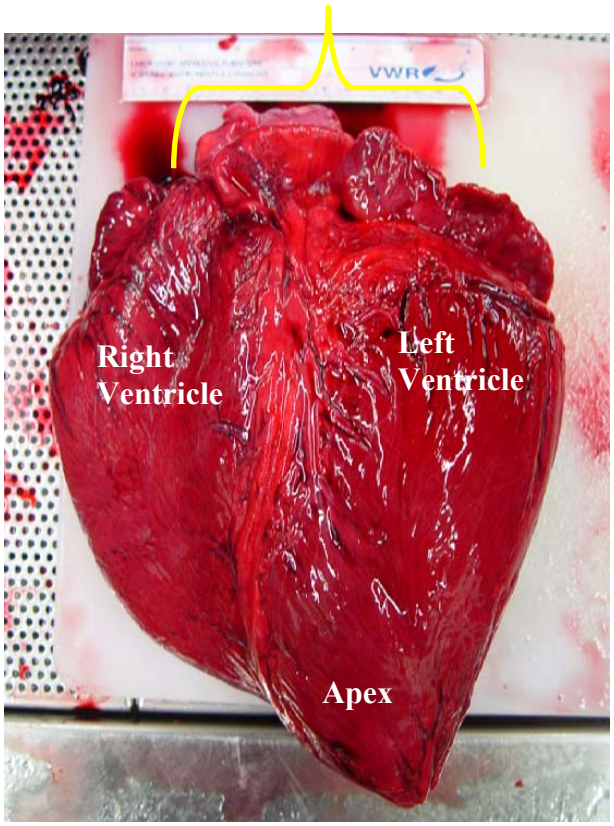

Figure 4-44. External structures of the heart.

Figure 4-45. Recommended incision pathway to open the heart.

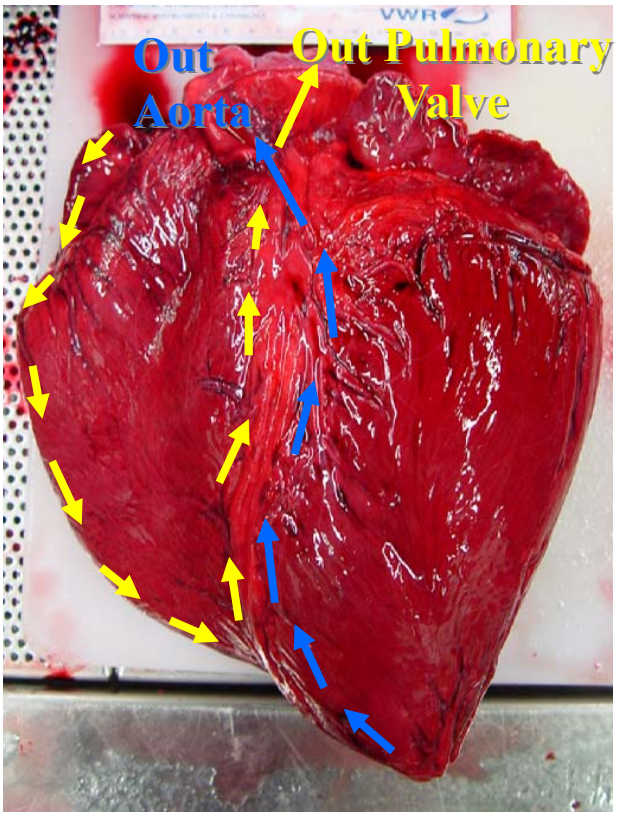

A simpler way to examine the endocardium (inner surface of the heart) is by slicing the organ completely in half starting at the apex going laterally toward the vessels, so that it opens up like a book (Figure 4-46). Examine each chamber for the presence of worms or other foreign matter. Note the size/thickness of each atrium and ventricle, as well as color and texture. The left ventricle should be substantially thicker than the right. Thoroughly examine the interior of the valves for changes in texture or thickness. Normal mitral and tricuspid valves should be thin and slightly opaque. Once the endocardium is examined, bread–slice the ventricles to examine changes in the myocardium. Sample the right and left ventricles and atria, septum, apex, atria, and aorta for histology.

Figure 4-46. View of the Endocardium; heart is opened longitudinally.

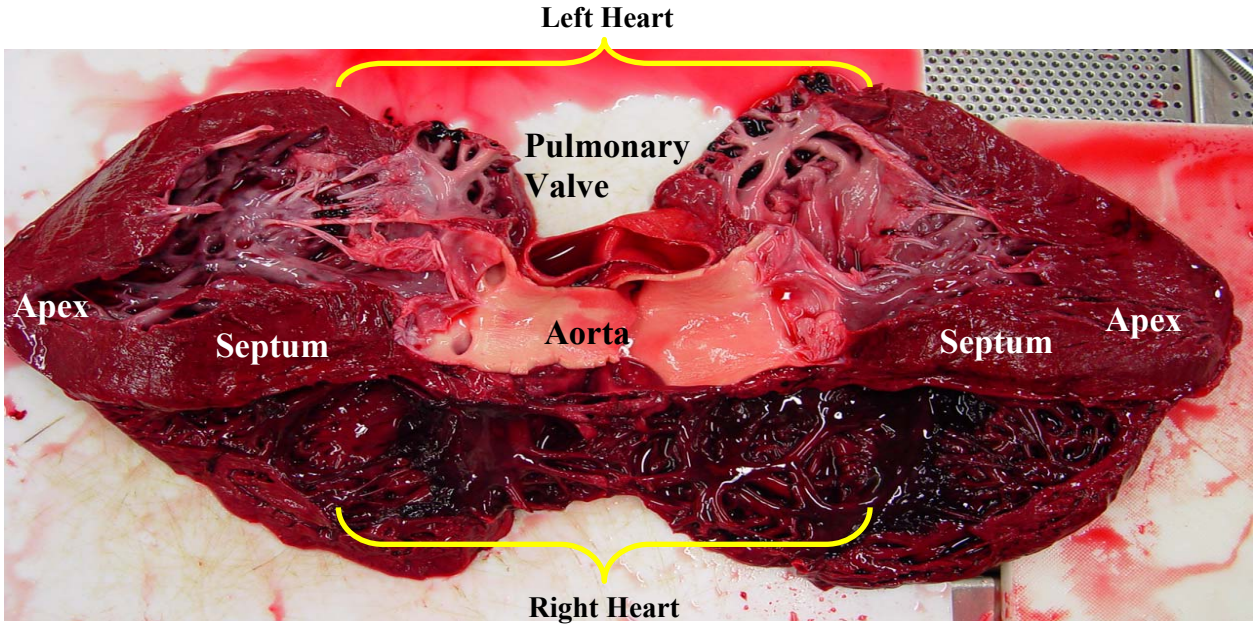

Figure 4-47. Gross Description: Translucent heart valves.

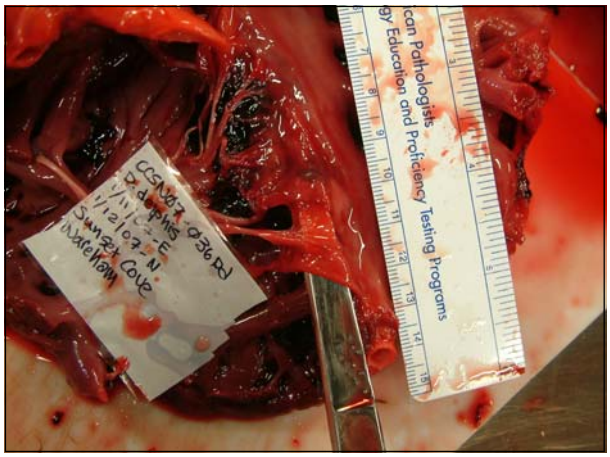

Morphologic Diagnosis: Normal A-V valves.

Figure 4-48. Gross Description: Thick, opaque, irregular textured mitral or tricuspid valves.

Morphologic Diagnosis: Valvular Endocardiosis

Figure 4-49.

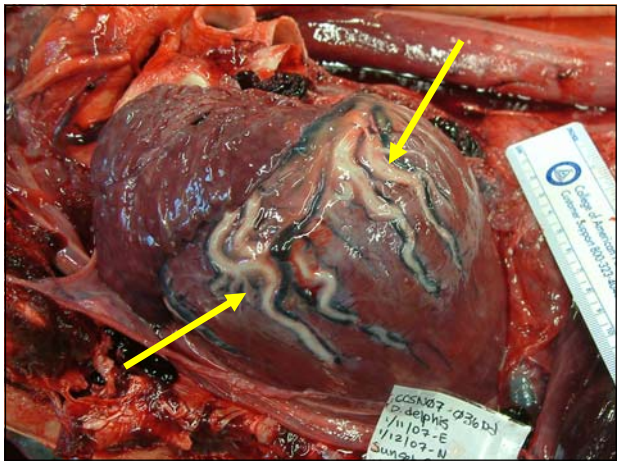

Figure 4-49. Gross Description: Thick, white, endocardial vessels.

Differential Diagnosis: Fibrosis; atherosclerosis; mineralization; or arteriosclerosis

Diaphragm:
The diaphragm is the thin, smooth textured, dark maroon, expandable muscle that is attached to the caudal rib cage and separates the thoracic and abdominal cavities (Figure 4-50). Note the texture and color as well as any tears or adhesions. White striations over the surface of the diaphragm are normal. Trim away the diaphragm enough so that there is complete access to the abdominal organs. Sample for histology.

To expose the abdominal organs, incise the abdominal wall from the last rib mid-ventral to the level of the anus. Extend the most cranial cut laterally along the thoracic arch and reflect the abdominal musculature to expose the internal tissues. The orientation of the organs should be visually assessed and any free fluids aseptically collect in a sterile syringe prior to proceeding with the internal examination.

Figure 4-50. Abdominal viscera in situ.

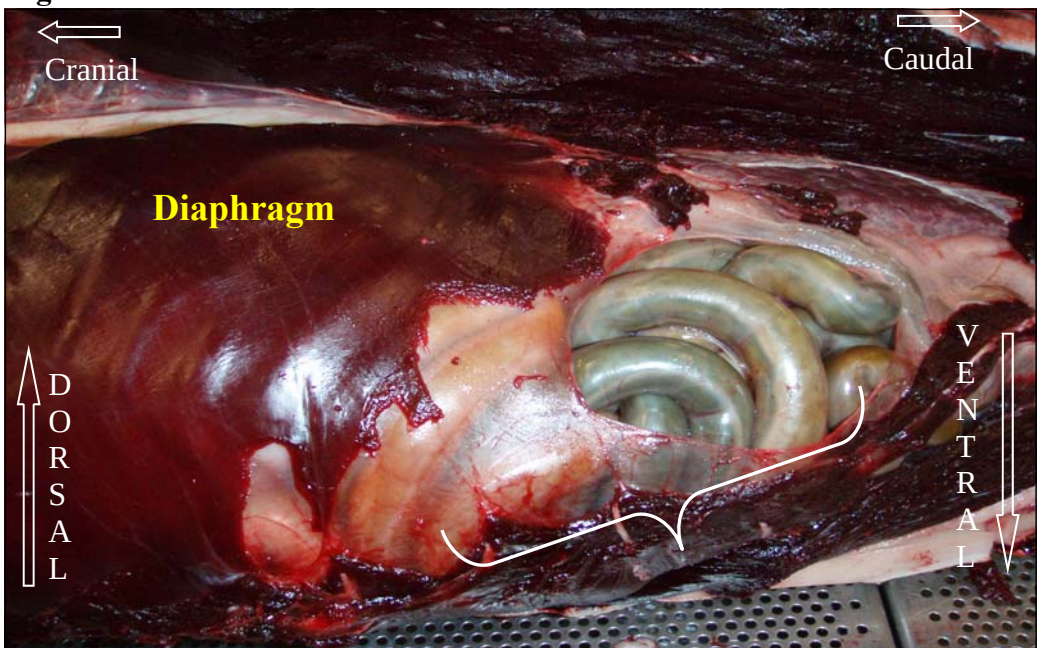

Liver:
The multi-lobular, diffusely maroon liver is large, lies over the stomach and dominates most of the abdominal cavity (Figure 4-51). Examine the parietal (toward the body wall) and visceral (toward the organs) surfaces of the liver and note color pattern, texture and size of the lobes. Examine the parenchyma of the liver by bread-slicing through the tissue. Again, note the color and texture within. Examine bile ducts for presence of parasites. Sample for contaminants, histology, microbiology, molecular and ancillary investigations. **Note: all cetaceans lack a gall bladder.**

Figure 4-51. Location of liver in situ.

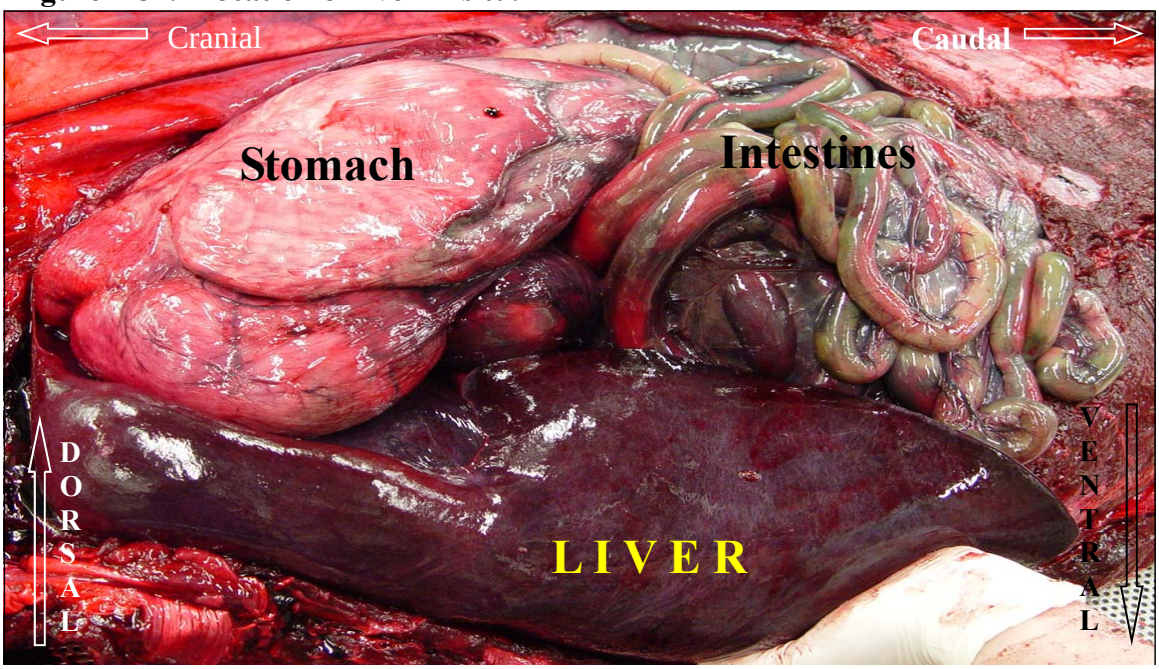

Figure 4-52. Gross Description: Multiple, translucent off-white 0.8 x 0.5cm adhesions that easily detach from the liver capsule.

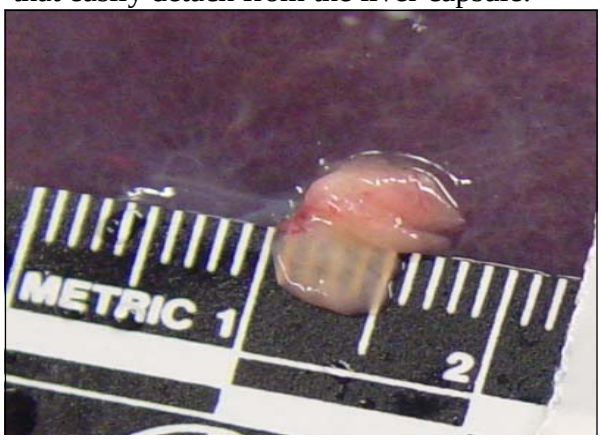

Morphologic Diagnosis: Fibrin tag

Figure 4-53. Gross Description: Multifocal to coalescing firm, cream colored nodules diffusely throughout the liver affecting >80% of the tissue.

Morphologic Diagnosis: *Lymphosarcoma

Figure 4-54.

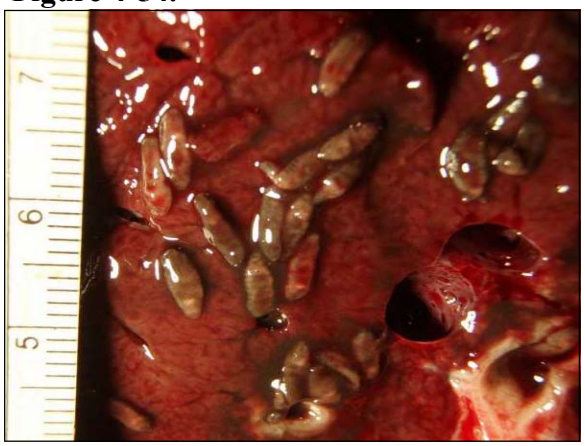

Figure 4-54. Gross Description: Approximately 15cc's of mucopurulent, light green fluid and >200, 0.5cm, flat, light green parasites exuding from the bile ducts of the liver.

Morphologic Diagnosis: Cholangiohepatitis with intraluminal trematode parasites and associated periductular fibrosis, bile ductular hyperplasia, and ductular cholestasis.

Spleen:

The shape and size of the spleen vary among cetacean species. The spleens of most delphinids are palm-sized, spherical and mottled dark purple to white with a smooth external texture. For other species, the spleen may share these characteristics or be smaller and oblong. Regardless of physical characteristics, the organ is always located underneath the main stomach toward the left side of the body (Figure 4-55). Remove the spleen by detaching it from the omentum (thin, web-like, connective tissue). Note size, shape, color, and texture of both the surface and the parenchyma of the spleen. In some cases, smaller (0.2—1.0cm), accessory spleens may be attached to the visceral surface of the spleen. These smaller spleens share the same characteristics as the larger spleen. Sample for histology, microbiology, molecular and ancillary investigations.

Figure 4-55. Stomach lifted to reveal the location of the spleen.

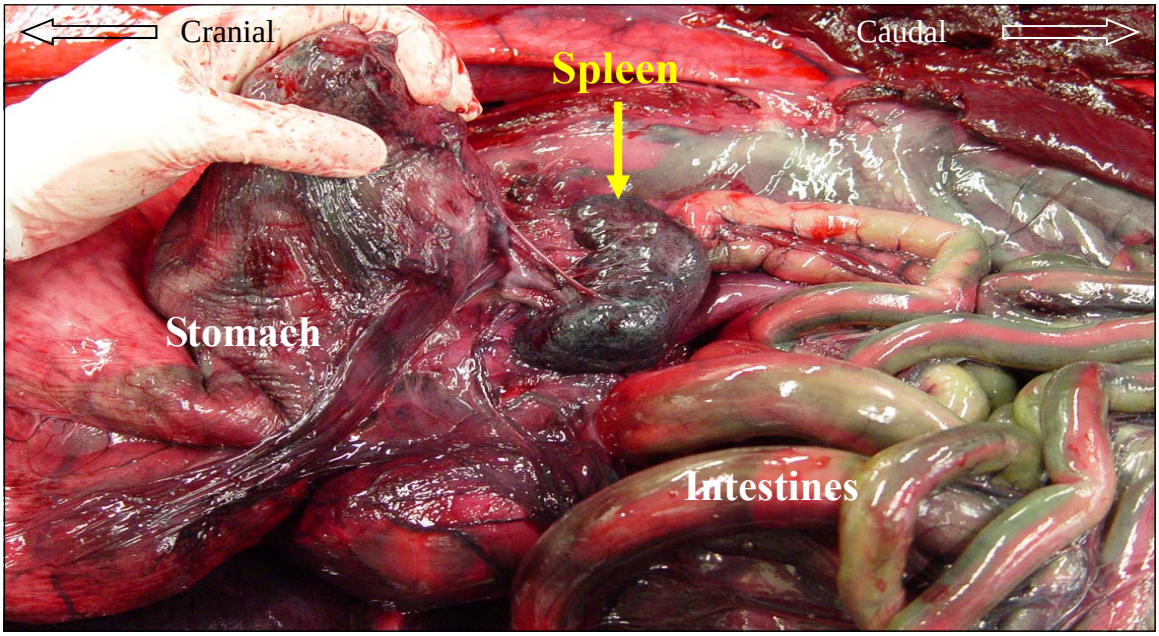

Figure 4-56. Gross Description: Multifocal, 0.5-3.0cm, firm, white nodules diffusely throughout the spleen; one half of the spleen is pink the other is purple (normal).

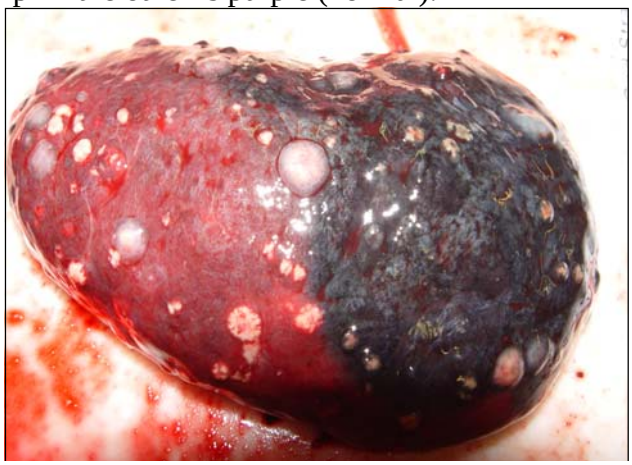

Morphologic Diagnosis: *Multifocal granulomas.

Figure 4-57. Gross Description: Multifocal, maroon, 0.1-0.3cm, circular, flat to slightly raised, superficial, foci.

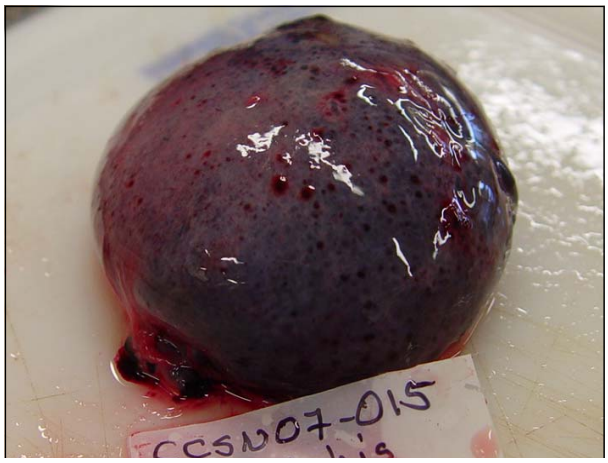

Morphologic Diagnosis: Normal, extruded red pulp

Pancreas:
The pancreas is a peach colored, irregularly shaped, pyramidal, softer tissue that is attached to the mesentery and sits in the curve of the duodenum (Figure 4-58). Remove the pancreas from the cavity by detaching it from the connective tissue and duodenum. Note the size, shape, color, and texture of the surface. Cut into the parenchyma and note changes in color or texture (Figure 4-59). Examine ducts for parasites. Sample for histology, microbiology, molecular and ancillary investigations.

Figure 4-58. Location of the pancreas in situ.

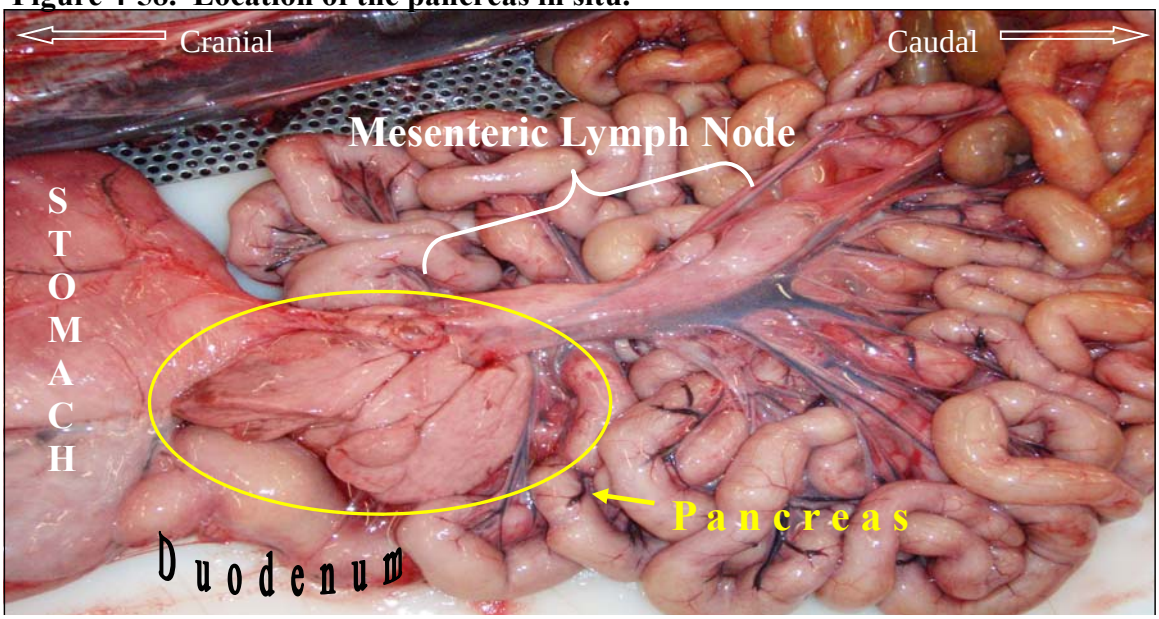

Figure 4-59. Normal pancreas incised and margins reflected to expose cut surfaces.

Figure 4-60. Gross Description: Bile ducts are thickened, white and contain multiple ~1.0cm flat worms and dark brown fluid.

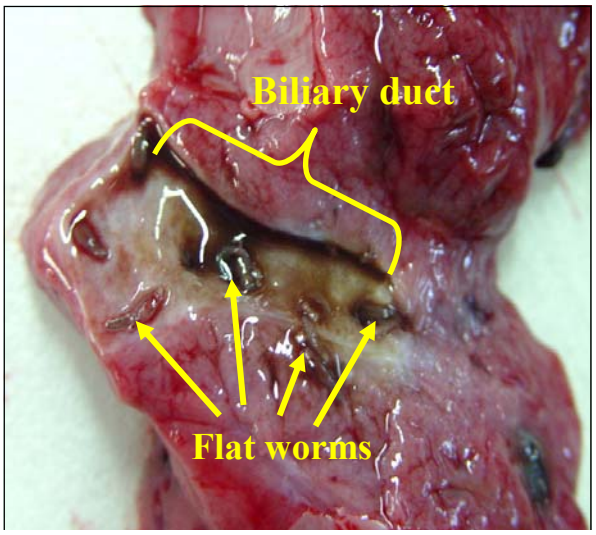

Morphologic Diagnosis: *Intraductal trematode and periductular fibrosis and ductal ectasis.

Mesentery and the mesenteric lymph node:
The mesentery is a broad sheet of connective tissue which attaches the intestines (and other viscera) to the mesenteric root. This connective tissue should be translucent and show some resistance when attempting to bluntly dissect (Figure 4-61). Examine the mesentery for parasitic or fungal attachments or other abnormalities. Note thickness and opacity. The mesenteric lymph node is a finger-like, gray to tan colored, larger lymph node that is centrally attached to the mesentery (Figure 4-58). Remove the lymph node by detaching it from the mesentery. Note the size, shape, and color of the mesenteric lymph node. Examine the external surface and internal structures for changes in color and texture. Unlike previous lymph nodes discussed, the mesenteric lymph node tends to have a more defined cortex and medulla. Be sure to describe each structure separately. Sample for histology, microbiology, molecular and ancillary investigations.

Figure 4-61. Mesentery.

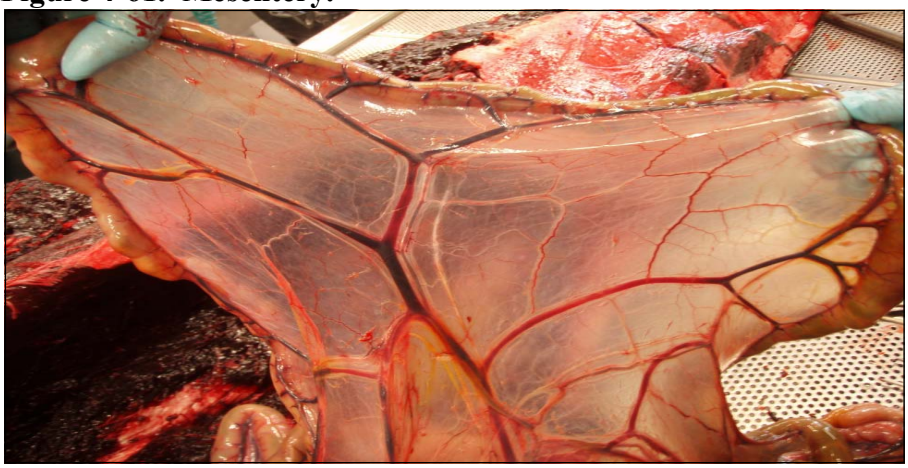

Figure 4-62.

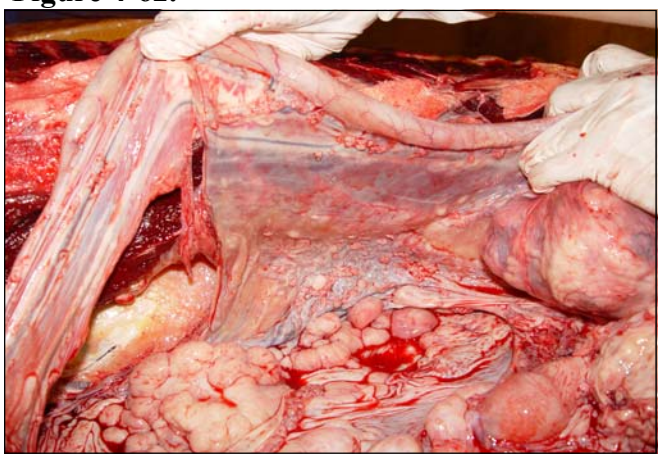

Figure 4-62. Gross Description: Multifocal to coalescing firm, raised, creamy white, sessile masses diffusely attached to the mesentery.

Morphologic Diagnosis: *Multicentric lymphosarcoma.

Figure 4-63. Gross Description: Extremely enlarged mesenteric lymph node with multiple clusters of circular, white, firm nodules with yellow centers infiltrating the cortex effecting >80% of the tissue.

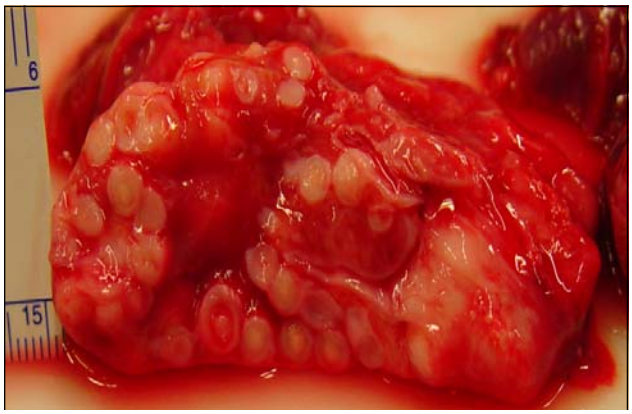

Morphologic Diagnosis: Lymphadentitis or neoplastic process.

Figure 4-64. Gross Description: Well demarcated yellow to tan cortex with multiple, small (0.2 –0.5) circular nodules that slightly infiltrate the medulla; focal areas of hemorrhage at the cortico-medullary junction; medulla is severely edematous and hemorrhagic.

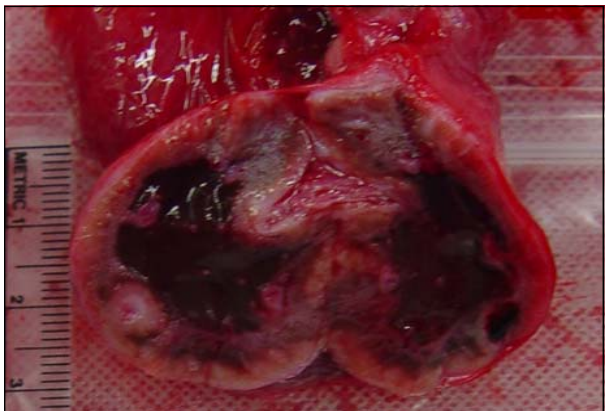

Morphologic Diagnosis: *Follicular hyperplasia

Adrenal Gland:

The right and left adrenal glands are located just anterior to the cranial pole of each kidney and are attached to the dorsal abdominal wall (Figure 4-65). The adrenal glands are small, oblong, light maroon tissues possessing irregular furrows over the surface. Locating and extracting the adrenals prior to removing the kidneys is highly recommended, as they can be difficult to locate without the kidneys as an anatomical reference. To remove the adrenals, grasp and pull the tissue away from the body wall and cut the surrounding connective tissue. Before sectioning, measure (LxWxH) and weigh each adrenal. When cut in half, a normal adrenal will present a distinct darkened center (medulla) with a lighter perimeter (cortex). Note size, shape, color and texture of the external and internal tissue. Also, note relative size of the aperture, or opening in

the medulla, which would indicate usage of the vessel. Normal apertures should be no larger than the tip of a pin. Sample each adrenal for histology and ancillary investigations.

Figure 4-65. Location of the adrenal in situ.

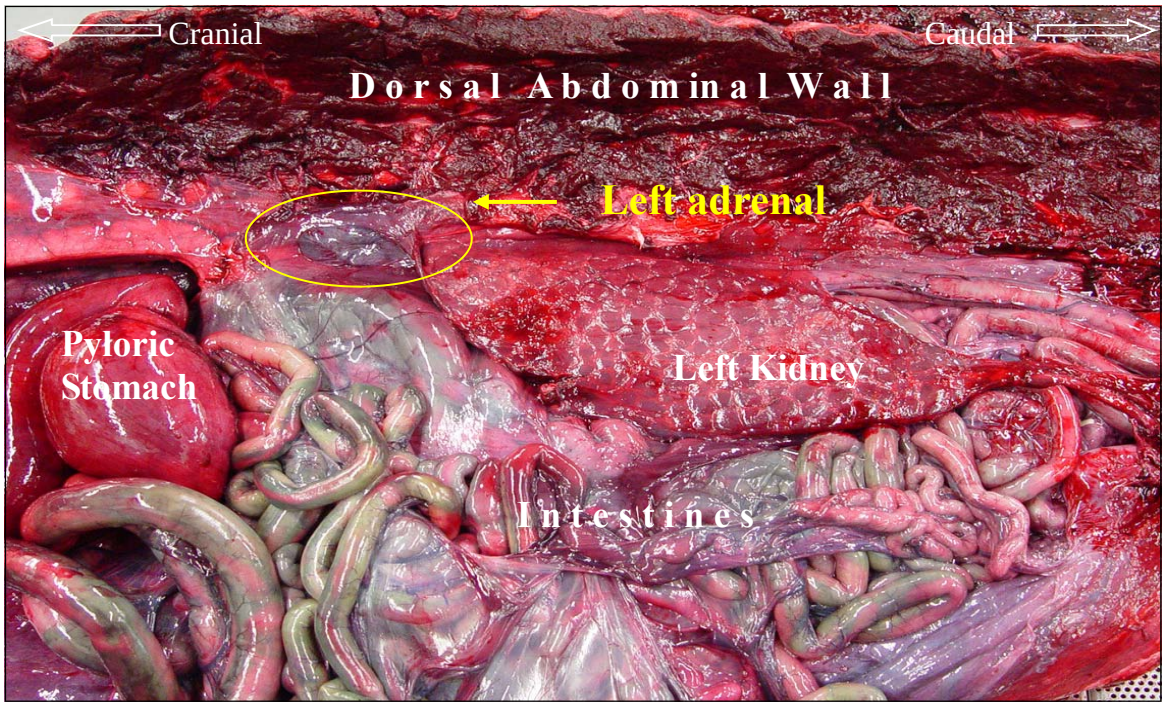

Figure 4-66.

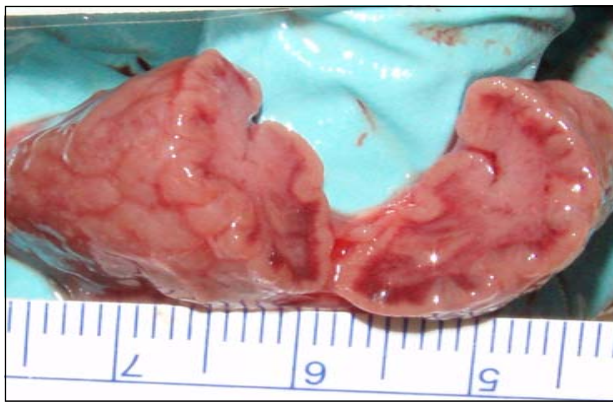

Figure 4-66. Gross Description: Adrenals are diffusely pale pink with multifocal hemorrhage at the cortico-medullary junction.

Morphologic Diagnosis: Cortico-medullary adrenal hemorrhage.

Kidney:
The left and right kidneys are maroon, ovoid, tissues comprised of numerous, clustered reniculi (miniature kidneys) and are attached to the caudal dorsal abdominal wall (Figure 4-65). Examine the capsule (connective tissue surrounding the kidney) for the presence of fluid, hemorrhage, or bubbles and note color, thickness, and opacity. Create a longitudinal incision through the capsule and reflect the margins to asses for adhesions or sub-capsular hemorrhage. Detach the kidney from the abdominal wall and remove the capsule to examine the external surface. Note the size,

shape, external color and texture of each kidney. Examine the internal structure of each kidney by bread- slicing. Note color and presence of stones. Observe the degree of differentiation between the cortex and medulla as well as the medulla:cortex ratio within each reniculus (Figure 4-67). Each reniculus should be well demarcated but clustered together within the kidney itself. Sample for contaminants, histology, microbiology, molecular and ancillary investigations.

Figure 4-67. Cross section of reniculi.

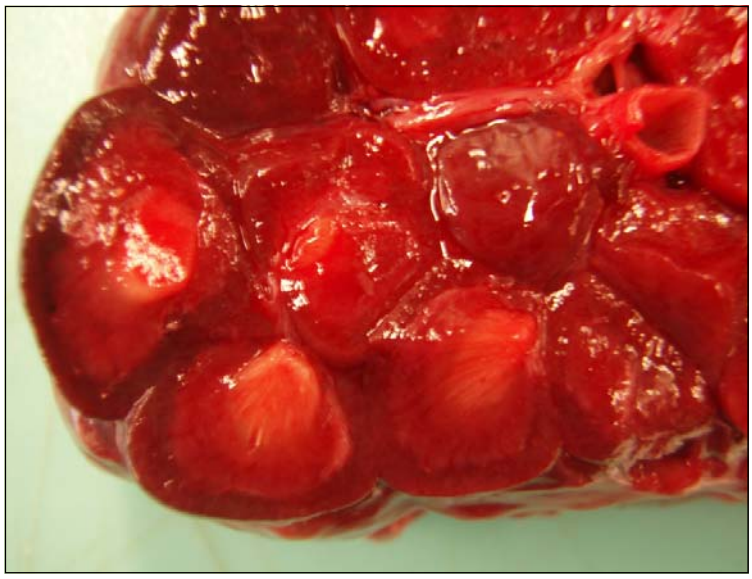

Figure 4-68 . Both the left and right kidneys are adhered together at the cranial pole and share the same ureter; there is only one large adrenal that spans the width of the conjoined kidneys.

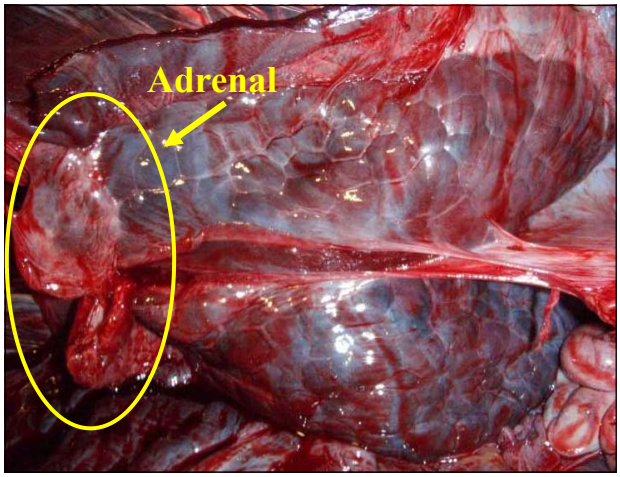

Morphologic Diagnosis: Anterior pole renal adhesions; adrenomegaly.

Figure 4-69. Gross Description: Capsule is thickened, pale pink with multiple nodules; internal structures are pale.

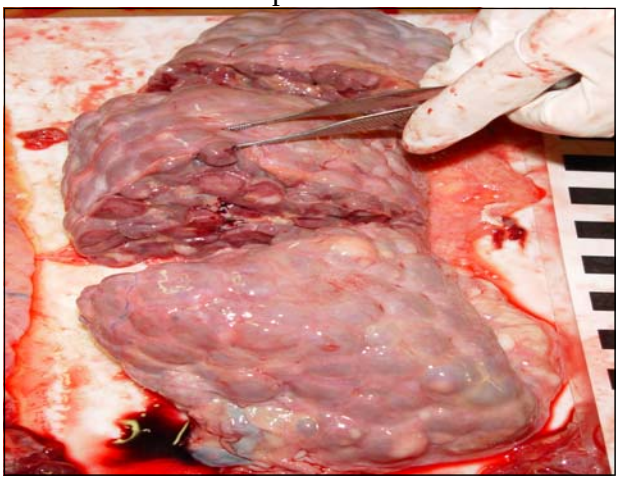

Morphologic Diagnosis: *Disseminated renal lymphosarcoma.

Figure 4-70. Gross Diagnosis: Thick, white, sponge-like material surrounding the entire kidney as well as the internal vessels.

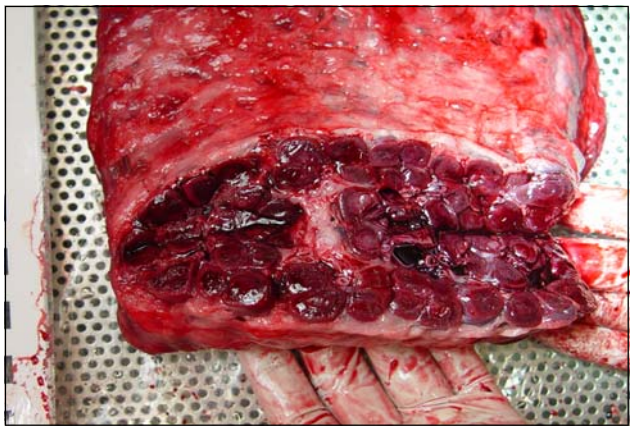

Morphologic Diagnosis: Commonly interlobular renal fat; or steatosis.

Figure 4-71. Gross Description: Bubbles within the renal capsule.

Differential Diagnosis: Post-mortem gas or ante-mortem gas emboli.

Urinary Bladder:

The bladder is a smaller, light pink, organ that is found along the ventral body wall (Figure 4-72). The organ may appear as a thick walled, muscular organ, but if distended with urine, the walls may be thinned and semi-translucent. Before removing the bladder from the body, extract contents using a sterile syringe and medium gauge needle. If none are available, be sure to clamp the bladder using a hemostat before removing the organ in order to retain urine. Note color, consistency, and amount of urine. Remove the bladder and examine internally by cutting along the length of the organ to expose the mucosal surface. Note color and texture of the mucosa. Sample the cranial tip of the bladder for histology.

Figure 4-72. Location of the bladder in situ.

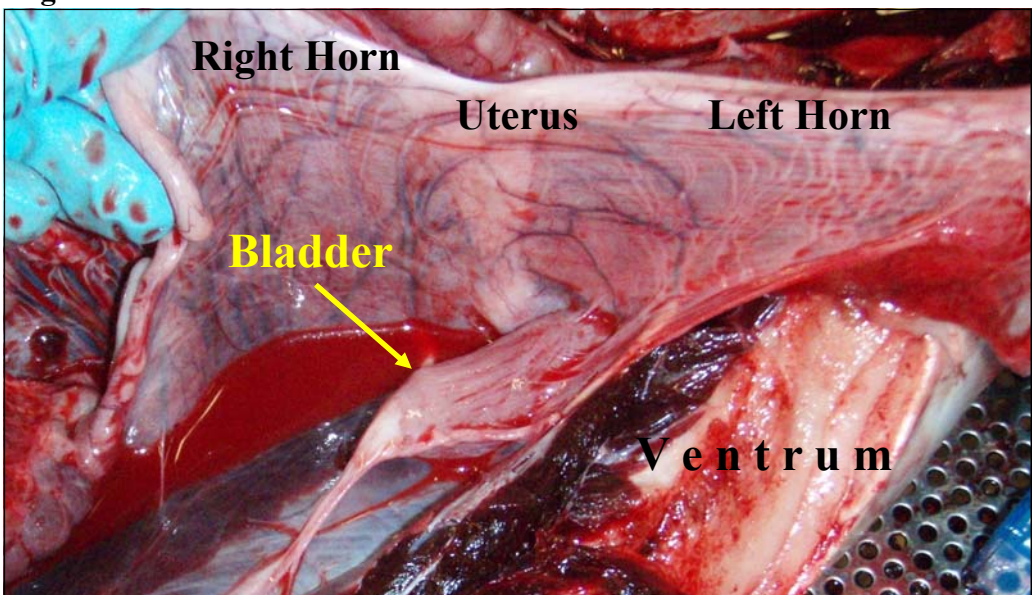

Reproductive tract:
<u>Female</u>- Ovaries and uterus
The uterus and ovaries can most easily be identified by following the reproductive tract from the vagina to the uterus where it bifurcates to a right and left horn, each ending at the attachment of the ovaries (Figure 4-73). The uterus is a tan to pink tissue that will vary in size and thickness depending on the maturity of the animal and its reproductive history. Note size, shape, color, and texture of the external and internal surfaces of the organ. If a fetus is present and is too small for a sufficient individual necropsy, incise the abdomen, collect microbiology and molecular samples, then preserve fetus whole in formalin. If the lung tissue floats in formalin (or water), this signifies that bronchiole expansion of the fetal lungs has occurred.

An off-white spindle-shaped ovary is attached to the end of each uterine horn. Detach the organ from the uterus and examine the external surface. Note size, shape, color and texture. A mature ovary will possess random darkened notches or scars (corpus albicans) which signify previous ovulations (Figure 4-74). The ovary of a pregnant female will posses a corpus luteum, or a large yellow mass attached to the ovary (Figure 4-75). Before internal examination, measure (LxWxH) and weigh each ovary. Also count and note the number of scars and presence/absence of a corpus luteum. Examine the tissue internally and note color and texture. Sample both the uterus and ovaries for life history, histology, microbiology, molecular and ancillary investigations.

Figure 4-73. Reproductive tract of an adult, female *D. delphis;* note the cluster of large *monorygma* attached.

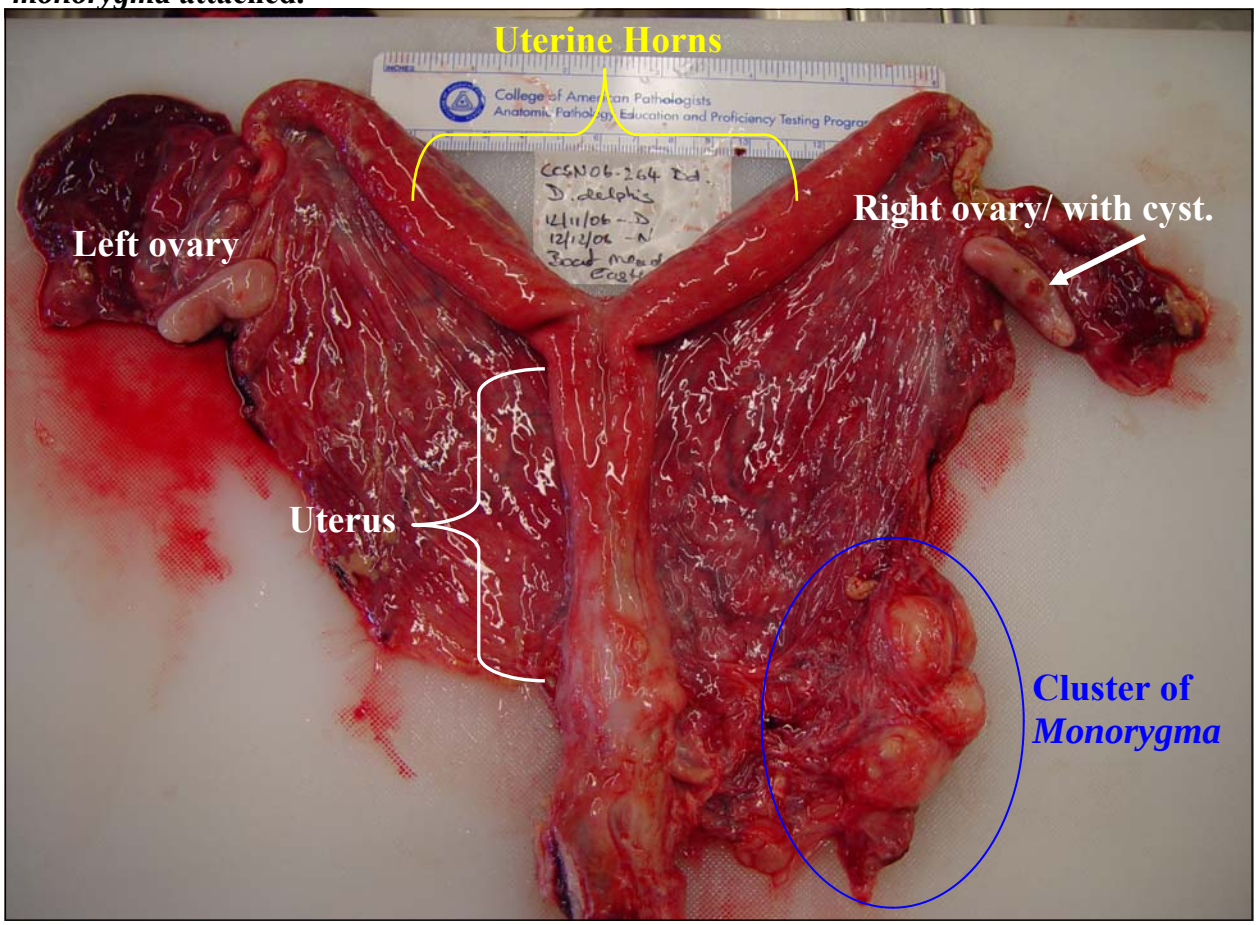

Figure 4-74. Gross Description: Multifocal dark, slightly depressed notches on the surface tissue.

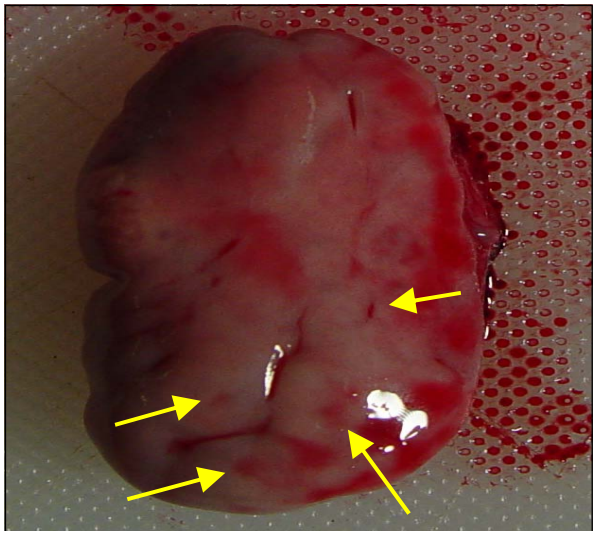

Morphologic Diagnosis: Stigma on the surface of the ovary indicative of previous ovulation.

Figure 4-75. Ovaries from a pregnant *L. acutus*: Left is an active ovary with multiple corpus albicans; right is the ovary from which the fertilized follicle was released—notice enlarged, but hemorrhaged corpus luteum.

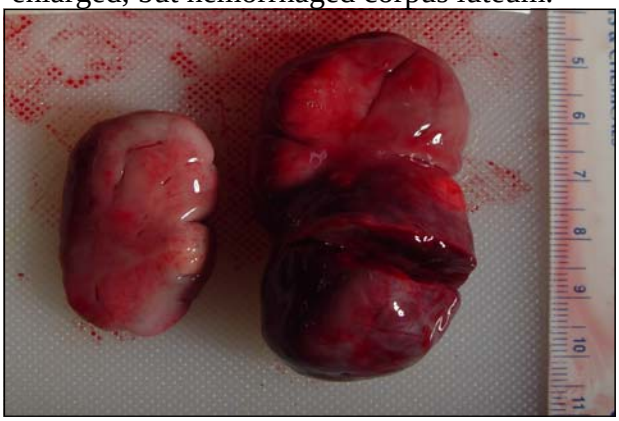

Morphologic Diagnosis: Corpus luteum hemorrhage.

Figure 4-76. Gross Description: There is a 0.4cm spherical, clear fluid-filled nodule attached to the surface of the ovary.

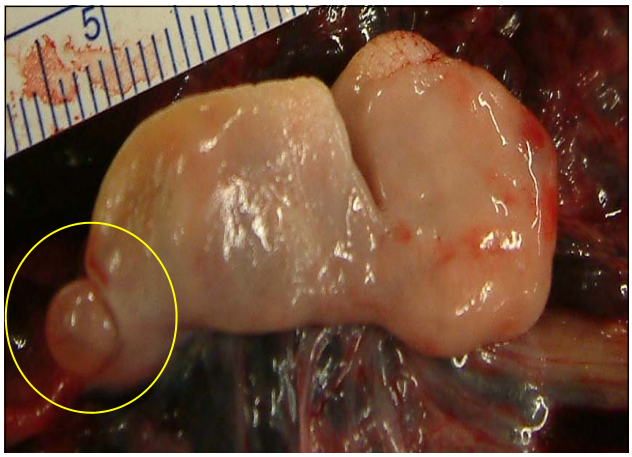

Morphologic Diagnosis: Ovarian Cyst.

Figure 4-77. Gross Description: Multifocal areas where the ovarian capsule is raised and roughened.

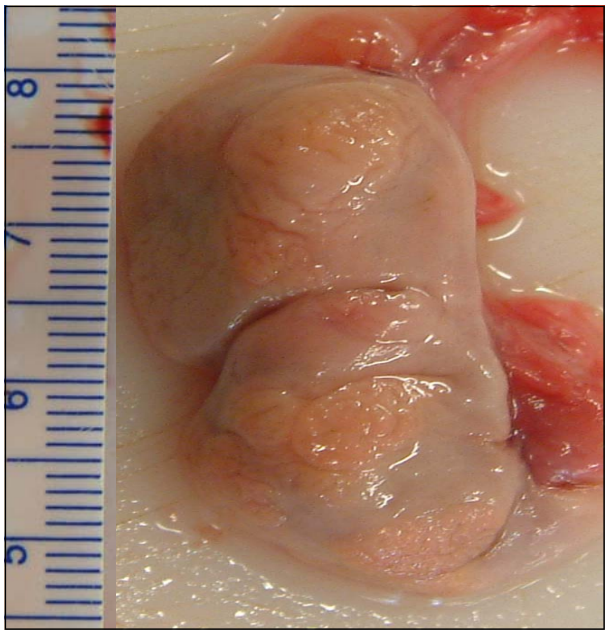

Morphologic Diagnosis: Capsular fibrosis.

<u>Male</u>- Testis and Penis

The elongated, spindle shaped, off-white paired testes are located within the caudal abdominal cavity along the ventral wall, posterior to the kidneys, each one just off the ventral midline (Figure 4-78). Remove the testes (with the epididymus attached) from the body. Obtain measurements (LxWxH) and weight of each one. Examine the size, shape, color, and texture externally and internally. Section epididymus for the presence/absence or sperm. Obtain samples of each testis for life history, histology, microbiology, molecular and ancillary investigations. Examine the penis externally and look for discharge or the presence of papillomas or other lesions.

Figure 4-78. Left testis in situ with penis dissected.

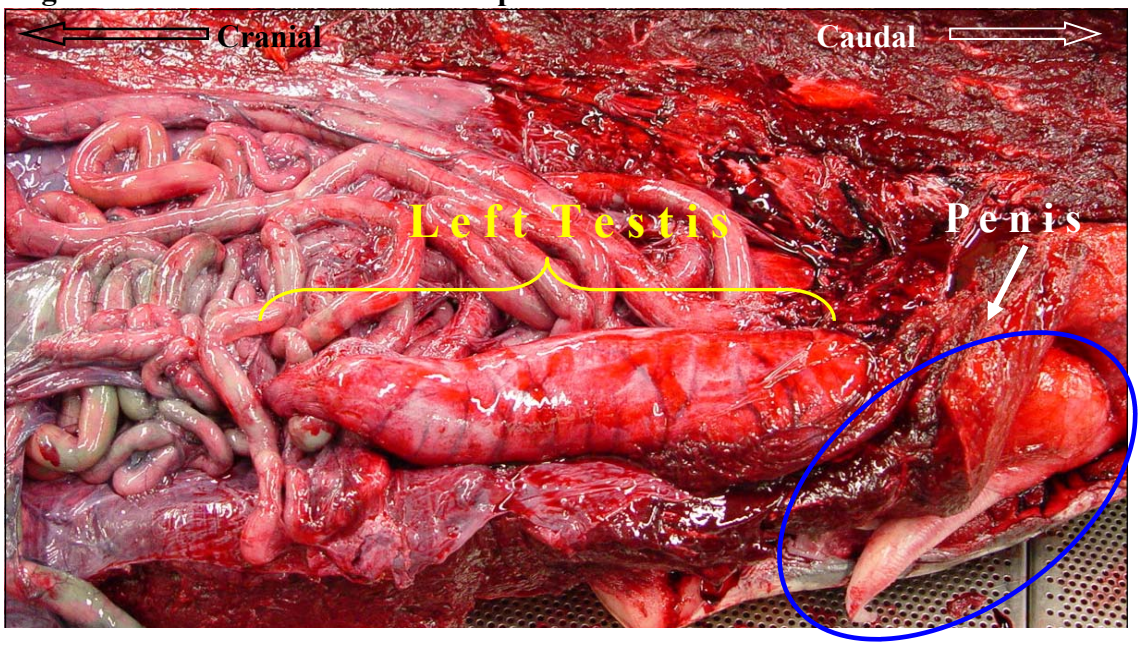

Figure 4-79. Normal, immature testes with epididymus.

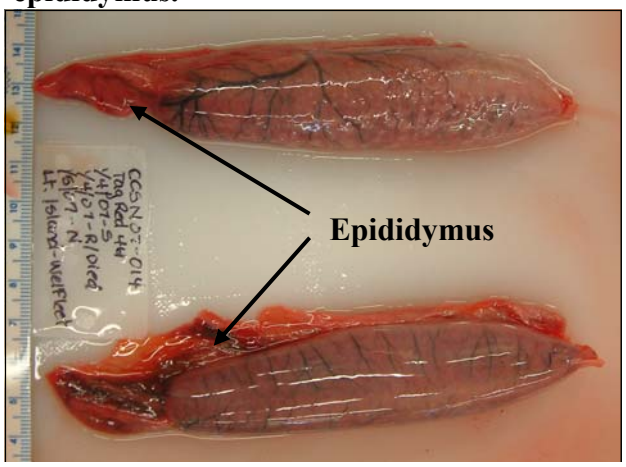

Figure 4-80. Cross section of vas deferens.

Figure 4-81. Gross Description: Multiple (>15), large (2.0cm), spherical, thin walled, parasitic cysts clustered around the urinary and reproductive organs.

Morphologic Diagnosis: Pericystic cestodes; **Etiology**: *Monorygma* sp.

Figure 4-82. Gross Description: Attached to the lower, ventral abdominal wall, proximal to the testis, there is an 8.0cm, thin walled, spherical cyst containing green/brown translucent fluid and yellow plaques and a single 1.3cm diameter yellow, gelatinous ball.

Morphologic Diagnosis: Pericystic cestode; **Etiology**: *Monorygma* sp.

Stomach:

The stomach of most odontocetes is comprised of three compartments: the fore stomach, main stomach, and pyloric stomach (Figure 4-83). There is a thin, net-like connective tissue that is attached to the visceral side of the stomach. This is the **omentum**. To avoid contaminating the remaining tissues in the body cavity or losing contents, it is necessary to tie off both ends of the stomach prior to extracting. With some twine, tie a tight, secure knot at the location of the attachment of the esophagus to the fore stomach. A second piece of twine can be tied just below the base of the pyloric stomach where the small intestines begin. Remove the stomach from the carcass by cutting beyond both knots. Examine the serosal (external) surface of the stomach for discoloration and lesions. If an internal pathology is present, the peri-gastric lymph nodes attached to the stomach should be noticeably enlarged. Sample for histology, microbiology, molecular and ancillary investigations and make note on the sample inventory list if this is the case. Otherwise, remove all excess attached tissue from the exterior of the stomach and weigh the stomach full.

Using a scalpel, make an incision through the wall along the greater curvature of each stomach large enough to allow examination of the contents and entire mucosal surface. Describing the contents of each compartment separately, note the composition of stomach contents (fluid; whole or partially digested fish; fish bones; parasites; foreign objects). Be sure to describe amounts, color, and texture. Prior to further manipulation, collect a sample of contents for biotoxins. The remaining contents can be emptied and rinsed into a sieve to ensure solid material is not lost and is thoroughly examined. Save all foreign objects for human interaction documentation. Collect and store the remaining solid materials as outlined in the Sample Management section (Section 2) of this manual.

Figure 4-83. Three-compartment stomach removed from the carcass.

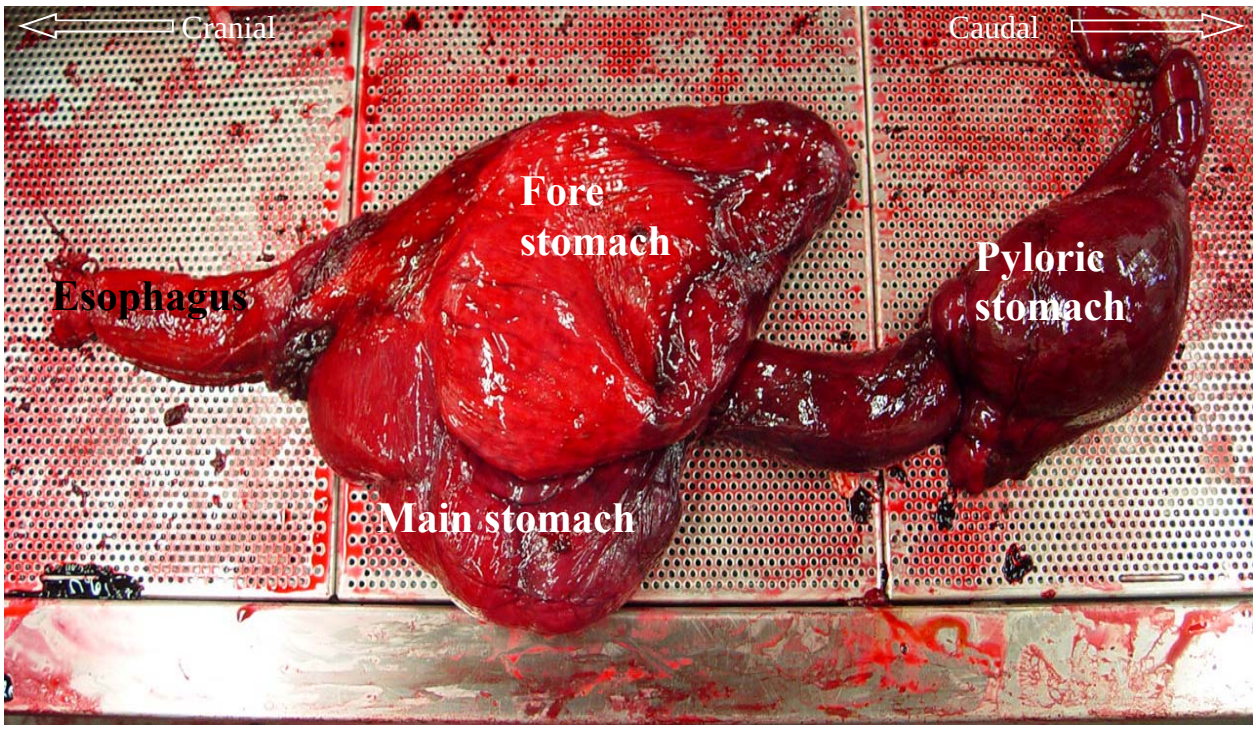

Once empty, examine the mucosa of the stomach. Note the color and texture of the mucosa of each compartment separately. The mucosa of the fore stomach is composed of squamous tissue and is usually white (Figure 4-84). The wall of the main stomach is stratified and usually thicker than that of the fore stomach. The mucosa is usually dark red (Figure 4-85). The pyloric stomach tends to be thin walled, glandular, and the mucosa is pink or stained with bile. Look for ulcers, areas of discoloration and other abnormalities. Weigh the stomach empty. Sample each compartment for histology.

Figure 4-84. Mucosa of the fore stomach

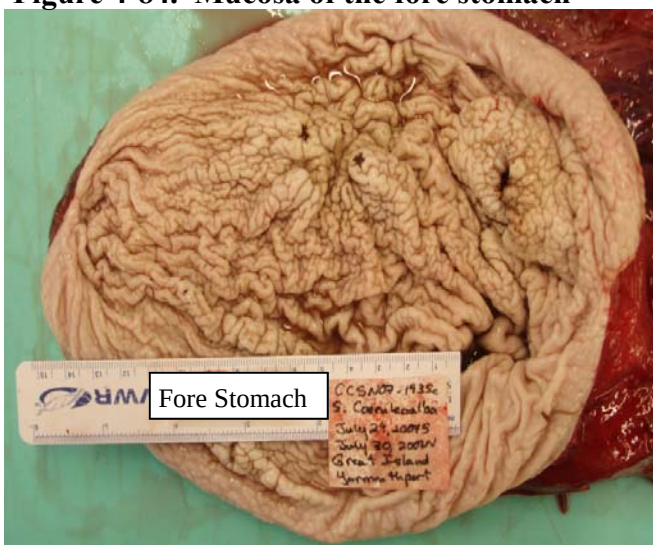

Figure 4-85. Mucosa of the main stomach

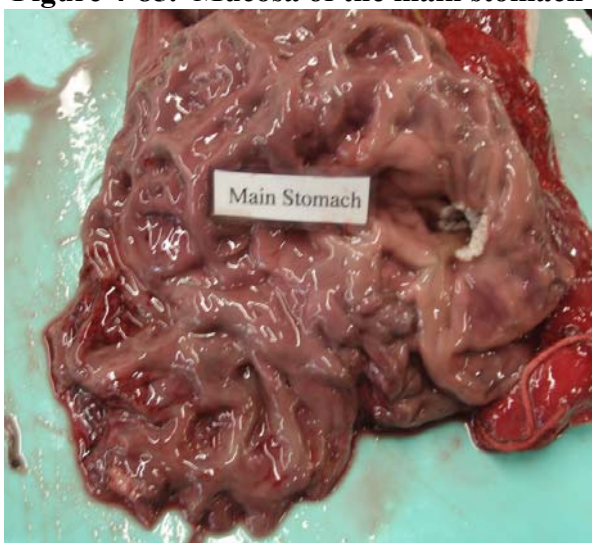

Figure 4-86. Gross Description: Multifocal 0.1-0.3cm circular, white, firm attachments on the major vessels of the omentum.

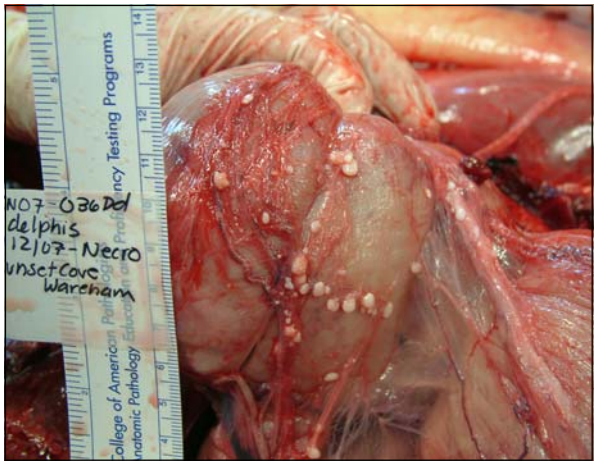

Morphologic Diagnosis: Unclear, but consider encysted parasites or granulomas

Figure 4-87. Gross Description: Firm, cream colored nodules varying in size adhered to the omentum and covering the stomach.

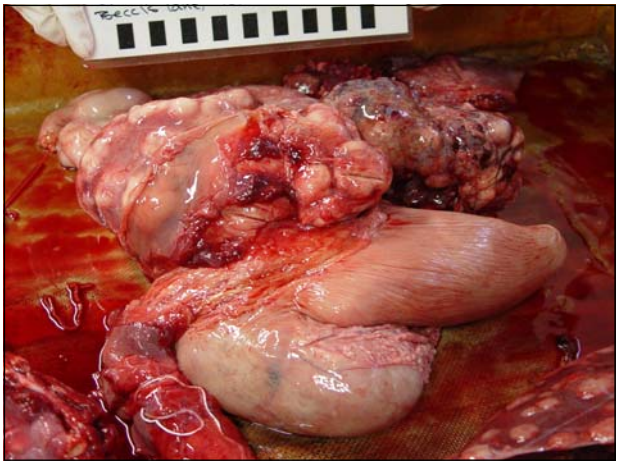

Morphologic Diagnosis: *Gastric and omental lymphosarcoma.

Figure 4-88. Gross Description: Approximately 1.0cm, irregular edged, granulated, depressed, red, ulceration of the fore stomach mucosa.

Morphologic Diagnosis: Chronic stomach ulcer.

Figure 4-89. Gross Description: Large (3.5cm), circular, gray-black ulcer of the main stomach mucosa with a marked depressed center penetrating the mucosa and submucosa of the main stomach.

Morphologic Diagnosis: Stomach ulcer with associated necrosis and hemorrhage.

Esophagus:
Trace the esophagus from the exposed caudal end to the mouth, opening the esophagus in the same manner as done with the trachea. Observe the serosal and mucosal surfaces of the esophagus. Note, color, texture, and contents. Sample for histology.

Small intestine:
Examination of the intestines is preferably left until the end of the necropsy so as to not contaminate the other organs. Examine the serosal surface of the small intestine first. Look for areas of hemorrhage or discoloration as well as parasites. The inside of the small intestine can be examined by spot checking: at 5 – 10 random, separate areas, using scissors to cut about 10.0 cm down the length of the lumen. Note color, consistency and amount of contents as well as thickness of the lumen and the texture and color of the mucosa. Sample several sections for histology.

Large intestine:
To locate the beginning of the large intestine, look for the ileo-ceco-colic junction, which usually is a ridged junction between the smaller diameter small intestine and the larger diameter large intestine. The large intestine can be examined in the same manner as the small intestine. Note any discoloration or the presence of parasites. Describe the color, consistency and amounts of contents. Note the thickness of the lumen as well as texture and color of the mucosa. Sample for histology.

Colon:
Examine the serosal surface of the colon for areas of discoloration. Cut through the lumen of the colon from the anus to the large intestine. Describe the color, consistency and amount of contents. Note the thickness of the lumen as well as texture and color of the mucosa. Sample for histology. Collect feces for biotoxins analysis.

Figure 4-90. Gross Description: Mucosa of top intestinal section is thick and yellow to dark orange (A); mucosa of lower section is light pink with scant amount of yellow mucoid material (B).

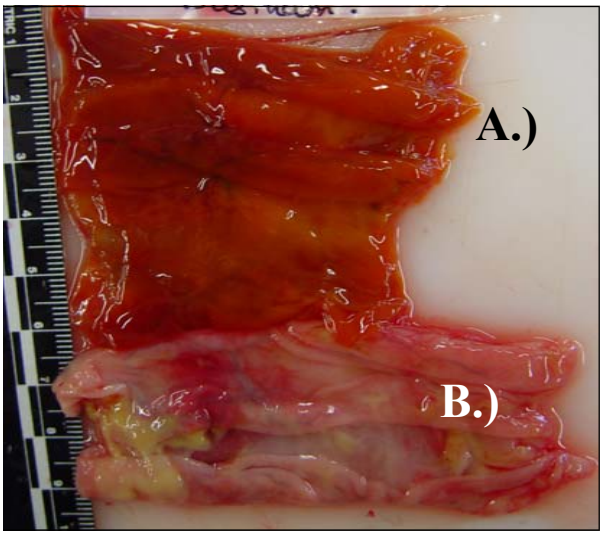

Morphologic Diagnosis: (A) Enteritis; (B) Normal mucosa.

Figure 4-91. Gross Description: Small (0.3cm), white, flat, thorny head worm attached to the mucosal surface of the intestine.

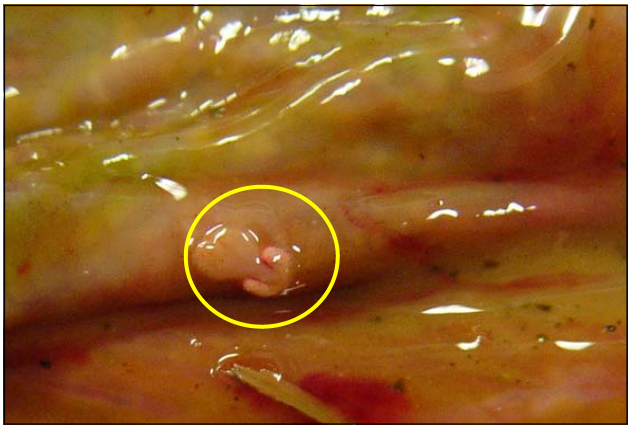

Etiology: *Acanthocephalan sp.*

Removal of the Brain:
The brain is the most fragile and easily disrupted tissue in the entire body, thus extreme care must be taken when removing the brain from the skull. Before removing the head, cerebrospinal fluid (CSF) can be collected for cytology and culture. To do so, remove the overlying soft tissue at the back of the head and neck to gain access to the atlanto-occipital joint. Insert a sterile needle and syringe and collect the clear, viscous CSF.

First the head must be detached from the body to safely remove the brain. Do so by cutting behind the blowhole down to the joint between the skull and cervical vertebrae, and then completing the cut ventrally. Once separated, remove all excess skin, blubber, muscle and connective tissue from around the dorsal and caudal skull. Then, using a Stryker saw or a hacksaw, make cuts from lef to right through the middle of each occipital condyle, up each side of the lateral skull, and then across the dorsum, just posterior to the marked transverse ridge at the apex of the skull (Figure 4-92). Be sure to fully penetrate the bone, but avoid contact with the brain. This can be very difficult, so proceed with caution. It will take some practice to successfully remove the cranium without penetrating the brain. Carefully place a chisel between the cut bone and turn the tool to crack the remaining bone until the back of the skull comes away in one piece (Figure 4-92). Be careful to pull it off evenly, without using one edge as a lever, otherwise the bony shelf (the tentorium cerebellae) that is positioned between parts of the brain will penetrate the tissue and damage the brain. Using fingers, gently tease the meninges (thin membranes enveloping the brain) away from the skull, and work under the brain to sever each cranial nerve. Inversion of the head often allows the brain to gently descend in to the palm of your hand.

Figure 4-92. Dorsal aspect of the skull has been removed to expose the brain. Note: Vascular congestion of meninges.

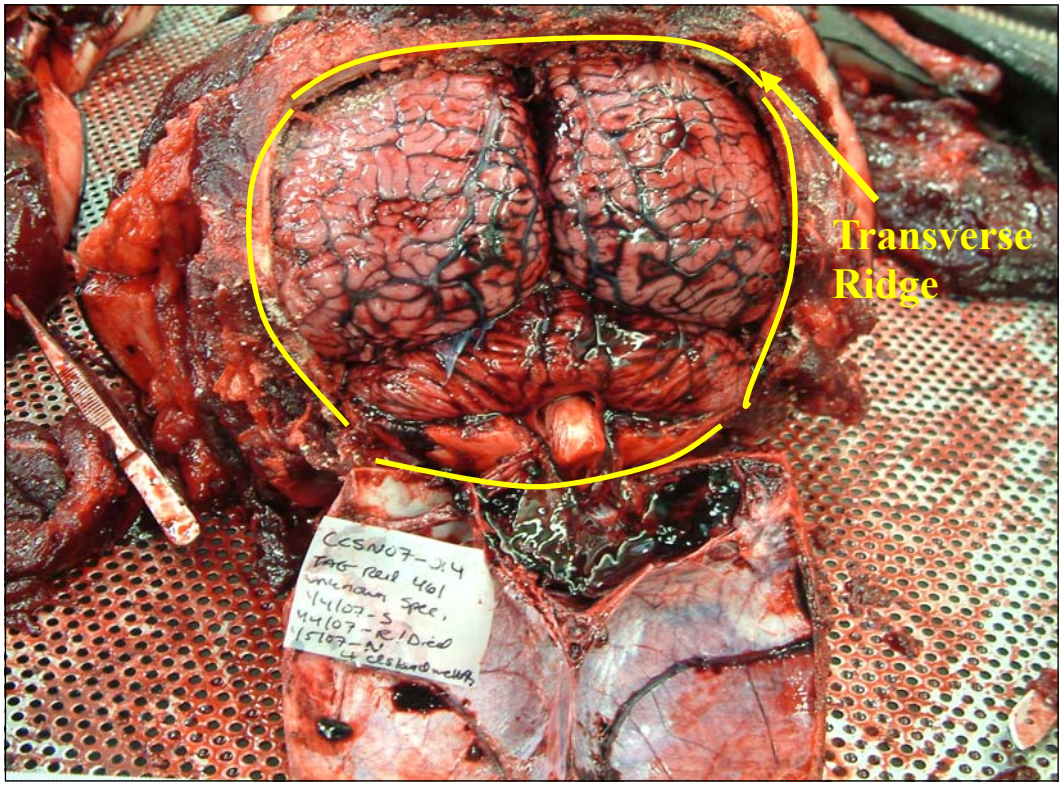

Examination of the Brain:
Again, the brain is the most delicate tissue in the body and will fall apart if handled excessively. Observe the external surface of the brain and note symmetry of each distinct structure (right and left cerebral hemispheres, cerebellum, and brain stem) (Figure 4-93) while noting the color, texture, and presence of worms or lesions. Vascular congestion can be a result of positioning or post mortem lividity. Cut through the brain in one long motion, cranial to caudal, using a large, thin knife so that the two hemispheres evenly separate. Again, note symmetry, color, texture and the presence of worms or lesions. Each section of the brain has a distinct pattern (Figure 4-94). The cerebrum is comprised of two distinct lobes and is the most cranial section of the brain. The cerebellum is the most caudal portion and sits dorsal to the brain stem. The brain stem originates from the ventral midline of the brain and extends into the spinal chord. Sample the cerebrum, cerebellum, and spinal cord for microbiology, molecular and ancillary investigations. Fix the remaining brain tissue for histology. It is important to include a sample of normal and abnormal meninges in the histology sample set.

Figure 4-93. Brain is removed from carcass to view structures.

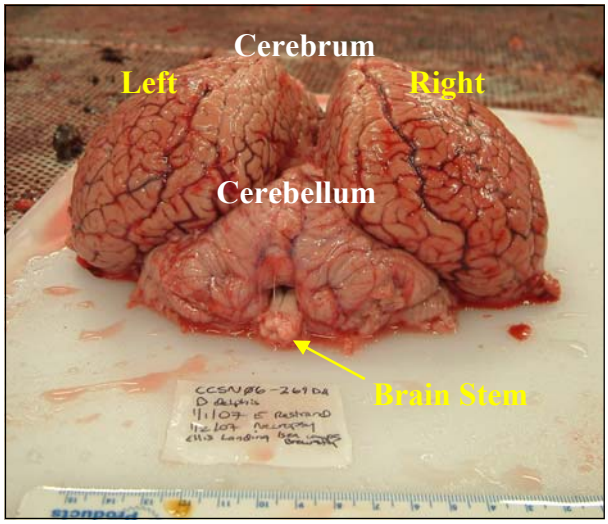

Figure 4-94. Structures of the brain upon cut section.

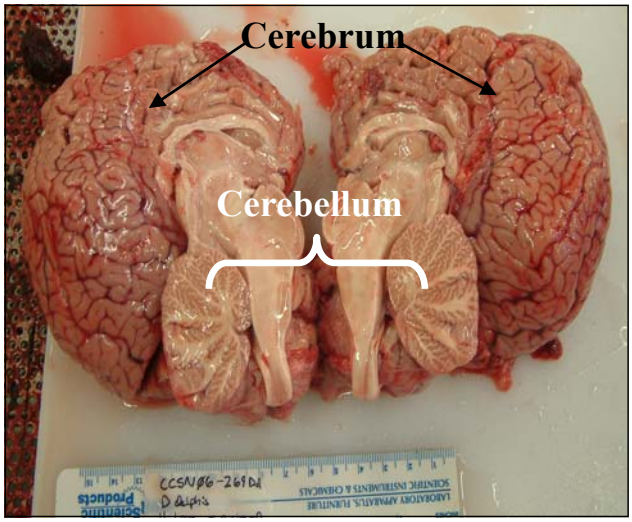

Figure 4-95.

Figure 4-95. Gross Description: Brown, necrotic 2.0cm depression of the left frontal lobe with tan fibrino-purulent exudates.

Morphologic Diagnosis: *Parasitic abscessation.

Figure 4-96. Gross Description: Brown/ black lesion with clear exudates penetrating the brain parenchyma of the right occipital lobe proximal to the hemispheric division and apex of the cerebellum.

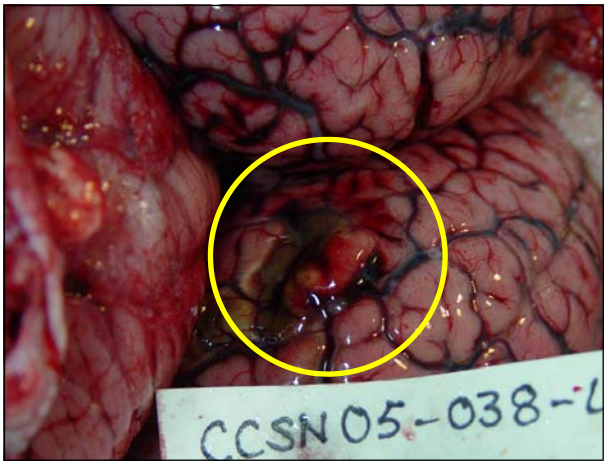

Morphologic Diagnosis: *Necrotizing encephalitis with parasitic tract formation.

Figure 4-97. Gross Description: Meninges and folia of the cerebellum are dark red.

Morphologic Diagnosis: *Mild, chronic meningoencephalitis and peracute hemorrhage.

Pituitary Gland:
Once the brain has been removed, immediately under the crossover of the optic nerve, the usually small pituitary gland can be extracted after incision through the overlying dura. The organ is within a bony recess and has to be lifted out using a scalpel blade and small forceps. Sample for histology and other priority testing.

Ear Extraction:
After removal of the brain, the middle and inner ear complex can be removed and preserved as appropriate. Detailed protocols for this procedure can be found in Ketten *et al* (2007).

This page intentionally left blank.

- SECTION FIVE -
Large Whale Examination and Necropsy

On-Shore Necropsy

Planning and Logistics:

A large whale necropsy event requires substantial coordination and rapid planning, as each event is unique and presents different constraints. However, they are all driven by the same basic issues: location/relocation, towing, landing, case history, examination, sampling, sample analysis, reporting and most pressing of all, waste disposal. The extent to which these are all possible depend on the availability of funds, which in turn is dictated by the pressure to obtain quality information. Thus, one's ability to work up a right whale carcass usually exceeds that of a less endangered species.

Logistical planning begins with the first report of the carcass. It is important to keep a detailed phone log of every call received or made throughout the large whale stranding event. Information on the log should include date and time of conversation as well as the person's name, affiliation, and contact number. For floating carcasses still at sea, a printed map of the initial location and weather predictions for the following few days should be on hand until the carcass is finally landed.

For all large whale necropsies, there is a significant amount of advanced planning that must be completed. It is essential to have these elements secured before beginning the necropsy:

Necropsy Site Location:

In most cases, large whale carcasses wash ashore and necropsies can be conducted on-site. Often, on both state, federal, and privately owned properties, the land owners/authorities are eager to remove the carcass and are thus very cooperative in facilitating the necropsy and disposal.

For carcasses found floating at sea and towed to shore or stranded at a site that prohibits a necropsy, it may be necessary to transport the carcass over land to a suitable necropsy site. Towing floating carcasses into large marinas with travel-lifts is the best way to facilitate transport. Travel-lifts permit fairly easy transfer of the carcass from the water into a truck. Land transport using a flatbed truck is reasonable, but it is preferable and cleaner to use large dump-trailer (when carcass size can be accommodated). This helps contain the carcass and any run-off during transport and, once at the new site, it can easily be slid out of the container.

Disposal:

Once a necropsy site is determined, the next step is to establish a disposal plan. Disposal ultimately drives the entire necropsy event, as without a disposal plan the event should not begin. Do not commit to a necropsy (even hooking up to a tow) until you are satisfied that the disposal plan is viable and appropriate, or that the necessary people are informed so that a plan will emerge in

time. Only your experience with the locality and participants determine this. Obviously, if the animal is already beached then the landowner is much more willing to work with you to make such a plan a reality.

Disposal options include:

Surface Decay: Realistically, this is rarely a viable option with land owners and local agencies. However, if the necropsy was conducted on a remote beach and burial is not practical, the fastest decay is achieved by leaving the carcass open for maggots and other scavengers. Be sure to obtain good images of the state of the carcass as left at the site. Thus, if a storm washes it offshore and it is found floating or stranded on a new beach, it will be identifiable. It is vital to be able to recognize carcasses that have already been worked up.

Beach burial: Where the ecology and human use of the beach allows, beach burial is the most affordable and easiest action. This should be done away from water supply and other environmentally sensitive areas. This option allows the leachate to flush out to sea, and avoids extensive transport costs. A suitable backhoe, excavator, or other heavy equipment is required. Ideally, a hole is dug beside the carcass and as flesh and blubber are stripped off they are examined, sampled and pushed in to the hole. The hole is then backfilled. Attempt to dig such holes away from likely tracks of future vehicles. If a museum is likely to want the skeleton, it is best that the bones are collected immediately. Bones left on a beach are likely to be stolen overnight. If the interested person is not able to collect the bones right away, rather within 24 - 48 hours, using a machine to cover them with large pieces of soft tissue waste has proven an adequate deterrent. If the bones will be collected much later, take careful note of the exact location, using a map, GPS, triangulated landmark sightlines and a buried piece of metal to enable later use of a metal detector.

Offshore dumping: If the material can be loaded on a barge and dumped offshore, this is a good plan, as long as the risk of the material washing ashore again is minimal. Legally you have to be at least 12 miles offshore, but in all likelihood a greater distance will be required to ensure tissues will not float ashore again. The local currents and tides will dictate exactly how far and where to go. In addition, NOAA fisheries, the Environmental Protection Agency, and the US Coast Guard (USGS) will likely need to approve of such a plan.

Land filling: Often, landfills are the optimal (or only) option. Some landfills may not accept whale carcasses or necropsy waste. To be environmentally sound, only lined landfills should be used. The impact of a whole carcass or just necropsy waste deposited at landfills must also be well planned and the associated costs considered. Note: for floating carcasses towed ashore, landfills can also be the best necropsy site as well.

Composting: there is a growing movement, with the demise of the livestock rendering industry, to compost livestock waste. Protocols for marine mammals are still under development, but the general principles can be obtained from the following website: http://cwmi.css.cornell.edu/ and specifically http://compost.css.cornell.edu/naturalrenderingFS.pdf

Team Member Roles:

Once necropsy personnel are assembled, hold a group meeting to assign roles, discuss safety, personal protective clothing (boots, foul weather gear with duct taped cuffs, safety glasses and

double gloves) and outline the goals for the event, along with pertinent known case history.

Large whale events require a number of key personnel:

Off-Site coordinator – Serves to streamline communications among the responsible agencies, solve logistical issues, and coordinate the general process.

On-Site Coordinator – Arranges logistics for landing site, beach equipment, disposal and necropsy crew. Assists with sample dissemination and tracking.

Necropsy Team Leader – Manages the necropsy crew, gathers all available data with the help of the scribe, supervises direct sample submission and analysis, collates and pursues data, drafts and completes a full gross necropsy report. Ultimately responsible, along with the On-Site Coordinator, for human safety and environmental protection of the site. Although ideally there should be a separate individual overseeing all safety is sues.

Photographer – Records the subject of the filename of each image. Photograph all ex ternal and internal abnormalities. Ideally, sections of all lesions should be photographed prior to preservation. Such images should bear an identifying number or letter in the im age that relates to the sample ID, and the necropsy record. Maintains a log of all images. Ideally, images are cross referenced by the same letter or number shown in the image and on the sample tag.

Cutting crews – Crew of 2-3 – a cutter, a hooker and a spotter to watch for safety issues with other crew members and run samples to the sampling team. Each crew disassembles different aspects of the animal – such as head, thorax and abdomen, communicating continuously with the team leader, the photographer and the scribe.

Sampling team– Crew of 2-3- Receives samples from cutting crews. Dictate notes to scribe regarding all samples. Follow proper sampling and labeling protocols for all samples (genetics, life history, contaminants, biotoxins, *etc*.).

Scribe – Records all gross necropsy observations, prompts necropsy cutting crews for information on each organ system as exposed. Records descriptions of samples from sampling team.

Floating Carcass:

The investigation of large whale mortalities is often important enough that carcasses found floating at sea warrant an examination. Conduct as complete an external examination as possible before handling or moving the carcass. This will help to differentiate existing marks and possible human interaction from the marks resulting from the towing, landing, and transporting of the carcass. Furthermore, these will be the “freshest” photos of the carcass and in most cases are critical in the final diagnosis. The image below (Figure 5-1) was taken at sea and was critical to the final diagnosis.

Relocation:

Cases at sea are usually initially reported by aerial surveys, ships or the USCG. Often, it takes hours or days to organize a response. In these cases, drift models can be consulted to predict the likely position at the time of attempted relocation. However, such models are not always 100% accurate. Thus, search patterns should start close to the last known position and head downwind from there, crossing the likely line of drift perpendicularly if possible, to maximize the chance of encountering the oil slick emanating from the carcass. Such slicks are often miles in length and may be populated with sharks. Birds often mark the carcass. Tides are usually of little net impact if more than 12 hours have elapsed, but if there is a persistent current, this too should be factored into the analysis. Once the carcass is re-sighted, be sure to obtain images of the external condition of the carcass prior to initiating a response. These images will serve to document any changes since the animal was first sighted. In addition, they can be transmitted back to the Off-site Coordinator and other authorities to aid in determining the best course of action. The extent of decomposition and scavenger damage will affect possible examination options (towing to shore vs. at sea exam). Very decomposed, deflated carcasses are likely to fall apart when towed and will yield only limited information. Intact carcasses, often still bloated, are more likely to withstand the strain of the tow and make it to shore, yielding greater results.

Figure 5-1. Line impressions around the peduncle of a large whale carcass at sea.



Towing:

It is always preferable to bring a carcass ashore, if feasible, to conduct a complete and thorough necropsy. If the carcass is in good enough condition to be towed (intact, not completely deflated), one must asses the logistical considerations of towing—distance from shore, appropriate landing site, disposal plan, *etc*. Once all elements of the plan are established, proceed with towing.

As a rule of thumb, the vessel should be significantly longer in length than the whale to be towed. A towing bridle makes hooking up to a carcass much easier (Figure 5-2). Using a boathook, push the float ball (a) under the narrowest part of the tail (b) until it floats up the other side of the whale. Pass the float and line it is attached to through the eye splice on the opposite end of the heavy line (c). Cinch it tight. Use the short rope tail (d) on that splice to tie the splice to the heavy line that passes through it to ensure that the bridle does not slip off the whale when no tension is applied. Use the smaller line with the float (a) attached to catch the line when hooking up a tow line to the larger rope. Alternatively, a sinking line with a weight attached can be thrown over the upstream side of the peduncle, the whale will then drift in to this line making it stream out below and behind the moving carcass, allowing one to catch the line with a boathook and draw it up to encircle the peduncle.

Figure 5-2.

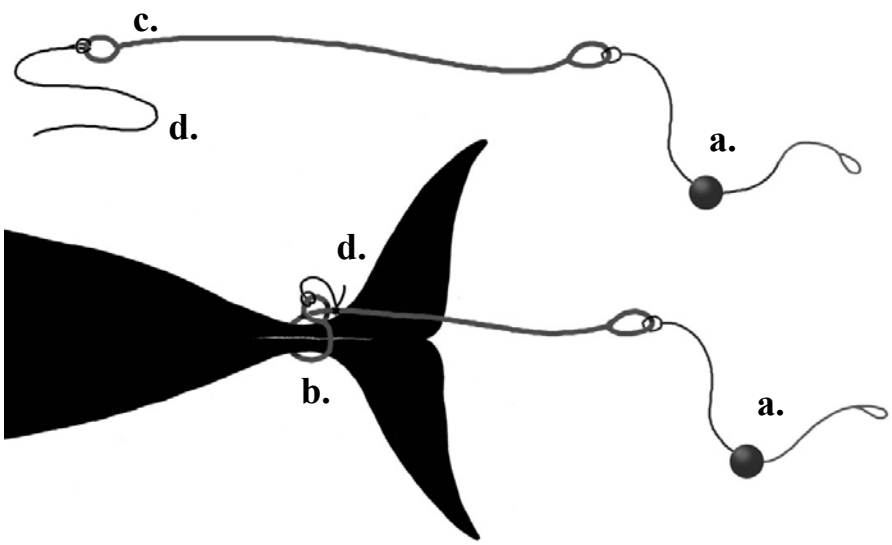

Drawing by Scott Landry, Provincetown Center for Coastal Studies

Landing:

The amount of power required to haul the carcass up and onto land/beach depends on the nature of the site, and the size of the whale (Figure 5-3). In order of increasing friction we have found that the easiest to hardest surfaces are as follows: wet slab rock such as basalt, cobble, slick mud, gravel, sand. If the necropsy site is on a dock or paved area or if the site is away from the landing area requiring transport, a crane or boat hoist (travel-lift) is a good option for moving the carcass onto the dock or into the transport truck . For landing carcasses in beaches, track laying machines are better than wheeled. Adequate heavy rope is critical for dragging the carcass above the high tide line. Ropes, chains or cables of 90 ton breaking strain are not unreasonable. Be extremely careful to keep bystanders out of any possible zones of influence of recoiling broken lines and cables.

Figure 5-3. Equipment required to move a decapitated right whale up a sandy beach.

Necropsy:

For the full necropsy examination of a large whale carcass, whether beached or landed , the primary aspects of the process are the same. The process for performing a necropsy on a large whale is covered in great detail, with excellent data sheets, in the Right Whale Necropsy Protocol (McLellan et all, 2004), which can be easily adapted for other species. Outlined below is a brief overview of the key aspects.

Case History:
Be sure to obtain a full history of the carcass. Inquire of all relevant on-site and off-site personnel for all data concerning first sighting, location, timing, known life history, and post-mortem handling to maximize understanding of the carcass as it is now. Be sure to ask about any rope that has been tied to or removed from the carcass post mortem (in the process of towing, landing or manipulating the carcass).

Site Safety:
Before beginning the necropsy, as stated previously, all on-site personnel should meet and be briefed on the plan for the necropsy and other important issues, especially safety. There are many dangers on-site, including, but not limited to: working around large equipment, large knives, use of chemicals, the movement of large pieces of tissue, and often uneven substrate, weather, and other environmental concerns. All personnel should have proper personal protective equipment for their role. When possible, one individual should be named as the Safety Officer to monitor the scene. All personnel should sign into the scene when they arrive and sign out when leaving. Discuss the importance of keeping track of all tools, and never leaving knives or hooks resting in a carcass. All injuries should be reported immediately to the on-site coordinator.

External Examination:
Once the animal is at the necropsy site, make another careful assessment of the external condition, noting swellings, scars, lacerations, contusions and other lesions. Take many photos of noted abnormalities. Liaise with the relevant catalog holders to ensure the right images are acquired. For instance a right whale needs images of all callosities, scars, flukes, and flippers. Humpbacks require ventral fluke images. Ensure images are taken of all aspects that will assist with photo-identification of the individual as well as record the standard suite of measurements. This can often be done while the necropsy crew is assembling. The initial process is much like that for small cetaceans: 1) Photos and video; 2) Human interaction evaluation; 3) Morphometrics; 4) Blubber thickness.

Internal Gross Examination:
The most dangerous aspect of this is the first incision. Be sure to have the crew stand back while one experienced cutter decompresses the abdomen and thorax with a careful, iterative incision to avoid any explosive decompression event. Remove the blubber in circumferential slabs, allowing blubber thickness to be measured on the blubber that remains on the carcass. Note all areas of hemorrhage, edema, swelling and abscessation. Look for focal changes in color pattern and texture. Patterns of change that are widespread and uniform are often post mortem in nature. Take histology samples of all identifiable as well as suspect tissues – they can always be discarded later, but cannot be retrieved once buried or disposed. Have multiple individuals examine as much of the carcass as possible. Many eyes see different things. Proceed logically through the carcass using the gross necropsy report form as a prompt to ensure all organ systems are examined. Follow the same organ by organ process as described for small cetaceans.

Sample preparation and analysis: See Section 2: Sample Management

Report Preparation: See Appendix A.

At Sea Examination of Whale Carcasses

Where distance offshore, cost, carcass condition or other factors preclude towing a large whale carcass to shore for examination, there is some benefit to the limited examination that can be undertaken at sea in certain situations. Such events need careful coordination and rarely succeed unless the carcass has been satellite or VHF tagged, or aerial support is available on the day of the attempt, as relocation of the carcass can often be difficult.

Necropsy Logistics:

The following approaches have been used by members of the North East Region Stranding Network for the examination of large whales at sea. Prior to leaving shore all necessary equipment should be packed and accessible.

Documentation:

Slowly circle the carcass to obtain images (photograph and video). Observe and note the degree of scavenging and extent of decomposition. Note body condition (robust, emaciated, *etc*.). Try to obtain photos of the fluke if possible (specifically the trailing edge and the ventral surface) and other species-specific aspects suitable for photo ID (dorsal fin, callosities, scars, etc.). Any and all media are appropriate and every effort should be made to document the animal using multiple media: digital still photos, 35mm photos, and video.

Be sure to examine the carcass for evidence of human interaction (entanglement marks, scars, ship strike, *etc*.). Fully document any suspected evidence using digital, video, and still photos. Sample any areas of possible or suspected HI for histology whenever possible.

Next, measure the total length of the animal. This can be challenging at sea, as some of the carcass may be at depth (often the flukes hang down in the water column). As you approach the carcass, be aware of the likely presence of sharks. The length will not be the “standard length” as the carcass is belly-up, but one can obtain a reasonable estimate. To measure, lay the tape along carcass to obtain total length . If necessary, the tape can be “pinned” to one end to hold it in place while the tape is played out (forceps stuck through the end of the tape and into the blubber will accomplish this). Alternatively a large vessel can be laid alongside the whale and the position of the head and tail marked on the vessel at a moment in time and the distance measured.

In significant sea states, a partial external examination can be conducted using aerial and underwater pole cam video. Analysis of such material frame by frame later can reveal substantial information about rope marks, propeller wounds, lesions, *etc*.

Crew:
If using a small boat, a minimum of five people is ideal on the sampling boat: 1 boat operator, 2 "hookers" to hold boat to the carcass, 1 cutter, 1 sample handler/data recorder. Usually one of the "hookers" can use a free hand to pass sample collection jars to the cutter and also pass tissue samples from the cutter to the sample handler to collect. Personnel on the large support vessel should serve as observers, documenters, and shark spotters.

Sampling:
Where there is essentially no sea state, or at worst a long swell, it has been possible to obtain internal samples to a limited degree from free-floating large whale carcasses. Most carcasses present ventral side up, making access to tissues feasible. Some are heavily shark scavenged from underneath, but often the viscera are still intact. Dissection is best done with an extra long- handled flensing knife. Carcasses can be worked from moderate sized ships (assuming a platform close enough to the water), or smaller boats. If possible, secure lines around the flipper and tail stock to lash the vessel alongside the whale (be sure to carry a safety knife with you to sever these lines if necessary). If attaching lines is not possible, two persons each with a whale hook on either end of the vessel (bow and stern) can hold the whale and vessel together if the vessel is small.

The animal should be opened up with a long cut along the mid ventral line from sternum to anus. Make an initial exploratory cut to determine the level of gas build-up inside the animal prior to proceeding with the ventral midline incision. The underlying organs emerge much more readily if the cut is truly mid line. Samples can be obtained from the colon, bladder, small intestine and stomach in addition to skin, muscle, and blubber. Obviously this is in no way a complete necropsy, but it will allow analysis for biotoxins, contaminants, *etc*. Large whales are quite broad, making sample collection from a boat alongside very challenging, as most of the organs of interest are in the midline. Given the significant risk of unexpected shark attack, getting out of the vessel is not recommended, so do what can be done using long handled knives, hooks, bailers, and suction devices from a stable vessel platform. Do NOT stand on the carcass at any time.

Sampling Preparation:
Pre-label a set of bags, Nalgene jars and vials to take to the carcass for initial sample collection (See attached sample collection guide). Small tubes and jars can be used as bailers once an organ has been opened. Where intestinal contents are scant, a large knife can be used as a scraper to remove contents adherent to the mucosa. A large turkey baster can also be useful in obtaining samples from stomach, colon, bladder, *etc*.

Sample collection:

1. If possible, collect a **blood** sample into a red top blood tube. This can be done on male carcasses by severing the penis and collecting a sample as it bleeds out. In females (and males from which blood cannot be collected from the penis) blood can be collected from the flukes, behind the eye, or snout.

2. Collect a **skin** sample. The carcasses tend to be fairly decomposed and often desiccated. The skin is usually peeling off. Try to collect a sample that is in good condition (*e.g.*, not crispy). Place it in a whirl pack.

3. Collect a **blubber** sample (approx. 10x10x5cm), store in whirl pack.

4. If access permits, incise region at and forward of genital slit. Collect a **muscle** sample (approx. 10x10x5cm) and place it in a whirl pack. The bladder should be a white fibrous bag immediately under the blubber/ muscle coat. Incise bladder and bail out available **urine** with a centrifuge tube, turkey baster or syringe. Place in a centrifuge tube for storage. Collect 2 tubes if possible.

5. Beneath the bladder the colon will be a white tubular structure. Incise the wall and re move available contents (**feces**). They are usually pasty green and the consistency of toothpaste. If possible, use a Nalgene bottle for both collection and storage. You may need to use your knife to scrape the inside of the colon to extract feces.

6. Continue incision cranially along the ventral midline to the sternum, making lateral cuts if need be, to allow the body wall to fall away. Scoop up the largest chambers (stomach) that are evident behind the liver (if visible). Incise and sample **stomach con tents** if present. (Use a Nalgene bottle to collect the samples or scoop them out with a knife, then store in the Nalgene bottle). Sample **liver** if intact: approx. 10x10x5cm in a whirl pack.

7. The kidneys lie along each side of the body wall in the abdominal cavity. If visible, collect a sample of one **kidney** (approx. 10x10x5cm), place in a whirl pack.

8. If possible collect an eye and store in a Ziploc bag.

9. If any evidence of human interaction was noted during carcass examination, sample appropriate tissue if possible. Store frozen or in formalin as appropriate.

Sample processing and storage:

1. Once back onboard the main vessel, process samples immediately.

2. Bagged samples: prepare a second set of bags with full labels to double bag samples. This reduces mess and provides a second label. (Remove blubber, liver, and kidney samples from original bag, wrap in acetone-washed aluminum foil, and place back in original bag before double bagging.) To ensure identification of tissues, an ID tag bag can be placed within the sample bag with the actual tissue. Please refer to the sample management section of this manual for details.

3. Skin sample: cut small pieces of skin and place in DMSO vials before double bagging the remaining sample.

4. Jars and vials: wipe down outside of each container. Fill out a Tyvek tag and tape to outside of container using clear packing tape. Be sure not to cover the existing info on the label tape.

5. Be sure to fully clean all gear between whales to avoid cross contamination. Use new scalpel blades for each animal's skin samples and use a clean cutting surface.

Quick Sample Collection Guide

Sample collection can be guided by the steps outlined in the Section 2: Sample Management of this manual. However, sampling from large whales is slightly different and decomposition makes collection difficult. The following is a brief out line of samples to collect and method of storage as described above. (Note: **BOLD** face indicates priority sampling)

Collect in whirl packs or Ziploc bags: **Skin,** blubber, muscle, liver, kidney, eye.
Collect in Nalgene jars or centrifuge tubes: **Urine, feces, stomach contents**
Collect in red top tubes: **Blood**

Appendix A. Blank Gross Necropsy Report

Necropsy Examination Report

CCSN#___-_____
Tag color/# _____
Species_____

Event Info	Animal Info
Strand date: _____	Sex: M F CBD
Recovery date: _____	Length: _____cm / in / ft
Euthanized / Died	Weight: _____lbs / Kg
Date & TOD: _____	Pup / Calf / YOY / Sub-adult / Adult / CBD
Necro date & time: _____	Condition at Stranding: 1 2 3 4 5 6
Storage prior to necropsy: _____	Condition at Necropsy: 1 2 3 4 5 6
Stranding location: _____	Human Interaction: Yes / No / CBD / NE
_____	Mass Stranding: Yes / No
Lat/Long: _____N/_____W	# animals: _____

Necropsy Summary – Differential diagnosis from gross exam:

History

Necropsy Observations: Please note general observations of color, condition, textures, etc. even when utilizing NA= not applicable, NE= not examined, NSF= no significant findings, NVL= no visible lesions. List weights (g) next to each organ examined.

External Exam

Body Condition: robust thin emaciated CBD

Skin/Hair coat (color, condition):

Necropsy Examination Report

CCSN#___-_____
Tag color/# _____
Species_____

Wounds/scars:

Lesions:

Parasites:

Nostrils/Blowhole:

Mouth (tongue, teeth condition, ulcers)/ /Mucous membranes (color):

Eyes (discharge, color, ruptures): **(R)** **(L)**

Ears: **(R)** **(L)**

Genital slit/anus:

Umbilicus: Pink Open Healed

<u>Musculo/Skeletal System</u>

Blubber:

Necropsy Examination Report

CCSN#___-_____
Tag color/# _____
Species_____

Muscle:

Diaphragm:

Skeletal:

<u>Circulatory System</u>

Pericardium:

Heart:

Vessels:

<u>Pulmonary System</u>

Trachea:

Bronchi:

Lungs (color, condition, edema, congestion, consolidation, granulomas, emphysema, lesions):
(R)

(L)

Necropsy Examination Report

CCSN#___-_____
Tag color/# _____
Species_____

Tracheobronchial Lymph:

<u>Gastro Intestinal System</u>

Esophagus:

Stomach (contents, ulcers, mucosa, parasites):

Small Intestine:

Large Intestine:

Colon:

Peritoneum, mesentery, omentum:

Liver (color, congestion, lesions, size):

Gall Bladder/ Bile Duct/ Pancreaticoduodenal duct (color, amount):

Pancreas:

Associated Lymph:

Necropsy Examination Report

CCSN#___-_____
Tag color/# _____
Species_____

Urinary/Reproductive Systems

Kidneys (reniculi differentiation, color, condition):
(R)

(L)

Bladder:

Testes / Ovaries: Immature / Mature

(R) **Lx W x H cm:**

(L) **Lx W x H cm:**

Mammary glands:

Uterus/ Cervix/ Vagina:

Pregnant? : Y / N / NA (male) / CBD

Lymphatic System

Spleen:

Scapular Lymph node:

Mesenteric Lymph node:

Necropsy Examination Report

CCSN#___-_____
Tag color/# _____
Species_____

Other Lymph (list location):

Endocrine System

Adrenals:
(R) **Lx W x H cm:**

(L) **Lx W x H cm:**

Other:

CNS

Spinal cord:

Brain:

Pterygoid Sinuses:

Other

Peritoneal cavity:

Abdominal cavity:

Thoracic cavity:

Thyroid:

Internal Parasites (location, type, #)

Necropsy Examination Report

CCSN#___-_____
Tag color/# _____
Species_____

SUMMARY- Differential Diagnosis from Gross Exam:

CARCASS DISPOSITION:

Soft tissue:
Skeleton:

PROSECTORS (list names and primary prosector signature)

SAMPLES/Disposition
See attached list

PHOTOS/VIDEO
Camera Roll# Frames: Description:

ASSOCIATED DATA SHEETS

- ❑ **NMFS Data Report**
- ❑ **Human Interaction Protocol**
- ❑ **Pinniped / Cetacean Data Record**
- ❑ **necropsy/ archive sample list**

Researcher Sample Collection List

Researcher	Affiliation	Sample type	# of samples	Method of storage/location

Appendix B. Guidelines to Writing a Gross Necropsy Report.

The most important things to remember when writing a gross report are:

1. Describe what you see, smell, feel, and hear.

2. Do not worry too much about using all technical terms. Learning the language will come with time. Write it how you see it.

3. Provide a detailed, but concise, description of each individual organ. Record NVL (no visible lesions) or NSF (no significant findings) if no abnormalities are observed. Never leave a field blank.

4. Common objects may be used as analogies but should never stand alone. It is helpful to describe what you see first, followed by the analogy.

5. Be aware of the organs in relation to other tissues.

6. Describe both external and internal findings of each tissue.

7. Follow the report systematically to ensure that all organs are examined and described.

8. Be sure to write the summary of gross findings or morphological diagnosis **immediately** after the conclusion of the necropsy while the details are still fresh in your mind.

With these criteria considered, the necropsy report should enable the pathologist to identify the pathologic process and connect multiple gross conditions to accurately diagnose a cause of death.

The following list of questions and answers have been provided to assist with describing abnormal lesions found grossly:

Where is it? Dorsal, ventral, lateral, medial, proximal, distal, cranial, caudal, anterior, posterior.

What is the distribution? Diffuse, disseminated, focally extensive, multifocal, coalescing, segmental, transmural

How big is it? Give dimensions in cm (length x width x height) and estimate volume in mls or ccs.

What is the shape? Round, spherical, ovoid, crescent, nodular, conical, lobular, tortuous, discoid, bulbous, sessile, stellate, reticular, fusiform, irregular, loculated, branched, amorphous

What does it feel like? Wet, dry, tacky, hard, firm, soft, friable, gas-filled, viscous, gelatinous, gritty, resilient, rubbery, granular, flaccid, de pressed, raised, smooth, rough, nodular, grooved, crusted, spongy, thick, thin.

What color/ pattern is it? Mottled, patchy, mosaic, translucent, opaque, dark, pale, degree of demarcation, striated, primary colors, multicolored –list all

To what extent is it affecting the tissue? < 10, dozens to hundreds, % of tissue

Is it odorous? Strong or faint smell, ammonia-like.

Appendix C. Human Interaction Evaluation Form and Instructions.

PROTOCOL FOR EXAMINING MARINE MAMMALS FOR SIGNS OF HUMAN INTERACTION

Exam Information *(fill in or circle most appropriate)*

1 Field #: _____ Species: _____

2 Examiner: _____ Recorder: _____

3 Date of exam:_____ Condition code (at exam): 1 2 3 4 5 CBD

4 Preservation: alive fresh frozen frozen/thawed Body condition: emaciated not emaciated CBD

5 Documentation: digital print slide video Image disposition:_____

6 Integument : normal abnormal decomposed % Skin missing: <10% 10-25% 25-50% >50%

7

Explanation of terms:
YES = I have examined the area and found signs of human interaction
NO = I have examined the area did not find signs of human interaction
CBD = I have examined the area and could not determine whether there were signs of human interaction (i.e. the part was missing, degraded, or signs were ambiguous)
NE =I did not examine the area
NA = this animal does't normally have that part (i.e. seals have no dorsal, dolphins have no rear flippers)

	WHOLE BODY EXAM	YES	NO	CBD	NE	NA	Image taken (Y or N)
8	Head/appendages removed *(with instrument)*					X	
9	Pelt removed *(with instrument)*						
10	Body sliced *(with instrument)*					X	
11	Gear/debris present on animal					X	
12	Gear retained *(name & contact info in Comments)*			X	X		X
13	External pathology *(pox, tattoo lesion, abscess)*					X	
14	Natural markings *(scars, tooth rakes, unusual pigmentation)*					X	
15	Other HI lesions *(gaff, gunshot, propeller, healed HI)*					X	

16 Predation/scavenger damage *(circle all anatomical areas where damage hinders evaluation; numbers coincide with anatomical areas below)*: 17 18 19 20 21 22 23 24 25 26 27 28 29 30 NONE

FILL IN TABLE FOR **ALL POSSIBLE FINDINGS OF HI**

Do not fill in for natural markings/other lesions.

	DETAILED EXAM OF ANATOMICAL AREAS	YES	NO	CBD	NE	NA	Type of Lesion: impression	laceration	abrasion	other	Origin of Lesion: Gear: twine/line	net	unknown	monofilament	multifilament	unknown	Other: propeller	other	CBD	image taken?
17	rostrum/snout																			
18	mandible																			
19	head																			
20	R front appendage																			
21	R body																			
22	dorsum/dorsal fin																			
23	L front appendage																			
24	L Body																			
25	ventrum																			
26	peduncle																			
27	R rear appendage																			
28	L rear appendage																			
29	flukes/tail																			
30																				

Field #:_____

	INTERNAL EXAM	YES	NO	Partial	CBD	Image taken	Detailed Info *(circle all that apply)*
31	Internal exam conducted				X	X	*Details in Comments section -use line number*
32	Bruising/blunt trauma			X			*Details in Comments section -use line number*
33	Skeleton examined				X		*Details in Comments section -use line number*
34	Broken bones present			X			*Associated tissue reaction: YES NO CBD*
35	GI tract examined *(circle contents)*				X		*intact prey debris/gear partially digested empty hard parts only other*
36	Lungs/bronchi examined				X		*Details in Comments section -use line number*
37	Lung/bronchi contents			X			*froth fluid air* (color:)
38	Other pathologies noted			X			*Details in Comments section -use line number*

39 **Comments** (*note line number from left margin before each comment*):

40 **Signs of Human Interaction Observed:** YES NO CBD (transfer to Level A Datasheet)

41 **Stranding Event History/Circumstances:**

42 **FINAL HUMAN INTERACTION EVALUATION:** If you circled YES above (#40), evaluate the external exam, necropsy, caracss condition and circumstances surrounding the stranding event to answer the question below.

What is the likelihood that the observed signs human interaction contributed to the stranding event?

0: CBD 1: Improbable 2: Uncertain 3:Probable 4: Certain

43 **Justification:**

PROTOCOL FOR EVALUATING MARINE MAMMALS FOR SIGNS OF HUMAN INTERACTION

Introduction

Evaluating marine mammals for signs of human interaction requires consistent, objective examination by trained personnel. This document is meant to accompany formal training by experienced stranding network participants. This new protocol is divided into an objective data collection section and a more subjective final diagnosis. The primary goal of this protocol is to determine whether evidence of human interaction is present on the animal. The secondary, and more difficult, goal is to determine whether human activities contributed to the stranding event. A positive score for signs of human interaction results from an objective evaluation of an animal or carcass. This evaluation does not attempt to determine whether the signs of human interaction occurred before, during or after a stranding event and does not attempt to qualify the severity of the interaction.

The final, subjective human interaction evaluation takes into account the circumstances of the stranding event and the animal's physical condition. A high score indicates that human activities most likely caused the stranding. A low score indicates that although signs of human interaction are present, the likelihood that the interaction caused the stranding is very low. For example, old, healed, propeller scars on a known whale are unlikely to have caused a stranding during a domoic acid event and a dead dolphin calf covered by debris on a beach following a hurricane is unlikely to have died due to entanglement.

Determining the cause of death is not an objective of this protocol. Without further evaluation such as histopathology and review by veterinarians, pathologists and/or other experts, the exact reason for stranding and cause of death cannot be accurately determined.

Human interaction (HI) data illustrate where problems between marine mammals and humans occur. When collected carefully and consistently, these data can be used to describe the types of interaction taking place (*e.g.* monofilament net, multifilament net, small or large vessel interaction, ingestion of debris, *etc*.), thus providing a sound scientific basis for policy and management decisions. The nature of strandings makes it inadvisable to use human interaction data to estimate mortality or changes in the mortality rate due to human interaction.

Definitions

In order to effectively evaluate marine mammals for signs of human interaction, you must understand what you are looking for. Below are terms and explanations of data sheet sections:

For most of the sections, you must choose among the following answers:

YES you have examined the area (*i.e*. left front appendage, or snout) and you found signs of human interaction

NO you have examined the area (*i.e*. left front appendage, or snout) and you found NO signs of human interaction

CBD (Could not Be Determined) which means either: (1) you have examined the area and could not determine whether the marks you saw were signs of human interaction, (2) you could not properly examine the area because it was degraded (scavenged, skin/pelt

Document developed by CCSN and VAQS (9/2007) with funding from the John H. Prescott Grant Program

missing, mangled, etc.), or (3) you could not examine the area because it was missing (removed, decomposed)

NE you did not examine the area (an explanation as to why is often helpful – *e.g*. it was too dark; the animal was to large to roll over, etc.)

NA this question is not applicable to this animal (*e.g*. it is a seal and doesn't have a dorsal fin, or it is a dolphin and doesn't have rear appendages)

Strategy for filling out the human interaction data sheet

Each new line on the data sheet is numbered in the left hand margin. These numbers serve two purposes: (1) each number corresponds to a section within these instructions with details about how to fill in that line; (2) the line numbers should be entered in the comments section on the second page of the data sheet to indicate to which item the comment refers.

Page 1:

EXAM INFORMATION: Fill in or circle the most appropriate answer for each of the fields.

1 *Field #:* unique identifying number originally assigned to the animal by response personnel. Note: the field number NEVER changes. If other filing numbers are added or accession numbers from other institutions are added, they should be noted as "additional identifiers".
Species: note the genus and species, or common name of the animal.

2 *Examiner*: the person evaluating the animal.
Recorder: the person recording the information on the data sheet.

3 *Date of exam*: the date that you are conducting the human interaction evaluation.
Condition Code (at exam): the condition code of the animal at the time of the human interaction evaluation. Use Smithsonian Institution condition codes (Geraci and Lounsbury, 1993).

4 *Preservation*: circle one of following - ALIVE, FRESH (not previously frozen), FROZEN (completely or partially frozen while exam was conducted), or FROZEN/THAWED (previously frozen, but completely thawed before exam).
Body condition: circle one of following - EMACIATED (clearly thin, concave epaxial muscle, obvious neck, ribs, scapulae, hip bones, and/or vertebral processes), NOT EMACIATED (robust or slightly thin, but not fitting the description of emaciated above) or CBD could not be determined (bloated, decomposed, not examined, etc.).

5 *Documentation*: circle all forms of photo/video documentation that apply.
Image disposition: indicate which camera, disk, tape, *etc*. that images were taken or stored on and the acronym of the organization that is maintaining them.

6 *Integument*: (skin, fur, hide) circle one of following - NORMAL (as if it were healthy and alive), ABNORMAL (conditions not associated with decomposition such as: alopecia, skin lesions, sloughing, abrasions, etc.) or DECOMPOSED/SCAVENGED (post-mortem changes such as peeling, sunburn, or scavenger damage).
% Skin missing: Circle the most appropriate number. Note that this does not apply to alopecia (fur loss) but to SKIN loss.

7 *Explanation of terms*: definitions of common terms used throughout the data sheet.

WHOLE BODY EXAM: Before beginning a detailed exam, take a look at the whole animal. If possible, look at all angles and surfaces. Following your whole animal exam, check the most appropriate choice for each category. If you check YES or CBD, describe what you see in the

Comments section on the next page, noting the appropriate line number. Indicate whether you collected an image of an area with a Y (Yes) or N (No) in the *Image taken* section. If you are unable to examine any areas, note the details in the *Comments* section.

8 *Head/appendages removed* (*with instrument*): Check YES if the head or other appendages (limbs, dorsal fin, fluke, *etc*.) appear to have been removed from the animal with an instrument (*e.g.* if there are obvious straight line cuts or straight nicks to the bone). In the lower 48 states of the US, this would be consistent with mutilation. In other areas, such as AK, this may be evidence of the legal harvest of a marine mammal. It is essential to work with local communities and agencies to interpret your findings in these cases. Check NO if all appendages are intact. Check CBD if you are unsure why an appendage is missing or if you cannot examine all appendages. If an appendage was completely removed by scavenging or predation (*e.g*. shark bite removed entire dorsal fin) you should check CBD.

9 *Pelt removed* (*with instrument*): – Check YES if the pelt appears to have been removed with an instrument (knife, scraper). Check NO if the pelt is intact (even if the animal's skin is intact but the hair/fur is missing). Check CBD if you are unsure (due to decomposition, *etc*.) of whether the animal's pelt was removed. Again, removal of the pelt in most regions of the US would be considered mutilation; however, in areas where harvesting is permitted, care must be taken in interpreting and documenting the interaction. Check NA if the animal has no pelt (cetacean or manatee).

10 *Body sliced* (*with instrument*) – Check YES if the carcass appears to be sliced with one or more cuts (from a knife or other blade), consistent with either legal harvest or mutilation (as above, dependent on the region). Multiple parallel cuts are often indicative of propeller wounds and should be noted under the *HI Lesions* category. Check NO if the body is intact or open body cavity is obviously due to natural causes (*e.g.* scavenging, predation). Check CBD if the body cavity has been penetrated and you are unsure of the cause.

11 *Gear/debris present on animal*– check YES if the animal is entangled in gear (net, line, pot, buoy, line with hook, *etc*.) or debris (anything else). Check NO if there is no gear/debris on the animal. Check CBD if you are unsure for any reason (*e.g*. gear/debris is found on, but not around the animal, or gear/debris was reported on the animal but apparently removed before you responded). Note *gear/debris present on animal* = YES if tags are present on the animal.

12 *Gear retained* – Check YES if the gear was retained by a stranding network or NOAA enforcement official. Note the name and contact information if the gear was retained by anyone other than your organization. Check NO if the gear was not retained. Check NA if there was no gear/debris present on the animal.

13 *External pathology* – If the animal has any lesions that appear to be disease-related such as pox lesions, tattoo lesions, abscesses, or other unexplained lumps, bumps or sores, check YES. Check NO if the animal has no disease-related lesions. Check CBD if you observe lesions and are unsure of their origin or if the integument is too degraded to assess.

14 *Natural marking* – If the animal has any natural markings (*e.g*. tooth rakes, unusual pigmentation, any non-HI scars) check YES. If the natural marks hamper your examination please note in the COMMENTS section. If there are no natural markings, check NO. If you cannot tell if there are any marks or are unsure of the origin of marks/scars check CBD.

Document developed by CCSN and VAQS (9/2007) with funding from the John H. Prescott Grant Program

15 *HI lesions* – Note lesions that may be associated with human interaction (fresh or healed entanglement or propeller scars, gaff marks, gunshot, healed HI scars, brands, *etc*.). Check YES if any human interaction lesions are observed. Check NO if no other lesions are observed. Check CBD if you observe lesions and are unsure of their origin or if the integument is too degraded to assess. A detailed exam of these lesions will occur in the next section.

16 *Predation/scavenger damage* – If there is evidence of predation or scavenger damage, circle the number(s) that correspond to the anatomical areas where evidence is seen. If the area affected is not numbered, circle *#30*, and note the area in the table below (*e.g.* genital slit, umbilicus, tongue) and note details of the damage in *Comments.*

17-29 **DETAILED EXAM OF ANATOMICAL AREAS**– Use this table to record findings of all suspected or possible evidence of human interaction. This means that any mark that the observer believes is consistent with some type of HI should be noted here. In addition, any marks for which the source Could not Be Determined, but that do not appear natural, should also be recorded in this table. Do NOT record information on natural markings or other lesions in this space. Examine the animal carefully starting at the head and working caudally down the right, then left, side, finishing with the tail or flukes. For this section, indicate whether you observe any SIGNS OF HUMAN INTERACTION in each *anatomical area* by checking the YES, NO or CBD column. If you were not able to examine an area, check NE, if it does not apply to your animal, check NA. Be consistent; examine anatomical areas in the same order each time you do an exam.

TYPE OF LESION- If you checked YES or CBD in any area, proceed to the *Type of Lesion* section and check all columns that apply.

- An *impression* occurs when a line or net leaves an indentation but does not lacerate or abrade the skin/pelt. Impressions left by net or line usually wrap around the leading and/or trailing edges of a fin, flipper or fluke. Impressions on the leading edge of an appendage may line up with a similar mark on the trailing edge.
- A *laceration* occurs when the skin/pelt is cut. Net and line usually leave linear lacerations. These lacerations may be evenly spaced along an appendage (indicating net) and may be accompanied by impressions.
- A *penetrating wound* occurs when a foreign object punctures or deeply penetrates the body, generally characterized by a small external wound and a wound tract that extends deep into the tissue and often into the body cavity. Sources of penetrating wounds include gaff, knife stab, spear, arrow, gunshot (especially bullet), *etc.*
- A *healed HI scar* is similar to a natural scar in pigmentation, but exhibits similar characteristics to the other types of lesions described here (*e.g.* linear scars on leading edges of appendages consistent with entanglement, parallel scars consistent with prop strike, *etc.*). It is as important to note healed HI scars as it is to note recent (unhealed) HI wounds. Evidence of HI, even if healed and not likely associated with the stranding event, should still be scored positive (YES) for HI.
- An *abrasion* occurs when gear or debris rubs an area and scrapes the skin/pelt without forming an obvious laceration. This often occurs with heavy line or twine entanglement or when loose or trailing ends of gear/debris rub (abrade) parts of the body.
- Choose *other / CBD* for any other types of lesions and describe in the comments section.

Document developed by CCSN and VAQS (9/2007) with funding from the John H. Prescott Grant Program

ORIGIN OF LESION - Once you determine the type of lesion, move to the origin of lesion section and check all that apply.

LINE is made up of many individual strands (multifilament) and is large in diameter. It is used for moorings, tow lines, forms the float and lead line of nets and attaches buoys and anchors.
TWINE is a small diameter line and can be multi- or mono- filament. Twine is constructed of various materials and is combined in different ways:

MONOFILAMENT twine – a single strand of nylon twine that leaves a single, straight, narrow impression or laceration (Figure 1, A).

MULTIFILAMENT – line or twine made up of multiple strands of material that are twisted or braided together and can leave a distinctive impression (a series of parallel, angled lines or ovals, Figure 1, B and C). If heavier twisted or braided line rubs on a body part or becomes tightly wrapped, it can cause an abrasion.

NET – nets can be made of either monofilament or multifilament twine and have various characteristics: twine diameter, square mesh size (knot to knot), and stretch mesh size (diagonal between opposite knots of a mesh with one knot between; Figure 2). Net impressions are often characterized by either a criss-cross pattern or a bunching of impressions with or without knot marks evident where lines intersect.

Based on the descriptions above, indicate the origin of the lesion:

- *Twine/Line* - select TWINE/LINE if the impression, laceration or abrasion is consistent with the descriptions above, but is not indicative of interaction with a net.
- *Net* – select NET if the marks are consistent with the descriptions above. Nets made of monofilament may leave multiple impressions or lacerations, but each lesion is a straight furrow.
- *Other/CBD* select this column if the marks appear consistent with entanglement or interaction with some type of gear, but you cannot determine which type.

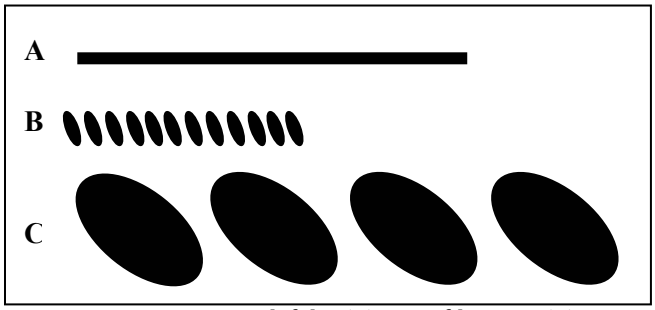

Figure 1: Impressions left by (A) monofilament, (B) twisted twine and (C) twisted line. Impressions are most visible on cetaceans.

If you checked *Twine/Line*, *Net, or Other/CBD,* indicate whether lesions were caused by *monofilament* or *multifilament* gear. Select *CBD* if you observe linear marks and you are unsure of the origin.

Document developed by CCSN and VAQS (9/2007) with funding from the John H. Prescott Grant Program

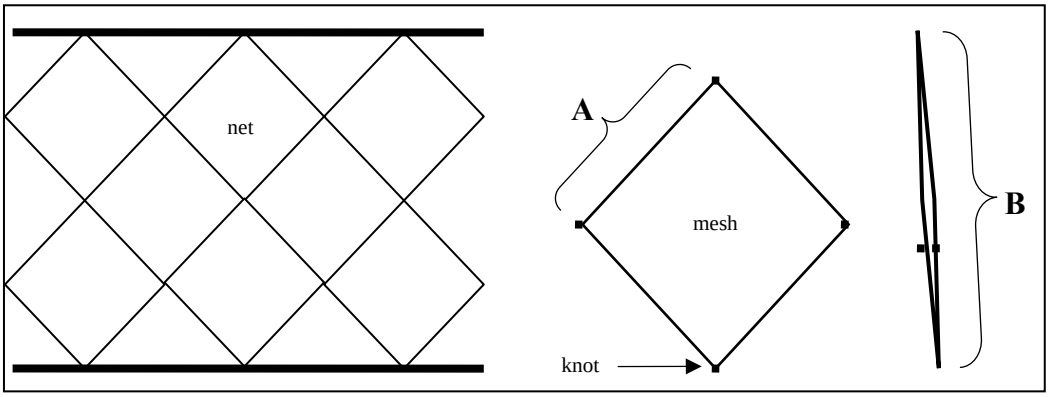

Figure 2: Typical net design. Nets are measured by the depth and length of the meshes hung between the top and bottom lines (float line and lead line on gill nets) and the horizontal length of the meshes. The mesh size can be measured from knot to knot (A) which is called the square *or* bar *mesh size or (B) at it's maximum diagonal width which is called a* stretch *mesh size.* Twine *size is the diameter of the twine the makes up the mesh.*

If the lesion you noted was not made by gear (line, net/twine), check the appropriate box to indicate the source:

- *Propellers* usually leave deep, roughly parallel lacerations (Figure 3). Lesions can be (A) straight, (B) Z or S-shaped, (C) curved, or open in the middle with thin trails (not illustrated). Large vessels may bisect an animal. Propellers have different sizes, numbers of blades, pitch, and configurations. Vessels can have a single propeller or two propellers separated by varying distances. Two propellers can be mounted on the same shaft rotating in different directions. The latter configuration causes very unusual lesions, unlike those in Figure 3.

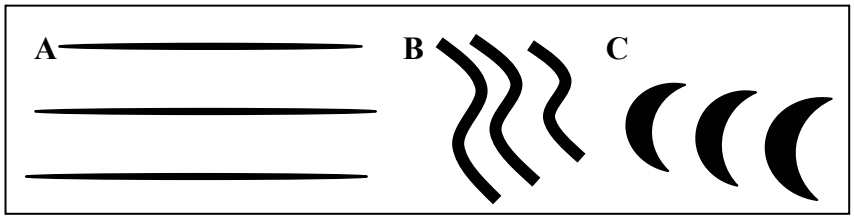

Figure 3: Types of propeller lesions left by different styles and sizes of propeller. The length, depth and spacing between lesions can provide information as to the type of propeller and vessel.

- *Gunshot* wounds vary based on the weapon used (shotgun, rifle, hand gun) and the distance from the weapon. Gunshot wounds can be very difficult to identify through gross exam, but can be characterized by single (bullet) or multiple (pellet) puncture/penetrating wounds. Radiographs are often necessary to confirm the findings.
- *Other/CBD*- select this column for lesions with other origins including, gaff, arrow, and debris entanglement, *etc*. or if you are unsure of the origin of the lesion(s).

Every area that scores YES or CBD should have an IMAGE TAKEN with identifying information (field number, date of stranding, species, examiner, subject of image, *etc*.) and a scale (small ruler or something of known size). If film or disk space is not limited, take pictures of all areas. Note Y (yes) or N (no) in the IMAGE TAKEN column.

Every area that scores YES or CBD should have a comment associated with it. Number each COMMENT with the corresponding line number for that anatomical area.

Document developed by CCSN and VAQS (9/2007) with funding from the John H. Prescott Grant Program

30 If you find lesions in an area not listed in the Detailed Exam table, add the area here and complete the table as explained above.

Page 2:
FIELD # - Be sure to fill out the field number on both sides of all pages associated with this animal.

INTERNAL EXAM – An evaluation is not complete without a thorough necropsy (internal examination). Some forms of interaction are only evident through internal exam (*e.g.* ingestion of debris or gear) and a final interpretation may change if an animal with external evidence of HI is found to be suffering from disease, pregnancy complications, injuries, etc. Some observations support a diagnosis of HI (*e.g.* for fishery interactions-full stomach, froth in lungs) and others provide evidence for HI although nothing was noted externally (*e.g.* stomach full of man-made debris). Be sure to note the date of the internal exam in the INTERNAL EXAM box.

31 *Internal examination conducted* – If you were able to examine the entire animal, check YES. If you did not examine the animal internally check NO. Check PARTIAL if you examined part of the animal (*e.g.* abdominal cavity only), then describe in the *Comments* section what was examined.

32 *Bruising/blunt trauma* – indicate if you see any focal area of bruising (discrete area, not diffuse along an entire body region). Note whether the area is associated with an external lesion. If it is not associated with a penetrating lesion or wound, it should be considered blunt trauma. If you check YES or CBD, note the size of the area and the tissue depth (*e.g*. sub-dermal to blubber, into muscle, through muscle and into mesenteries and organs) in the *Comments* section (do not confuse diffuse post-mortem blood pooling with bruising).

33 *Skeleton examined* – Check YES if the entire skeleton was examined. Check NO if no bones were examined. Check PARTIAL if only some of the skeletal elements were examined. If you check PARTIAL, note in *Comments* section what was examined (*e.g.* examined skull, head, left ribs and flipper, but not right side or vertebral column).

34 *Broken bones present* - Note whether you observed any broken bones.
Associated tissue reaction -Examine the tissue around the break(s) and circle whether any tissue reaction has occurred (hemorrhage, fibrous tissue, swelling at bone ends, *etc*.). If you are unsure, check CBD.

35 *GI tract examined* – Check YES if the entire GI tract was examined. Check NO if none of the GI tract was examined. Check PARTIAL if only some elements of the GI tract were examined and note which areas were examined in the *Comments* section (*e.g*. stomach, but not intestines). Note in the *Detailed Info* column the predominant condition of the contents. Circle *debris/*gear if non-prey items (plastic, line, hooks, *etc.*) are found. Use the comments section to describe the region of the GI tract (e.g. esophagus, stomach chamber, intestine, or colon) and its contents (*e.g*. fish, squid, crabs, mussels, milk, plastic bag, unknown). Stranded animals with full stomachs are often suspect cases. Ingestion of gear or debris is considered a human interaction.

36 *Lungs/bronchi examined* - Check YES if both lungs were thoroughly examined. Check NO if the lungs were not examined. Check PARTIAL if you performed a partial examination.

37 *Lungs/bronchi contents* – Circle all that apply in the Detailed Info column and describe the contents of each lung, including content volume, in the *Comments* section.

38 *Other pathologies noted* – Note whether any other pathologies were observed, describe in *Comments* section.

Document developed by CCSN and VAQS (9/2007) with funding from the John H. Prescott Grant Program

39 **COMMENTS** – The details of what you observe are required in the section. Provide comments for each item for which you checked YES or CBD. When describing lesions, include measurements (*e.g*. length, width and depth, distance between lesions), location (*e.g.* measurement from nearest landmark – 20cm caudal of the right flipper), color, shape and texture. Note the characteristics of the edges (*e.g.* jagged, straight, rounded) and the direction of linear lesions (*e.g*. wraps from leading edge of dorsal fin to trailing edge on left side). Number each set of comments using the corresponding line number for that row on the data sheet. Use extra pages if needed and be sure to note the animal's field number in the upper right margin. If this information is provided in the necropsy report or other data sheet, reference that material here.

40 **SIGNS OF HUMAN INTERACTION OBSERVED** – Review your exam notes and circle YES if you observed any signs of human interaction on the animal. Circle NO if you thoroughly examined the animal and did not find any signs of human interaction. Circle CBD if: (1) you did not examine the animal thoroughly, (2) decomposition or scavenger damage hampered the exam, or (3) you are unsure whether marks on the animal were caused by human interaction. This is an objective analysis. It does not take into account the animal's physical condition, the timing of the human interaction with respect to the stranding or the circumstances surrounding the stranding. TRANSFER THIS INFORMATION TO THE SIGNS OF HUMAN INTERACTION SECTION ON THE LEVEL A DATA SHEET.

41 **STRANDING EVENT HISTORY/CIRCUMSTANCES** – provide any information about the stranding event or circumstances surrounding the event that would be helpful in determining the HI diagnosis (*i.e.* fishing, drilling, or other activities, oil spill, unusual mortality events, previous sightings of animal, unusual behavior prior to stranding, *etc*.). Note any objective details provided by the initial reporter, these may be answers to questions you have asked (*i.e*. Was there any blood in the water next to the animal? What did it look or smell like when you first observed it? How was the animal positioned (belly up, on its side) when you first observed it?).

If harassment is suspected, objectively describe events in this section including names and contact numbers for witnesses and any authorities that were contacted.

42 **FINAL HUMAN INTERACTION EVALUATION** – This section should be completed if you circled YES under *Signs of Human Interaction Observed* (#40). It should be completed after filling out the entire data sheet. This section is subjective and takes into account the animal's physical condition, necropsy findings, the timing of the human interaction with respect to the stranding, and the circumstances surrounding the stranding. Most importantly it takes into account the evaluator's level of experience. If you have not conducted many evaluations or are not familiar with the region, you may be unable to make an accurate final evaluation and should circle CBD.

For this section you are estimating how likely you think it is that the documented human interaction contributed to the stranding event. This estimate or confidence interval is expressed in a scale of 0-3, as described below. Circle the most appropriate number. The higher the number, the more likely it is that the interaction contributed to the stranding. If you do not feel that you can provide and evaluation, circle 0 – Uncertain (CBD). [Note: We

do not say that the human activity *caused* the stranding because the human interaction could have indirectly contributed to the event without being the direct cause of the stranding.]

0. Uncertain (CBD) – You cannot provide an evaluation of the likelihood that human interaction contributed to the stranding (*e.g.* a Code 4 carcass is found with propeller marks; it is too decomposed to determine whether the interaction was pre- or post-mortem).
1. Improbable - It is unlikely that the observed human interaction contributed to the stranding (*e.g.* there are healed entanglement scars on the flukes of a known humpback whale that died with a full-term fetus; it is unlikely that the past entanglement contributed to the stranding).
2. Suspect – It is possible that human interaction contributed to the stranding (*e.g.* there is a small amount of plastic found in the animal's stomach, but you are unsure of its effect).
3. Probable - It is very likely that human interaction contributed to the stranding (*e.g.* clear evidence of mutilation, a full stomach, plus one mark that may be indicative of entanglement).

43 **JUSTIFICATION** – Provide a brief justification of your answer for the *Final Human Interaction Evaluation* score. Include information from all sources available to you.

Document developed by CCSN and VAQS (9/2007) with funding from the John H. Prescott Grant Program

Appendix D. Equipment Necessary for a Complete Necropsy on Pinnipeds and Small Cetaceans.

Most supplies can be found at local supply stores or in lab supply catalogues. Equipment that is difficult to locate is denoted with an asterisk and the supplier's information is listed at the bottom of the page.

Equipment list:

Documentation

Digital camera with sufficient battery power and memory cards
Disposable camera (for back-up)
Photo ID card
Forms: necropsy report with sample inventory list, morphometric data form, HI evaluation form
Clipboards
2 – 4 Sharpie markers (fine point and ultra fine point)
Pencils and black ink pens
Label tape*
Packaging tape

Sampling

Measuring tape
Ruler with cm
Tyvek labels*
2 x 3, 3 x 5 or 4 x 6, 8 x 10, and 9 x 13 write-on zip lock bags
4 x 6 whirlpack bags
Laundry tags*
2 1.0L bottles filled ¾ with 10% NB formalin for histology samples
1 250ml – 1000ml bottle filled ¾ with 10% NB formalin for life history samples
1 ½ gallon seal tight container for stomach contents
DMSO vial
Plastic centrifuge tubes(10-20mL)
Syringes (various sizes)
Aluminum foil
Acetone

Sampling (cont.)

EtOH and saline for parasites
Culture swabs – aerobic and anaerobic
Butane flame
Cutting board
Sharpening steel
5 toothed forceps
2 - 3 Stainless steel dissecting scissors
5 Sharp stainless steal knives 6"- 9"
Box of scalpel blades
Scalpel blade handles (3 -5)
Scalpel blade remover
Flat head screwdriver (tooth extractor)
Stryker saw
Chisel
Hammer
Cotton string
Small pan scale for tissue weights (mg or g)
Large scale for full carcass weight

Safety/Personal Protection

First aid kit
Sharps container
Latex or Nitrile gloves
Rubber boots
Aprons
Protective eyewear
Masks

Clean-up

Paper towels
Heavy Duty construction bags
30 gallon barrels for soft tissue disposal and skeletal remains

Flagging tape—www.LSS.com, Flagging tape, biodegradable
Laundry tags— www.golps.com,Daily Delivery Tag, 1-Ply fiber;
Label tape— www.VWR.com
Tyveck tags—www.LSS.com; Blank tags; white tyveck.

Appendix E. Pinniped Morphometric Data Record.

Cape Cod Stranding Network, Inc.
Pinniped Data Record

Field #: _____
Accession #: _____
Species: _____
Condition Code: 1 2 3 4 5
Sex: M F CBD
Length: _____
Weight: _____
Human Interaction: Y N CBD
Carcass: Fresh Frozen
Field Notes:

Date of Death: _____
Date of Recovery: _____
Date of Necropsy/Exam: _____
Observers: _____
Location: _____
Lat/Long: _____N/_____W
Photos: Y N **Roll #:** _____
Video: Y N **Tape #:** _____
Necropsy: Y N; **Location:** _____
Tag Color / #: _____

Morphometrics: **Left / Right** **Measurer:** _____ **Units:**_____

Straight Line (taken from tip of nose to…)

1 (total, straight to tip of tail)	.
2 (total, curvilinear)	.

Appendages

3 (Front flipper, ant.)	.
4 (Hind flipper, ant.)	.

Girths

5 (axilla)	.
6 (Max, location)	.
7 (Umbilical)	.

Blubber Thickness (mm)

5-Dor	.
5-Lat	.
5-Vent	.

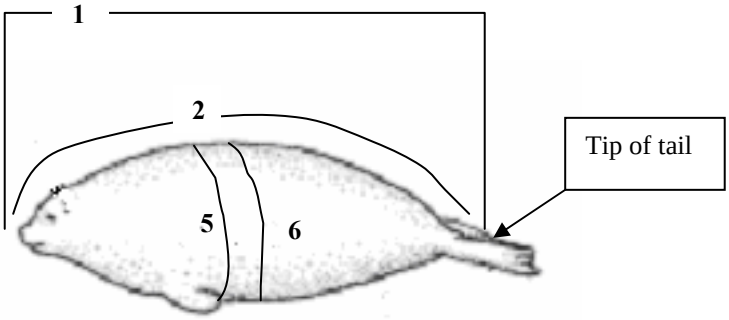

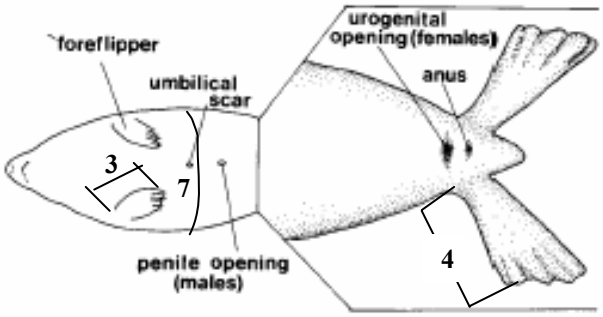

Emaciated: **Yes / No / CBD**

External Exam:
(lesions, scars, parasites, etc.)

Tooth Counts: LL:_____ **UL:**_____ **LR:**_____ **UR:**_____

Appendix F. Cetacean Morphometric Data Record.

Cape Cod Stranding Network, Inc.
Cetacean Data Record

Field #: _____
Accession #: _____
Species: _____
Condition Code: 1 2 3 4 5
Sex: M F CBD
Length: _____
Weight: _____
Human Interaction: Y N CBD
Carcass: Fresh Frozen
Field Notes:

Date of Death: _____
Date of Recovery: _____
Date of Necropsy/Exam: _____
Observers: _____
Location: _____
Lat/Long: _____N/_____W
Photos: Y N **Roll #:** _____
Video: Y N **Tape #:** _____
Necropsy: Y N; **Location:** _____
Tag color:_____ **Tag#:**_____

Morphometrics: **Left / Right** **Measurer:** _____ **Units:**_____

Straight Line (taken from tip of upper jaw to…)

1 (total: to fluke notch)	.
2 (apex of melon)	.
3 (gape of mouth)	.
4 (center of eye)	.
5 (center of blowhole)	.
6 (ant. insert pec.)	.
7 (ant. insert d. fin)	.
8 (d. fin tip)	.
9 (umbilicus)	.
10 (center of genital slit)	.
11 (anus)	.
12 (fluke notch to anus)*	.

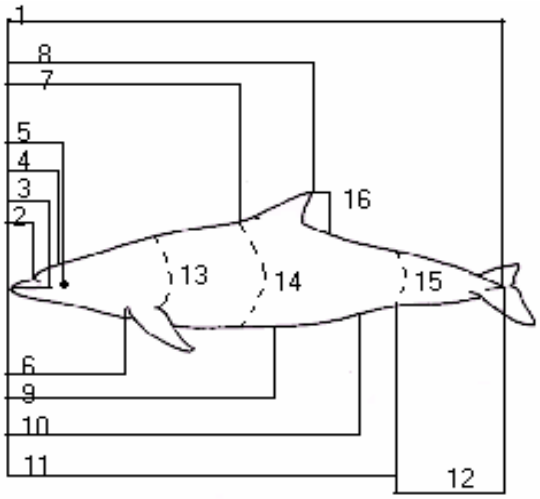

Girths

13 (axilla)	.
14 (ant. insert d. fin)	.
15 (anus)	.

Appendages

16 (d. fin height)	.
17 (pec.fin ant. length)	.
18 (pec. fin max width)	.
19 (fluke width)	.

Blubber Thickness (mm)

13-Dor	.
13-Lat	.
13-Vent	.

Emaciated: **Yes / No / CBD**

Tooth Counts: LL:_____ **UL:**_____ **LR:**_____ **UR:**_____

External Exam:
(lesions, scars, parasites, etc.)

© Cape Cod Stranding Network, Inc.

Appendix G. Blank Photo ID Card.

CCSN#:

Date:

Species:

Location:

Comments:

Observer:

Cape Cod Stranding Network, Inc.
P.O. Box 287
Buzzards Bay, MA 02532
508.743.9805

Appendix H. Necropsy Sample Inventory Check List.
Note: This is only an example. Sampling should not be limited to this list.

		Standard Samples				Pinn. Only			UME ONLY
		Life History	Genetics	Contam.	Histo.	Herpes	Morbilli	Brucella	Biotox
Tissue		(Frozen or fixed as below)	(Frozen &/or DMSO)	(Foil wrapped and frozen)	(2 sets in 10% NBF)	(Frozen)	(Frozen)	(Frozen)	(Frozen -80º)
Skin									
Teeth		FR							
Oral mucosa									
Blubber									
Muscle									
Liver									
Kidney (R)									
Kidney (L)									
Stomach									
Lung (R)									
Lung (L)									
Tracheobronchial Lymph									
Spleen									
Blood/Serum									
Esophagus									
Trachea									
Prescapular Lymph									
Heart									
Diaphragm									
Pancreas									
Mesenteric Lymph									
Intestine									
Adrenal (L)									
Adrenal [R]									
Colon									
Bladder									
Testis		FX							
Uterus		FX							
Ovary		FX							
Feces									
Stomach Contents		CH							
Urine									
Aqueous humor									
Milk/Mammary Discharge		FR							
Brain									
Other:									
Lesions (list)		FR							
Fungal growths		FR SW							
Parasites (EtOH)									
Culture (swab)		SW	List sites:						

This page intentionally left blank.

Glossary of Terms

Acute	Rapid onset.
Amorphous	Lacking a definitive shape.
Caseous	Resembling cheese.
Catarrhal	Containing mucous.
Chronic	Refers to a persistent or lasting disease, or one that has developed slowly.
Caudal	Towards the tail.
Coalescing	To come together as to form one.
Cortex	The outer most layer of an organ, such as lymph nodes, kidney, or adrenal glands.
Cranial	Towards the head.
Cyamids	Whale lice.
Demarcate	To mark out the limits or boundaries of something.
Differential Diagnosis	List of potential etiologies for a suite of observations used to focus further diagnostic testes to adequetly discriminate and derive the actual etiology.
Diffuse	Entire surface involved.
Dorsal	The upper, or top, side of the animal's body.
Ectasis	Widening; dilation of a hollow organ.
Edematous	Excessive accumulation of serous, gelatinous fluid in tissue spaces or body cavity.
Emphysema	An abnormal distention of body tissue caused by retention of air.
Etiology	The cause of the condition(s).
Etiologic Diagnosis	The cause(s) of the condition(s) observed using all available diagnostic data.

Fascia	Soft tissue component of the connective tissue system that interpenetrates and surrounds muscles, bones, organs, nerves, blood vessels and other structures.
Flaccid	Lacking firmness.
Fusiform	Spindle-shaped.
Granulomatous	Highly vascular fibrous connective tissue involved with the resolving phase of an inflammatory process.
Histology	The study of tissue sectioned as a thin slice, using a microtome.
Histomorphology	The form and structure of an organism or any of its parts as seen through a microscope.
Histopathology	The microscopic study of diseased tissue.
Hyperplasia	An abnormal increase in the number of cells in an organ or a tissue with consequent enlargement.
Hypostasis	Post-mortem pooling of blood in dependant part of the body.
Immunohistochemistry	The process of localizing proteins and other components in cells of a tissue section exploiting the principle of antibodies binding specifically to antigens in biological tissues.
Lateral	Along the length, or side or the animal's body
Lividity	The settling of the blood in the lower (dependent) portion of the body, causing a purplish red discoloration of the skin
Loculated	Having divided into small cavities or compartments
Maxilla	Upper jaw
Medulla	The inner part of an organ
Milliary	Resembling a millet seed
Morphologic Diagnosis	A summary of the grossly evident abnormalities

Morphometric	Measurement of the form of organisms or of their parts.
Mosaic	Patterned in small squares.
Mottled	Spotted or blotched with different shades or colors.
Mucopurulent	Containing mucus and pus.
Mucosa	The moist, inner lining of some organs and body cavities.
Multifocal	More than one location.
Opaque	Impenetrable by light; neither transparent nor translucent.
Parenchyma	The functional parts of an organ in the body; the bulk of a substance.
Parietal surface	Surface of tissues that are in contact with the body wall.
Pathology	The study and diagnosis of disease through examination of organs, tissues, cells and bodily fluids.
Peracute	Very acute; violent.
Pericystic	Alongside the bladder.
Petechia	A small purplish spot on a body surface, such as the skin or a mucous membrane, caused by a minute hemorrhage.
Pleura	The thin covering that protects and cushions the lungs.
Purulent	Containing, discharging, or causing the production of pus.
Resilient	Capable of returning to an original shape or position, as after having been compressed.
Reticular	Net-like.

Serosa	Smooth membrane consisting of a thin layer of cells which excrete a fluid, known as serous fluid.
Serous fluid	Bodily fluids that are typically pale yellow and transparent.
Sessile	Permanently attached; not free moving.
Steatosis	Abnormal retention of lipids within a cell.
Stellate	Arranged like a star; radiating from the center.
Stenosis	Abnormal narrowing in a blood vessel or other tubular organ or structure.
Tortuous	Having many turns; winding or twisting.
Ventral	The underside, or belly of the animal's body.
Visceral surface	The surface of the organ that faces adjacent organs.
Viscous	Having relatively high resistance to flow.
Zoonosis	Infectious disease that can be transmitted from animals to humans or humans to animals.

Resources

BARCO, S. and K. TOUHEY. 2007. In prep. *Handbook for Recognizing, Evaluating, and Documenting Human Interaction in Stranded Cetaceans and Pinnipeds.* Virginia Aquarium Stranding Program, 717 General Booth Blvd., Virginia Beach, VA 23451

DIERAUF, L.A. and F. GULLARND. 2001. *Marine Mammal Medicine*. CRC Press, Boca Raton.

DYKSTRA, M. 1993. *A manual of techniques for applied biological electron microscopy*. Springer.

GERACI, J.R., and V.L. LOUNSBURY. 2005. *Marine mammals ashore: a field guide for strandings*, Second Edition. National Aquarium in Baltimore, Baltimore, MD.

KETTEN, D., S. CRAMER, and J. ARRUDA. 2007. Procedure for the Removal, Fixation, and Preservation of Cetacean Ears. Pages 3.1 to 3.22 https://reefshark.nmfs.noaa.gov/pr/mm/sysadmin/nrsworkshop/ *in* N. YOUNG ed. *Odontocete Salvage, Necropsy, Ear Extraction, and Imaging Protocols.*

LUNA, L. 1992. *Histopathologic methods and color atlas of special stains and tissue artifacts*. American Histolabs Gaithersburg, MD.

MCLELLAN, W., S. ROMMEL, M. MOORE and D. PABST. 2004. Right Whale Necropsy Protocol. Final Report to NOAA Fisheries for contract # 40AANF112525 U.S. Department of Commerce, National Oceanic and Atmospheric Administration, National Marine Fisheries Service, Office of Protected Resources, Silver Spring, Maryland. Pages 51 pp.

MEYER, D. and J. HARVEY. *Veterinary Laboratory Medicine, Interpretation and Diagnosis, 3rd edition*. Elsevier.

O'HARA, T. and T. O'SHEA. 2005. Toxicology. Pages 471 *in* L. DIERAUF and F. GULLAND eds. *Maine Mammal Medicine.* CRC Press, Boca Raton, FL.

RAVERTY, S. and J. GAYDOS. Unpubl. Killer whale necropsy and disease testing protocol. Pages 1-63. Animal Health Center, Ministry of Agriculture, Food and Fisheries, Abbottsford, British Columbia, Canada.

YOUNG, N. 2007. Odontocete Salvage, Necropsy, Ear Extraction, and Imaging Protocols. Pages 1-171 https://reefshark.nmfs.noaa.gov/pr/mm/sysadmin/nrsworkshop/.

WYNNE, K. and M.SHWARTZ. 1999. *The Guide to Marine Mammals & Turtles of the U.S. Atlantic & Gulf of Mexico*. Rhode Island Sea Grant, University of Rhode Island, Narra gansett, RI.

50272-101

REPORT DOCUMENTATION PAGE	1. REPORT NO. WHOI-2007-06	2.	3. Recipient's Accession No.

4. Title and Subtitle
Marine Mammal Necropsy: An introductory guide for stranding responders and field biologists

5. Report Date
August 2007

6.

7. Author(s) Katie R. Pugliares, Andrea Bogomolni, Kathleen M. Touhey, Sarah M. Herzig, Charles T. Harry, and Michael J. Moore

8. Performing Organization Rept. No.

9. Performing Organization Name and Address
Woods Hole Oceanographic Institution
Woods Hole, Massachusetts 02543

10. Project/Task/Work Unit No.

11. Contract(C) or Grant(G) No.
(C) NA05NMF4391165
(G)

12. Sponsoring Organization Name and Address
National Oceanic and Atmospheric Association

13. Type of Report & Period Covered
Technical Report

14.

15. Supplementary Notes
This report should be cited as: Woods Hole Oceanog. Inst. Tech. Rept., WHOI-2007-06.

16. Abstract (Limit: 200 words)

This necropsy manual is designed to establish a base level of profiency in marine mammal necropsy techniques. It is written for stranding network members who do not have a formal pathobiological training and have limited knowledge of anatomy. Anatomical and pathological jargon has been kept to a minimum. This manual is divided into six sections: preliminary data, sample management, pinniped, small ceetacean, large whale (at sea and on the beach), and multiple appendices (A-H). A well-illustrated, carefully written gross necropsy report is essential to an adequate diagnostic investigation. Gross reports with significant detail and description tend to engender useful histopathological findings. A sample blank gross necropsy report and guidelines in writing a report can be found in Appendices A & B. Overall, this guide aims to lead the enquiring mind through the necessary steps to produce such reports. While this manual focuses on process and interpretation, it is important to understand that the gross necropsy is primarily about making detailed, descriptive observations without bias as to possible etiology. The necropsy should establish a list of differential diagnoses and the sampling be directed by an attempt to discriminate between them.

17. Document Analysis a. Descriptors

Necropsy
Pinniped
Cetacean

b. Identifiers/Open-Ended Terms

c. COSATI Field/Group

18. Availability Statement
Approved for public release; distribution unlimited.

19. Security Class (This Report)
UNCLASSIFIED

20. Security Class (This Page)

21. No. of Pages
131

22. Price

(See ANSI-Z39.18) *See Instructions on Reverse* OPTIONAL FORM 272 (4-77)
(Formerly NTIS-35)
Department of Commerce

Appendix E: Selected MMHSRP Protocols

Sample Collection and Analysis

E-6: Odontocete Salvage, Necropsy, Ear Extraction, and Imaging Protocols (available at: http://csi.whoi.edu/download/file/fid/1616)

Odontocete Salvage, Necropsy, Ear Extraction, and Imaging Protocols

Compiled and Edited by Nina M. Young

Contributing Authors

Julie Arruda
Alexander Costidis
Scott Cramer
Darlene R. Ketten
William McLellan
Eric W. Montie
Michael Moore
Sentiel Rommel

July 1, 2007

Cover Photographs

Two beaked whales: ©NAN HAUSER

Dwarf sperm whale on table: University of North Carolina at Wilmington Marine Mammal Stranding Program

PREAMBLE

The tissue-collection and -analysis protocol contained herein is designed to guide the collection of pathological and biological data in single and mass strandings of cetaceans, including those qualified as an unusual mortality event (UME). Its purpose is to provide for the systematic collection of data so that a post-hoc analysis of potential factors influencing cetacean stranding events can be performed. The protocol is not intended to promote a specific forensic diagnosis of causative factors contributing to a stranding event and cannot be used to determine whether a stranding event was caused by anthropogenic sound. The protocol can support long-term research activities investigating a range of natural and anthropogenic causes of cetacean strandings. The creators of the protocol disclaim any responsibility for the opinions, forensic interpretation, or misuse of data collected under this protocol related to stranding events putatively associated with anthropogenic sound.

ACKNOWLEDGMENTS

I would like to thank all of the authors who contributed chapters to this document. I would also like to especially thank the steering committee: Bob Gisiner, Bill McLellan, Michael Moore, Sentiel Rommel, Teri Rowles, Brandon Southall, and Douglas Wartzok for their time, guidance, preparation, and review of workshop documents and this report, and for their overall support. Special thanks also go to the workshop attendees for their participation in the workshop and review of the report: Edward Cudahy, David Doolette Andreas Fahlman, Antonio Fernandez, Wayne Gerth, Frances Gulland, Dorian S. Houser Paul Jepson, Darlene Ketten, Susanne Prahl, Dave Rotstein, Katie Touhey, Sean Sylva, and Tanja S. Zabka. I also greatly appreciate the time and outstanding efforts of the workshop rapporteurs: Andrea Bogomolni, Nadine Lysiak, and Regina Campbell-Malone. I wish to thank Angela Payne for the development and maintenance of the website for the workshop. Finally, I greatly appreciate the tireless efforts of Karen L. Lew, who edited and formatted this massive document for publication and distribution. The workshop and this report were undertaken with the support of the Office of Naval Research [Contract N00014-06-1-0298].

Nina M. Young
Ocean Research, Conservation and Solutions (ORCAS) Consulting

Chapter 1

INTRODUCTION

This protocol document has been developed to assist those people involved in cetacean-stranding-response activities to provide critical data for diagnosis of the event itself and to provide a better overall understanding of the role of human-made (anthropogenic) noise in strandings and stranding-related mortality. The primary purpose of this document is to develop practical guidance for immediate stranding-response action and ensuing data collection, tissue sampling, and preparation for analysis.

It is critical that diagnosis of any stranding event be approached classically without bias. This approach involves acquisition of available history; blood sampling as possible; careful external and internal gross examination; radiography and imaging as possible; sampling for histology, microbiology, and toxicology; and subsequent sample analysis, the steps of which are iteratively driven by the implications of accumulating data. Thus, each event must be analyzed without preconception. Only this approach makes possible full consideration and distillation of a list of differential diagnoses, in order to ultimately arrive at the most parsimonious conclusion regarding likely cause(s) of stranding and/or death.

So that the biology of acoustic-induced stranding can be placed in the most-consistent and best-possible context, the protocols provided in this document need to be applied, as practical, to future single and mass stranded cases of all cetacean species.

No single protocol can be applied to all situations. The detailed protocols are intentionally comprehensive to encourage collection of a full suite of samples and data under ideal conditions. The protocols herein are provided in an attempt to formalize and standardize the investigation of small cetacean strandings (including beaked whales) to better determine the causes of death.

There are numerous marine mammal necropsy protocols (Geraci and Lounsbury 2005; McLellan et. al. 2005), and several marine mammal programs have their own standard protocols. The authors recommend using the following protocols in conjunction with. Our protocols are an initial attempt to bring together the experience and varied approaches of some of the world's most experienced scientists and to begin to apply a rigorous, standardized approach to determining the case of death of stranded cetacean. These protocols are designed for use in the best-case scenario, where time is not limited. When time or resources are limited, or experienced personnel don't need the detail provided in these protocols, form-based protocols are also included. It is expected that the advice of those experienced in the field will continue to shape these protocols further. Thus, this document is a living document, and the intent is to periodically update it to reflect advances in stranding response, necropsy, and imaging protocols and clinical diagnosis. It is formatted such that the user has an area in which to take notes, provide comments, and highlight critical information.

STRANDING-RESPONSE REGULATORY REQUIREMENTS

As protected wildlife, odontocete (toothed) cetaceans are covered under local, federal, and international laws. A number of laws and regulations pertain to the recovery or possession of cetacean carcasses or their parts and to the rescue and recovery of cetaceans in distress. One must be aware of and follow these laws and regulations.

Stranding network responders are governed by a legal framework established by various federal, state or provincial, and regional authorities. The United States Marine Mammal Protection Act (MMPA) specifically prohibits the collection of animals (live or dead) or parts from them or any form of harassment, detention, or restraints—however temporary—without a permit. Exceptions include government officials acting in the course of their duties and other authorized individuals.

Marine mammal stranding networks in the United States make up one facet of a broader, more comprehensive program called the Marine Mammal Health and Stranding Response Program (MMHSRP), established in the late 1980s in response to

growing concern about marine mammals washing ashore in U.S. waters. Following are the MMHSRP goals:

- To facilitate collection and dissemination of data
- To assess health trends in marine mammals
- To correlate health with available data on physical, chemical, environmental, and biological parameters
- To coordinate effective responses to unusual mortality events

The MMHSRP program was formalized by the 1992 Amendments to the Marine Mammal Protection Act, and the National Marine Fisheries Service (NMFS) was designated as the lead agency to coordinate related activities. A NMFS authorization is required to respond to a stranded marine mammal; thus, NMFS works with stranding networks to respond to marine mammal strandings. Volunteer stranding networks were established in all coastal states and are authorized through letters of authorization from the NMFS regional offices. Through a national coordinator and five regional coordinators, NMFS oversees, coordinates, and authorizes these activities and provides training to personnel who are the first-line responders to stranded marine mammals.

PUBLIC HEALTH AND SAFETY ISSUES

Although there are few known zoonoses (diseases of animals transmissible to humans) associated with cetaceans, it is likely that some remain unknown and, therefore, are likely to be difficult to diagnose and treat if contracted. Of the known zoonoses, *Erysipelothrix rhusiopathiae* is the best known and is a frequent cause of “seal finger” or erysipeloid (a dermatitis or cellulitis of the hand) if humans are bitten or have contaminated cuts. This disease is very common in the marine environment on all marine mammals and fish and has been diagnosed in cetaceans on many occasions (Dunn et al 2001). Risk of entry is via breaks in the skin (Duignan 2000). Mycoplasmas and Vibrio (Dunn et al 2001) are also known to be transmissible from cetaceans to humans.

When collecting samples, safety precautions should include basic hygiene and care around sharp objects; however, researchers and others overseeing a stranding response should

be aware of their state's occupational health and safety requirements.

HEALTH AND SAFETY RISKS

- Handling heavy carcasses—Marine mammal carcasses range in weight from 30 to 50,000 kg. Each carcass presents a different handling challenge. Where possible and necessary, use heavy equipment for moving carcasses. Small odontocete carcasses can be usefully moved with a chain or strong line tied though a hole cut in the dorsal fin. Always be aware of the risk of failing line; nylon line especially can recoil when it breaks.
- Handling biological material of unknown infectiousness risk—routine personal protection measures should be in place:
  - No food or drink near an animal
  - Protective clothing used at all times: e.g., rubber boots, waterproof bib pants, heavy-duty aprons, surgical scrubs, disposable gloves, eye shields, and face masks as appropriate.
  - Tools should be cleaned carefully with detergent and then in disinfectant. Sharps should be disposed in a dedicated sharps container.
  - Tissue waste should be disposed of appropriately.
- Use extreme care in handling toxic fixatives such as formalin. It is best transported to the beach packaged within a sealed leakproof outer container such as a screw-top bucket with a rubber gasket (see Lifelatch at http://www.m-m-industries.com)
- A first aid kit should be available.
  - Seek medical attention for bites, cuts, and other injuries; inform medical attendants of the source of the injury.
  - Disinfect all cuts with iodine or alcohol 70%.
- Use of sharp instruments: prior to any necropsy, safety protocols should be reviewed and any new

participants be shown how to handle any tools they might use

NECROPSY AND SAMPLE-COLLECTION GEAR LIST

The following is a suggested necropsy and sample-collection gear list taken from McLellan et. al. (2005).

NECROPSY GEAR

- digital camera (w/ disc space for at least 100 images) **OR** SLR camera with 28–70mm lens, macro lens, 2 rolls each of 50 Fujichrome, 64 Kodachrome, 200 Ektrachrome
- Hi or digital 8 video camera and video tape for 8 hours and storage media
- extra batteries for all previously listed electronic equipment
- handheld GPS (not mandatory)
- ID photo board to insert in all photo images; alternatively, see paper reference scales in subsequent necropsy procedure
- 2 metric tapes: 30m long (note: check end to see where numbers start)
- 2–3 data clipboards (Rubbermaid makes a plastic, rust-proof model)
- 30m of 2-cm braided line (examine for any abrasions or weak spots and remove)
- 30m of 1-cm line (examine for any abrasions or weak spots and remove)
- 1 very heavy (10cm wide) nylon towing strap—e.g., used by large vessel travel lifts
- 4–6 high quality knives with 12" blades and blade guard between blade and handle
- 4–6 high quality knives with 8" blades
- 4–6 high quality knives with 6" blades
- 2 diamond “flat” steels
- 2 draw-through knife sharpeners
- 2 pair ball shears or large boning shears
- 4 metal meat hooks: 2 feet long
- 4 metal meat hooks: 8 inches long
- 4 scalpel handles and a box of blades (take care loading and unloading blades onto or from handles)
- 4 large rat-tooth forceps
- 4 small forceps
- 2–4 plastic rulers: 15cm
- 2 plastic rulers: 30cm

- 2 plastic turkey basters for collecting urine and fecal samples
- 1 bow saw used for trimming tree branches: 1 meter long
- 1 long pry bar used for carpentry
- aerobic and anaerobic culturettes
- 100 Tyvek® tags for labeling
- fine point and large indelible ink Sharpies®
- permanent ink pens
- #2 pencils for recording data onto datasheets and histo cassettes
- several plastic 5-gallon buckets to store and wash gear
- 2 rolls of duct tape
- 2 boxes of 50-count, 2-gal. Ziploc® bags with write-on label
- 2 boxes of 100-count, 1-gal. Ziploc bags with write-on label
- 2 boxes of 100-count, 1-liter Ziploc bags with write-on label
- 1 large box of 50-count heavy garbage bags
- 2 large plastic cutting boards for cutting and photographing tissues
- set of sawhorses and 2' × 8' section of plywood to make workstation
- 1 box each of large, medium, small latex gloves
- 4 pairs each of fish-cutting gloves in large, medium, and small sizes
- boots, coveralls, and rain gear
- 2 headlamps
- 5 medium-to-large plastic coolers
  - 2 for dry-equipment storage for transport
  - 2 for tissue-containment on site and transport (get ½ full with slush ice)
  - 1 for food cooler for drinks, etc. (do not mix with above)
- 2 large plastic transport boxes
  - 1 for transport of rain gear and boots

  - 1 for plastic trash bags and Ziploc bags
  - 4–5 scrub brushes for cleaning gear
- Dawn dishwashing detergent
- safety glasses for those “going deep” into the whale

Tissue and Fluid Collection

- 1 cube of formalin with pour spigot: 20 liter, 10% buffered
- 2 gallons of 95% alcohol
- 6–8 plastic 1-liter jars with wide mouths
  - 2 boxes of 50-count large Ziploc bags
  - 2 boxes of 50-count small Ziplocs bags
  - 2 bread-box-sized waterproof plastic boxes for gross tissue collection
- histology cassettes
- 10 plastic syringes: 60 cc each
- 10 plastic syringes: 20 cc each
- 10 needles: 16-gauge

PROTOCOL FORMS

The necropsy and sample collection protocols are form-based to facilitate their use on the beach and in the laboratory. The protocols are provided to guide and assist personnel in conducting the necropsy and ear extraction. These forms contain information on sample collection and preservation, and, if completed legibly, can be scanned and become an integral part of the electronic necropsy report.

INITIAL RESPONSE AND LIVE-ANIMAL CLINICAL EXAM AND SAMPLING PROTOCOL

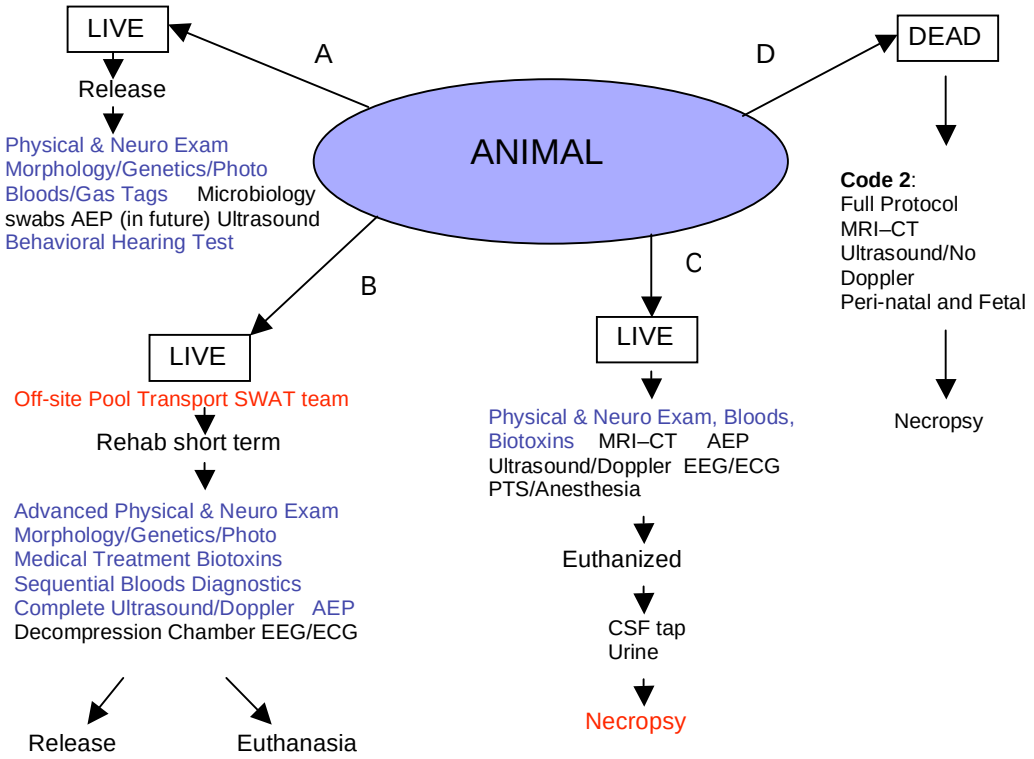

Figure 1.1 A decision tree for an organized triage approach. In this document we will provide a step-by-step process summary for each branch of the decision tree. The initial assessment should be rapid yet thorough. Under all branches of the decision tree, assessment should first include the collection of level A data.

Level A Data: Minimum Requirements (for each animal, complete NOAA Form 89-864 (see http://www.nmfs.noaa.gov/pr/pdfs/health/levela.pdf):

- Investigator: name and address (affiliation)
- Reporting source
- Species
  - Preliminary identification (by qualified personnel)
  - Voucher (supporting) material (photographs, specimens, including mandibles with teeth, tooth counts, and entire skulls)
- Field number
- Number of animals, including total and sub-groups (if applicable)
- Location
  - Preliminary description (local description)
  - Latitude and longitude (to 0.1 minute, if possible) with closest named cartographic feature as determined subsequently in the lab)
- Date (mm\dd\yy), time of first discovery and of data collection and specimen recovery
- Length (also girth and weight when possible)
- Condition (recorded for both discovery and recovery times)
- Code
  - **Code 1: alive**
  - **Code 2 (carcass in good condition):** fresh/ 'edible'; fresh smell; minimal drying or wrinkling of skin or eyes; eyes clear; no bloating, tongue and penis not protruded; blubber firm and white; muscles firm, dark red and well defined; brain firm; little gas in intestines.
  - **Code 3 (fair—decomposing but organs intact):** Some bloating may be present, possibly with tongue or penis protruded; mild odor, mucous membranes dry; eyes shrunken or missing; blubber blood tinged or oily, muscles soft and poorly defined; blood hemolysed; organs soft, friable, and mottled but still intact; gut dilated by gas; brain soft and fragile with reddish cast but surface features distinct.
  - **Code 4 (poor—advanced decomposition):** carcass collapsing; sloughing of skin; strong odor, blubber soft, possibly with pockets of gas or oil; muscle liquefying or easily torn; periosteum loose on bones; blood thin and black; organs identifiable but very friable, easily torn and difficult to detect; gut gas-filled; brain soft, dark red, containing gas pockets, pudding consistency
  - **Code 5 (mummified or skeletal remains):** skin may be draped over skeletal remains; any remaining tissues are desiccated
- Sex

LIVE-ANIMAL RESPONSE—BRANCH A

For live animals that are destined to be released, respondents should take four actions: (1) conduct a physical exam; (2) collect blood samples and perform a gas analysis on a subsample; (3) collect microbiology swabs; and (4) tag the animal. For the clinical examination, constantly record observations such as respiration rate and character; for other clinical signs, record observations as the opportunity arises (e.g., because you need to do some other procedure) or if there is a change in previously observed clinical signs. Changes in one clinical sign will likely result in changes to other clinic signs.

Physical Exam

After all Level A data have been collected, live animals should be given a physical exam. That includes the following:

- General Condition
  - Dorsal and cervical blubber and muscle mass. Photograph.
  - Record distribution and appearance of external lesions. Photograph and then record distribution on an outline drawing. Evaluate the condition of the skin; the condition will vary depending on the length of exposure. Note any drying, cracking, blistering, sloughing, and other traumatic injuries.
  - Awareness: Check for the presence or absence of reflexes, particularly the blowhole, which should be closed or should close if touched; the palpebral reflex to touch should result in lid closure. The anus should tighten when the surrounding area is touched.
  - Listen for vocalizations and note any audible sounds, apart from respirations, from blowholes. Whistles and high-frequency squeals, while possibly associated with stress, may be useful clinical indicators. Vocalizations diminish or cease in depressed animals.
  - Assess muscle tone by attempting to open the mouth or by resistance to traction of the

tongue or by assessing the ability of the cetacean to move.

  - Note any discharges.

- Cardiovascular and Pulmonary Systems
  - Record respiratory rate at regular intervals. The respiratory rate for cetaceans should be one to three per minute; however, there may be long periods of apnea especially if the animal is depressed or comatose. If the rate rises above 10/min when the animal is stressed (e.g., by handling), but then drops below this level once the stress is removed and the animal is made comfortable, it is a good sign. A consistently high rate carries a very bad prognosis.
  - Record heart rate.
    Listen to the heart or measure the heart rate by auscultating or palpating, medial to pectoral flipper at the level of the carpus (generally seen as a bend in the caudal border of the flipper). The heart rate may be very slow or weak and difficult to determine (e.g., may not be able to auscultate the heart at all in a medium-large cetacean). If the animal fails to exhibit tachycardia on inspiration, it is a grave prognostic sign.
- Body temperature.
  - This will only be useful if suitable rectal probes are available (minimum 30cm in length). Do not use glass. Normal values are 36.5° to 37.5° C (97.7° to 99.5° F). It may not be possible to take the temperature of a large cetacean in ventral recumbency.
- Neurological examination (see next page)

NEUROLOGICAL EXAMINATION

Date: **Time:** **Observer:** **Acc No:** **Total Score:**

Posture

1. Recumbent: sternal, dorsal, lateral: R/L
2. Body twisted: R/L (Stranding may result in neuromuscular damage causing the animal's body to
   to assume a "C" shape. Is the opening of the "C" to the left or the right?)
3. Opisthotonus (head and flukes pointing upward, limbs and body in rigid extension)

Mentation

1. Normal
2. Confusion and/or Disorientation
3. Obtunded
4. Coma

Abnormal Body Movements (each assigned 1 point)

1. Ocular: Nystagmus (slow drift of eye one way, rapid return):
   vertical/horizontal/postural/fixating/continuous (In which direction is the slow component?)
2. Strabismus: note position
3. Rapid blinking
4. Muscle fasciculations: note muscle or body part affected
5. Myoclonus (tremorlike activity)
6. Myotonus (longer duration muscle contractions)
7. Chorea (rapid, jerky, purposeful movements)
8. Athetoid (slow, writhing, purposeless movements)

Abnormal morphology of head (each assigned 1 point)

1. Drooping of lip on one side
2. Asymmetry of musculature (describe)

Responsiveness to a sound

1. Lifts and/or moves head
2. Moves eyes to observe
3. Nonresponsive
4. Seizures: note type of movements above

Locomotion

1. Able to swim normally
2. Able to swim slowly/reluctantly
3. Moves without use of fluke
4. Ataxic and/or Uncoordinated movements
5. <u>Unable to use foreflipper and fluke on same side (hemiplegia)</u>
6. Circling
7. Immobile

Blood Sampling

Blood samples provide an opportunity to evaluate the functional capacity of some organs. A broad spectrum of analyses can be performed, including plasma chemistry, hematology, antibody titers, and toxicology. Collect the following tubes of blood:

- 1 EDTA tube—*hematology*
- 1 serum separator tube—*serum chemistry*
  At least 1 mL of blood in a heparinized syringe or container—blood gasses. Separate the serum and freeze at –20° C for shipment, or refrigerate and ship using cold packs.
- 1 EGTA (ethyleneglycol-bis-N4-tetraacetic acid) tube or heparinized plasma—*catcholamines*
- 2 sodium citrate (clotting profile, glucose levels)—*clotting factors*
- 1 thrombin (FDP)—*clotting factors*
  - It is very important to make sure that the maximum draw has been obtained for the citrate and thrombin tubes.
  - Thrombin (FDP) tubes should be refrigerated but can only sit overnight before shipping.
- 2 serum separator tubes—*serum bank*

Record times of death and sampling. Place samples in a cooler or on ice, but do not freeze, and transport to the laboratory as soon as possible for processing.

When a delay of more than about 4 hours is anticipated, centrifuge the blood to separate the plasma or serum; these samples, free of red blood cells, can be frozen if delivery to the laboratory within 24 hours is impossible.

Allow blood in plain tubes or SST (serum tubes) to clot and for the clot to begin to shrink (room temp).

- Use EDTA blood to make three smears; chill remainder.
- Centrifuge all remaining blood samples (not EDTA) at 3000 rpm for 10 minutes. If no centrifuge is available, allow samples to stand, chilled, until the cells settle.

- Draw off clear liquid (plasma or serum) with a pipette, keep 2 mL of Li Heparin plasma and 0.5 mL of Fl Ox plasma aside; divide the remainder of all samples into 0.5–1 mL portions and freeze at –20° C or –80° C.
- Submit EDTA sample, the 2mL of Li Heparin Plasma, and the 0.5 mL of Fl Ox plasma to lab as soon as possible (must be processed at lab within 48 hours, preferably within 24 hours). Request full hematology and biochemistry profile.
- A blood smear is useful if samples for hematology cannot be analyzed within 24 hours.

Heart Blood in Plain Tubes (Disease, Toxicology, Hormones)

Freshly dead animals, including those euthanized by lethal injection, can sometimes be sampled in the same way as live ones. When procedures are carried out more than a few minutes after death, samples can be taken from the right ventricle of the heart with a syringe and needle (often the ventricles are contracted) In that case, collect blood from the caudal vena cava. 20–30 mL of whole blood is enough to run a comprehensive set of analyses.

- Allow blood in plain tubes (serum tubes) to clot and for the clot to begin to shrink
- Centrifuge at 3000 rpm for 10 min. If no centrifuge is available, allow the blood clot to shrink at room temperature for a couple of hours. Draw off clear portion (serum), divide into 0.5–1mL portions and freeze at –20° C or –70° C.

Collect Microbiology Samples

Using sterile swabs: Any orifices with discharges should be swabbed; also swab inside the blowhole as deep as possible. Place swabs in their accompanying transport media.

Chilled abnormal tissues (2–5cm cube in sterile container) (disease studies)

- Culturing and Submission of Tissues: Same Day
- Culturing by Swab:
    - Sear surface of tissue by dipping a knife or spatula in alcohol, lighting it (a small self-igniting propane torch also works well) and,

when it is hot, applying it to the surface of the tissue.

  - Slice into the middle of the tissue through the seared region with a sterile scalpel.
  - Insert a sterile bacterial swab into the middle of the cut, and then place the swab in culture medium.

Or, if no alcohol is available,

  - Cut a 3 × 3 to 4 × 4 cm section of tissue, chill, and submit to lab.
  - Laboratory can heat-sear the tissue in-house and culture.

- Always culture the tissue rather than an effusion, and always culture near the leading edge of the lesion rather than in the central area of necrosis
- Send to the lab, chilled, ASAP. If lab facilities are not accessible within 48–72 hours, freeze the swab and tissue (the colder the better). Request bacterial culture (aerobic and anaerobic).
- Select a 5mm slice, including healthy and diseased tissue, and place in 10% formalin.
- Freeze remainder.

Swabs of affected sites in transport media or frozen (disease studies)

- Send bacteriological swabs in transport media to the lab, chilled, ASAP. If lab facilities are not accessible within 48–72 hours, freeze the swab and tissue (the colder the better). Request bacterial culture (aerobic and anaerobic).
- Keep plain swabs frozen in case needed for microbial DNA.

Ultrasound—Guidance for use of ultrasound in live or dead odontocete cetaceans[1]

Ultrasound inspection of organs and blood vessels may be useful for the detection of bubbles produced by the off-gassing of tissues. *In vivo* inspections can capitalize on both two-dimensional (2-D) imaging and Doppler modalities to assess the presence or absence of bubbles in vessels and tissues. Results from post-mortem assessments are likely to be questionable, at best, unless made immediately following euthanasia. Post-mortem inspections will be limited to 2-D imaging modalities because Doppler inspections will be useless following death.

Vascular bubbles can be detected with both 2-D imaging and Doppler modalities. The former is more easily used by the untrained technician because the bubbles appear as reflective points flowing through the vessel. The use of Doppler is more specialized and will require some training prior to application, but it permits the acoustic detection of bubbles as they pass through the sound field. Both methods have been used to detect bubbles in human divers and tissue phantoms that mimic the depth of vessels potentially observed in odontocetes. The blood vessels that can be inspected with ultrasound will be limited by the resolution of the ultrasound system and the depth of penetration provided by the transducer. There is a trade-off between depth of penetration and resolution, so the ability to detect bubbles may decline with the depth of vessel inspection.

The reflectivity of an organ should, in theory, increase as reflective substrates accumulate within the organ. For example, the accumulation of microscopic bubbles within the liver or kidney should increase the reflectivity of that organ in a manner that is proportional to the amount of microbubble accumulation. This expectation is based on physical principles and has not been demonstrated in a cetacean. However, inspection of organs should still be performed because the presence of larger bubbles should be detectable, by the trained observer, as an anomaly in the field of view.

---

1 Respondents should note that, while ultrasound is a valuable diagnostic tool, it is important that, in the case of a freshly dead carcass, all ultrasound investigations take place as quickly as possible to avoid delaying the necropsy and causing further decomposition that might interfere with diagnosing the possible cause of the stranding. Respondents should use their judgment regarding the best course of action.

Following are recommendations of vessels for inspection in stranded odontocetes. These vessels are selected because of the ability to visualize or apply Doppler techniques to them via ultrasound. These vessels have been imaged in the bottlenose dolphin *(Tursiops truncatus),* and may or may not be visible in other odontocetes, depending on their depth and relationship to other tissues, organs, and air spaces. Consideration of vessel-specific blood flow should be given when applying Doppler to particular vessels. For example, blood flow within the portal vein has been shown to be sluggish in dolphins; thus, the sensitivity of the Doppler system should be set to the highest level (lowest flow) when investigating this vessel or other vessels expected to have low rates of blood flow.

Vessels and organs to inspect

- Portal vein (large vessel occurring 12–20 cm deep in dolphins; probably the easiest to visualize)
- Phrenic vein
- Brachiocephalic
- Ascending carotid artery (best observed with pulsed wave Doppler)
- Liver
- Kidney

Potential vessels and organs to inspect

- Epidural veins and retia
- Superficial veins
- Lymph nodes
- Pericardial plexus

Required Equipment

The depth of inspection and resolution of the system will depend on the design of the ultrasound head (the transducer). Similarly, Doppler capability is not available for all models of transducer. The user will need to determine specific system capabilities. The cost and summarized capability for two portable ultrasound systems are listed below. The listing is not an endorsement for any particular model of ultrasound, but rather a list of specifications for portable systems that have been used for vessel inspection in living odontocetes. When deciding on a system, consideration should not only be given to the depth of penetration, resolution, and imaging capability of the complete system, but also to the system's portability and

ruggedness. Portable systems are expensive, and the system's longevity must be taken into account. It should also be noted that the cost of transducers is in addition to the cost of the base system.

Ultrasound Base

- 2-D Imaging alone: Sonosite 180 Plus

  or

- 2-D Imaging and Doppler: Sonosite Titan, Sonosite MicroMax

Transducers

Deep penetration— C60 (obstetric/abdominal use—5-2 MHz curved array)

C15e (abdominal/thoracic use—4-2 MHz curved array)

- – provide depths of penetration up to ~25 cm
- – can be used with Doppler depending with which system it is coupled

Shallow penetration—L38 (vascular access/superficial imaging—10-5 MHz linear array)

- – provide depths of penetration up to ~7 cm
- – can be used with Doppler depending on with which system it is coupled

Video recording should be performed along with all ultrasound inspections. This provides for multiple review of recorded observations and more careful post-collection analysis. Portable recorders (DVR) that can interface with current ultrasound systems are available.

Morphology

See discussion in Chapter 2.

Genetics

Collect genetic samples in a minced 1×3 cm section of epidermis fixed in a super-saturated salt solution of 10% DMSO in water. Additional genetic samples can be collected from liver,

heart muscle, pericardium, and endometrium in DMSO if the carcass condition warrants it. Recently, researchers have been requesting frozen epidermis samples in plastic to be used to determine hormone levels, contaminants, and genetics. Collect a 10×10 cm section of epidermis, freeze it in a Ziploc bag, place on ice immediately, and transfer to a –80° C freezer as soon as possible.

Hearing Tests

Because of the concern for the potential impact of human-made sound on marine mammals and because odontocetes rely upon their hearing for communication and echolocation, hearing tests would provide useful information on potential causes of stranding as well as on the potential for release. Further, hearing tests on additional and/or new species of odontocetes would provide useful information having the potential for estimating the impact of future activities involving human-made sound in the oceans. Two methods of obtaining information on the frequency range and sensitivity of hearing exist: behavioral and auditory evoked potential.

Behavioral methods are the standard approach for audiometry in marine mammals. Several behavioral methods exist and, if an animal is determined to be suitable for behavioral audiometry, it is recommended that someone with experience in marine mammal behavioral audiometry be consulted. Behavioral hearing tests are time-consuming and can take many months to complete, particularly with a naïve subject (e.g., an animal that has never undergone behavioral training). The application of behavioral hearing tests will likely be restricted to rehabilitated animals deemed unsuitable for release to the wild.

Auditory evoked potential (AEP) methods are an electrophysiological means of testing hearing. The process involves recording electrical patterns (potentials or voltages) produced by the brain in response to a sound. AEPs are non- to minimally invasive and have been applied to odontocetes as large as the killer whale. The process is well developed in odontocetes, and methods of testing multiple frequencies simultaneously have reduced the testing time for the full range of hearing to less than 10 minutes in delphinids. Application of this technique requires the presence of an AEP system and personnel trained in the application of electrodes and sound

stimulus delivery. Multiple laboratories across the United States (Hawaii, West Coast, East Coast) have the equipment to perform these procedures as well as the experienced personnel to train stranding responders.

Tagging

Each carcass in a mass stranding should be tagged as soon as possible to manage specimens and avoid errors in recording individual case histories. Cattle ear-tags are easily applied to the trailing edge of the dorsal fin (Geraci and Lounsbury, 2005); make sure each animal has a single unique number assigned to it.

LIVE-ANIMAL RESPONSE—BRANCH B

In situations where live cetaceans are not to be released and will be removed to a rehabilitation facility for short-term rehabilitation, the following steps should be undertaken.

Prior to transport, respondents should conduct a physical exam and an ultrasound and Doppler exam in accordance with the instructions provided previously. Respondents should collect blood and begin a systematic sequential blood collection.

Once the cetacean has reached the rehabilitation facility, respondents should perform an advanced behavioral assessment and additional ultrasound measurements and continue sequential blood collection. If personnel and resources are available, staff should consider other diagnostic treatments such as Doppler, EEG/ECG, collection of samples for biotoxin, auditory evoke potential tests (behavioral hearing tests), X-rays, and MRI/CT scans (see protocol in Chapter 4).

LIVE-ANIMAL RESPONSE—BRANCH C

In those situations where live cetaceans are not candidates for rehabilitation and the animal will be euthanized, respondents should follow all of the procedures outlined under “Live Animal Response—Branch A” and as many as possible of those under “Branch B” and then take the necessary steps to euthanize the animal.

Once the animal is euthanized, urine, aqueous humor, and cerebral spinal fluid should be collected. After these samples

have been collected, perform an internal examination and necropsy using the procedure provided in Chapter 2.

FRESH DEAD OR EUTHANIZED ANIMAL RESPONSE—BRANCH D

If the animal is freshly dead (Code 2) or has been euthanized, respondents should follow the procedures outlined subsequently (in Chapter 3) for CT and MRI, the procedures outlined previously for ultrasound, and the necropsy protocol in Chapter 2. Note, however, that the necropsy of Code 2 animals should not be unduly delayed by CT, MRI, or ultrasound, especially if cold storage facilities are not available.

References Cited

Geraci, J.R., and V.J. Lounsbury. 2005. Marine Mammals Ashore; A Filed Guide for Strandings. U.S. National Oceanic and Atmospheric Administration.

McLellan, W., S. Rommel, M. Moore, D.A. and Pabst. 2005. Right Whale Necropsy Protocol. Contract Report, Marine Mammal Health and Stranding Response Program, National Marine Fisheries Service. Pp 1–39.

Dunn, J.L., J.D. Buck, and T.R. Robeck 2001. Bacterial diseases of cetaceans and pinnipeds. Pp 309–335 *In:* L.A. Dierauf and F.M.D. Gulland (eds.) *CRC Handbook of Marine Mammal Medicine*. CRC Press, Boca Raton, Florida.

Duignan, P.J. 2000. Marine Mammal Autopsy Techniques and Sample Collection. Pp 387–428. *Marine Wildlife: The Fabian Fay Course for Veterinarians (Proceedings 335)*. Postgraduate Foundation in Veterinary Science, Sea World, Gold Coast, Australia

Chapter 2—
Odontocete Necropsy Procedure

Sentiel Rommel[1]
William McLellan[1]
Alexander Costidis[2]
Michael Moore[3]

[1] Biology Department
University of North Carolina Wilmington
Wilmington, North Carolina

[2] Marine Mammal Pathobiology Lab
Florida Fish & Wildlife Conservation Commission
& The University of Florida, Gainesville, Florida

[3] Biology Department
Woods Hole Oceanographic Institution
Woods Hole, Massachusetts

June 2007

INTRODUCTION

This is a description of the procedures for the necropsy of odontocete carcasses. In recent years, mass strandings associated with high-intensity underwater sounds have presented new lesions associated with fat and gas emboli. This procedure incorporates suggestions to document these lesions and provides guidelines for a more complete examination of each case.

There are three purposes for a necropsy: (1) to collect natural and life history information; (2) to scientifically determine the most probable cause(s) of death; and (3) to properly collect appropriate samples to support research, life history, and cause-of-death investigations. The necropsy is also a source of important information for determining, documenting, and mitigating human-related causes of death.

When determining cause of death, it is important to document and consider both actual cause and circumstance of mortality. One should document both immediate and any secondary conditions contributing to mortality. The final most probable cause of death determination is actually an analysis of both cause and circumstance. For example, a dolphin found dead in a trawl net may be found to have died of suffocation secondary to forced submersion (drowning)—the circumstance of death was being caught in a net.

In addition to determining the most probable cause(s) of death, one must process each carcass in order to obtain general and detailed biological information. General information collected upon primary examination must include the following:

- Morphometrics
- Total body weight (TBW)
- Body condition
- Description and measurement of wounds and scars
- Photographs and sketches for individual identification
- Epibiota

More detailed information should include the following:

- Gross appearance of organs and tissues
- Description of fat stores
- Fullness of and prey items identified in the gastrointestinal (GI) tract along its entire length
- Documentation of natural, anthropogenic, and pathognomic lesions, congenital defects, and individual organ weights

Additionally, appropriate samples for toxicology, histopathology, microbiology, virology, and parasitology may be collected on a case-by-case basis, constrained mainly by decompositional state of the carcass and by sampling logistics; these samples may provide useful insights into normal and abnormal conditions.

NECROPSY PROCEDURE—PREPARATION

This written protocol is based on procedures followed at the Florida Fish and Wildlife Conservation Commission (FWC) Marine Mammal Pathobiology Laboratory (MMPL) and those followed at the University of North Carolina Wilmington. These directions are to accompany several illustrations of the left lateral aspect of a carcass (also see the illustrations of *Tursiops* gross anatomy in the CRC Handbook by Rommel and Lowenstein 2001). Lymph node is abbreviated LN and lymph nodes, LNN. The LN descriptions used herein are modified from Rommel *et al* (2002). The gross anatomy is based on that of the bottlenose dolphin, *Tursiops truncatus*. The terminology used herein is consistent (where possible) with the Illustrated Veterinary Anatomical Nomenclature by O. Schaller (1992).

PREPARING FOR A NECROPSY

Labels

Tissue labels should be written with bold, permanent markers such as pencils or fine-point *Sharpies,* which can be found at `<http://www.sharpie.com/sanford/consumer/sharpie/index.jhtml?_requestid=121078>`; histology pens or pencils should be used for tissue cassettes and labels submerged in formalin. Labeling should be on both sides of good quality paper. **Do not use ballpoint pens, inkjet printouts, or other**

water-soluble inks for labels or for data sheets! Tags and field data sheets should be made of waterproof, non-reactive material—e.g., Tyvek™ or *Rite In The Rain*™. Metal tags and tag parts should be nonreactive meta—samples should be packaged so that tags are not in direct contact with sample.

Collect one tissue per container, unless otherwise specified; label tissues according to tissue and sample type (e.g., histology, microbiology, virology, blubber for archive [for retrospective analyses], reproductive tract). Tissue labels should include the following:

- Test modality or sample
- Purpose of test
- Samples required
- Storage specifications

NECROPSY PROCEDURE—INITIAL OBSERVATIONS

Lesion Description: General Guidelines

All descriptions should at least include the following listed information. Lesions should be described *after* examining the cut surfaces. The following lesion descriptions should be *non-interpretive;* description should be thought of as if conveyed to a blind person (the histologist is often blind to the gross exam).

- Lesion type (ex: laceration, mass, ulcer, effusion, etc.)
- Organ affected and the lesion's potential communication with adjacent structures
- Precise location within the organ (e.g., serosa or parenchyma; superficial, deep, or full-thickness; cranial, caudal, or middle; dorsal, ventral, or lateral; left or right)
- Distribution within the organ (e.g., focal, multifocal, diffuse to coalescing, diffuse)
- Approximate total percentage of entire organ affected (<5%, 10%, 25%, 50%, 75%, 99%)
- Amount (mL) or size range (three dimensions, in cm; or maximum diameter) of lesion
- Modifiers: color, heterogeneous or homogenous, texture, consistency, viscosity, firmness, etc.

For a mass, include the following:

- Encapsulated or unencapsulated
- Whether it deforms or infiltrates adjacent tissue
- Whether central necrosis is present
- The location of the largest mass

For description of a fracture, include the following:

- Bone affected
- Open or closed to body surface
- Communicates with another structure
- Type of fracture (simple transverse or oblique; spiral; comminuted; greenstick, etc.)
- Whether fractured ends are aligned or displaced
- Whether fracture margins are sharp or smooth and have callus formation
- Presence of foreign material, purulent material, or osseous sequestrum
- Presence of blood, edema, fibrosis, purulent material in surrounding soft tissue or structure with which it communicates.

All of this information helps determine the type of trauma sustained, whether the fracture contributed to morbidity or mortality, possible sequelae, the potential for healing, and whether the fracture occurred antemortem.

Tissue Sampling for Histology

When a lesion is present, collect a sample of the lesion (including the leading edge), AND take another sample that does not appear to have the lesion. Should the lesion have more than one appearance, take a sample from each visibly different region.

When possible, samples taken for ancillary diagnostic tests—such as microbiology—should be taken adjacent to that section submitted for histology.

NOTE: *It is important to collect as much information as possible about the carcass and its collection. For example, a bycaught animal hauled up from depth may show signs of intravascular and interstitial bubbles—yet these would be an artifact of the recovery. Information gathered before the animal is examined is essentially case history and could be the most important part of determining circumstance of death.*

INITIAL OBSERVATIONS OF THE CARCASS

If possible, the carcass should be positioned right laterally recumbent (with its left aspect up); however, each surface of the carcass should be examined, described, and photographed prior to the internal exam.

External Lesions and Non-acoustic Human Interaction Data Sheet (Appendix 2-A)

Wounds are relatively recent lesions that may have some significance in determining cause of death or in documenting events that occur between stranding and necropsy. On the wound and scar data sheet, sketch and label each substantial wound with a unique number. If there are multiple wounds from a single event (e.g., a series of similar lesions), label each lesion in the wound series sequentially (histology and frozen samples should be matched as well).

Scars are superficial skin lesions that are healed or show significant resolution and have recovered sufficiently to be unlikely as the proximate causes of death. In some cases, where a chronic condition has been established by the event that caused the scar, cause of death may be linked to that event. Healing scars may have either rough or granular margins and a red, white, or yellow color. Repigmentation of a white scar begins at the wound margins and proceeds toward the center of the lesion. Most healed scars are completely covered with darkly pigmented epidermis and blend with the other epidermis so well that only the texture of the scar can be used to distinguish it from the adjacent undamaged epidermis. If there are multiple scars from a single event (e.g., a series of similar lesions), label each lesion in the scar series sequentially.

Procedure: On the wound and scar data sheet, make a sketch of the major scar patterns. Note whether each lesion is a wound or a scar. Indicate the depth of the lesion (i.e., to epidermis, dermis, blubber, or muscle or communicates with body cavity). If prominent scars extend down the sides or are found on the ventrum, sketch them on an appropriate projection. If there are signs of human interaction (HI), follow specific procedures to document these lesions.

External Photographs

A reference scale, clearly indicating a standard length (e.g., 15 cm for large regions and 1.5 cm for close-ups), should be included in all photographs. Place the scale so that it is in the plane of the photograph. If possible, photograph each image perpendicular to the plane of the scale, this is tedious but it makes interpretation of the photographs much easier. A fresh, 15 cm–long paper scale can be printed for each necropsy (laminated scales reflect too much light). The paper scale should be printed with a laser printer or photocopied (check for copier distortion) so that the ink is fused with the paper —inkjet printer products will run when wet. Using a waterproof marker, the field ID and the date of necropsy should be written boldly and legibly on the scale. If necessary, wet the paper to stick it to the sides of the carcass when taking lateral photographs. Appendix 2-B has an example of scales used at the Marine Mammal Pathobiology Lab.

Be sure that a unique carcass identifier (field ID) is in each photograph or that the first picture of a sequence on a roll of film is uniquely identified to avoid identification errors when more than one carcass is being processed at the same time. Take high-resolution electronic (preferred, or 35 mm) whole-body photographs of the carcass. Lateral (right and left) and ventral full-body photos and close-ups of specific lesions are recommended. The whole-body photos should be taken with the photographer as perpendicular as possible to the long axis of the carcass (and of the scale) so that measurements can be made from the photos. Photographs should be taken of all scars and wounds. If the scars are poorly visible, they can be highlighted with a grease pencil (or lipstick) and photographed (two sets of photos: highlighted and not highlighted). Close-ups are hard to ID by themselves, so take a wider-view photograph for perspective first, then take the close-up(s).

Measurements on Intact Carcasses—Morphometrics and Weight (Necropsy Morphometrics Data Sheet Appendix 2-C)

If a hoist or front-end loader is available, the carcass can be lifted by straps and weighed. Alternatively, platform scales or highway scales can also be used to measure weight—make sure movable equipment and gasoline level are similar to reduce error in smaller carcasses.

Standard external measurements that characterize the carcass (e.g., species, sex, age, superficial lesions, and condition) must be recorded (Appendix 2-C). If the carcass is intact, measure total body length (TBL) from the tip of the rostrum (not the lower jaw) to the midline of the fluke. If there is decompositional or scavenger damage of the midline extremities, TBL should be estimated and noted. Partial measurements such as distance from the snout to the anus or umbilicus to tip of fluke may help compute TBL if the carcass has missing extremities. Also, the position at observation or recovery should be recorded (e.g., right lateral, left lateral). As observations are recorded, they should be checked off on the *Necropsy Morphometrics Data Sheet* (Appendix 2-C).

NECROPSY PROCEDURE—NECROPSY NARRATIVE

Each necropsy should be permanently recorded as a written narrative using a word processor (blank *Odontocete Necropsy Report* in Appendix 2-D). The necropsy report is designed to prompt the team to make specific observations of all organ systems. If the organ or tissue appears normal, record this on the sheet—no visible lesions (NVL). If an organ or tissue was not examined (N/E) note that in the report and explain why not. If the tissue or body part was missing, note it as not applicable (N/A) on the report and why. Fill in all fields on the data sheet with some type of notation. If possible, this recording process should take place during the necropsy, not afterwards when the tissues are no longer available to clarify conflicts and omissions. Noting the absence of lesions is often as important as noting the presence of lesions.

Often the sequence that occurs during a necropsy differs from that listed in the narrative, particularly when several experts are present and contributing to the procedure or when specific lesions require special attention and procedures. If there are multiple prosectors, a primary prosector and one recorder should be assigned. If there are multiple carcasses, it is helpful to keep the same prosectors grouped; this will expedite the procedure as the group becomes acquainted with each other's methodology.

The primary prosector is responsible for the external examination and initial inspection of internal organs. This person then makes decisions about culture and collection of

tissues for ancillary diagnostics. This person also assigns additional prosectors to particular tasks. Each prosector is responsible for conveying a detailed description to the recorder. The primary prosector should review the necropsy report to ensure that all information was collected and that information is not conflicting.

The person recording the narrative must pay attention at all times, *repeat all* measurements or numbers to ensure accuracy, and read back any comments that are unclear. The recorder *must* feel confident to stop the procedure at any time to clarify any point. At the end of the necropsy, the narrative should be read and edited by the prosector(s) to ensure that all statements are accurate. This final read also serves as a check to make sure all steps in the procedure have been completed.

The process for a necropsy is described in following text. The Odontocete Necropsy Report in Appendix 2-D follows the narrative and can be removed, copied, and filled out as part of a necropsy. Before beginning the narrative, label all of the pages of the necropsy data sheet with the field ID.

Carcass Condition

The details recorded for each part of the necropsy procedure depend on the decompositional state of the carcass. By necessity, the fresher the carcass, the more detailed the examination and the greater the amount of useful information that can be extracted from it. If more than one carcass has stranded, start with the freshest individual(s). Unfortunately, because of ambient temperatures and the laws of thermodynamics, many carcasses are badly decomposed and unsuitable for *reliable* histology. When deciding which tissue samples are to be collected from a carcass, decompositional state must be determined. Fortunately for forensic purposes, many features associated with traumatic death are preserved even in decomposed carcasses. If in doubt, collect as many samples as possible; later they can be discarded if unused but they cannot be collected after the carcass has been disposed. Additionally, some biochemical assays (i.e., ELISA test for HAB) can be completed reliably on even autolyzed tissues, but care must be taken to avoid cross-contamination.

The condition of an odontocete carcass cannot be evaluated solely by its outward appearance nor estimated by knowing the

time elapsed since death. The rate of decomposition is influenced more by internal temperature (resulting from proliferation of decomposing bacteria) in large or robust animals and by ambient temperature in small or lean animals. Larger, rotund carcasses retain heat more effectively than smaller, slender ones. Carcasses also have a tendency to decompose more rapidly during the summer months, if pregnant, or if diseased.

Rigor mortis is a temporary condition and thus can be a helpful indicator of the time of death. The onset of rigor is typically within 2–8 hours after death, varying with the animal's terminal condition (particularly if there is a systemic infection) and the ambient temperature and activity of the animal prior to death. The duration of the condition is also variable, but may range from 12 to 72 hours (longest under cool conditions). The presence of rigor mortis indicates a carcass in fresh or moderate condition. It is important to note that carcass rigidity can also be a result of bloating from decompositional gas, generally a sign that a carcass is not fresh (though some diseases may cause gas production in tissues even in live animals).

Cardinal signs of decomposition include a rigid or distended tongue, prolapsed penis, protruding eyes, and distension by gas, and/or sloughing of epidermis. Skin, blubber, and muscle can remain intact and may even indicate gross lesions long after death. The heart, lungs, lymph nodes (LNN, singular LN), spleen, and kidneys may maintain their integrity longer, whereas adrenal glands, brain, pancreas, liver, and mucosa of the digestive tract decompose more rapidly. Extent of scavenger damage is also an indicator of elapsed time since death.

Internal Photographs

If possible, photographically document all lesions observed during the necropsy. It is important to have a nonverbal record of all significant observations. Again, for perspective, take wider view photographs before close-ups. Whenever possible, also photograph structure, organ, or lesion after removing and placing it on a white background (often improves color in photos); also photograph cut sections. Using a color strip can also help with standardization of color perception and description. When documenting anthropogenic lesions (HI), Polaroid photo-graphs should be added to the electronic and/or film record; the Polaroid pictures help the reviewer when

editing necropsy reports. Permanent markers can write on Polaroid pictures; this provides an additional medium on which to record observations or comments.

NECROPSY PROCEDURE—NECROPSY NARRATIVE HISTORY

The history of the individual animal may be important in interpreting the results of the necropsy. Record the history of the animal since its rescue or the interval between carcass recovery and necropsy. Be sure to be clear and concise (brevity is better than loquacity, but include all important events) in recording the events leading up to the necropsy; this includes carcass position in the water and attempts to rescue, carcass orientation during transportation and refrigeration, and, in the case of mass strandings, the temporal and spatial occurrence of each carcass and of human activities (e.g., military operations, seismic testing). Environmental conditions and the presence of other sick or dead animals is important to note. Include information about trauma and any rope or line added to the carcass during postmortem manipulation.

Sample Narratives:

e.g., 30 January 2004, at 0900 hrs, MMPL-KAA received a call from fishing Captain Kenny Hyatt who was on the water near the Skyway Bridge fishing pier, Tampa Bay, Hillsborough County. Captain Hyatt informed KAA that he was observing a dead dolphin wrapped in a cast net that was secured to the pier's piling. KAA called FWC SW Dispatch–Lakeland and requested an officer to investigate and tow the carcass to the nearest boat ramp. At 0925 hrs, FWC officer Cacciurri called KAA and informed him that he was en route to recover the dolphin carcass. Meanwhile, MMPL-TDP drove to the fishing pier to photograph the carcass and the recovery. The carcass was towed to the Maximo Park boat ramp in Pinellas County. TDP arrived at the boat ramp, loaded the carcass, and transported it to MMPL where it was stored in the cold room.

e.g., The carcass was part of a mass stranding in the Florida Panhandle; details of the mass stranding are found in a summary report. Fresh when collected and had to wait several days because of carcass transfer and manatee backlog. On 12 March 2004, the carcass was in cold room for approximately 5 hours, then transferred to outside frig. It was in frig at 1.1° C for approximately 3.5 days.

A. External (wound/scar description—epibiota, lesions (bruising, tooth rakes, cookie-cutter shark bites, HI, etc.)—distention from decompositional gas—condition of the epidermis [sloughing, sloughed, shedding, intact], emaciation [peanut head, rib outlines, body folds]). Describe the external appearance of the carcass; include verbal and quantitative descriptions of wounds and scars. If human interaction (HI) is suspected (e.g., military or seismic surveys nearby) or observed (e.g., entanglement in fishing gear), an HI report should be completed (2-A). Be sure to note on which side the carcass has been lying, because it may be very important during interpretation of organ color and fluid distribution within the carcass. Describe the condition of the skin: amount of epidermis present, shedding of superficial layers of epidermis (a natural process involving loss of the superficial layers of epidermis) and/or sloughing (epidermal loss due to decomposition), and peeling due to exposure. Note the presence and types (species) of barnacles or other epibiota, and record the dimensions of the largest individual of each type of epibiota. Describe fitness and/or emaciation and general appearance. Collect samples if appropriate. Examine the body openings and describe any lesions or foreign materials (e.g., fishing gear) that are present.

> ***Sample Narratives:***
>
> *e.g., Stalked barnacles* (Xenobalanus sp.) *mostly on the dorsal aspect and on the caudal margins of the flukes. No evidence of human interaction. Scavengers removed both eyes, and there was significant but superficial scavenging over the entire carcass.*
>
> *e.g., On the right side of the body, there were five scars. There were two linear scars on the left side of the body. There were patches of eroded epidermis on the dorsal fin, right shoulder, head, axillae, and flippers. There was a partial amputation of the left flipper (approximately 10 cm was missing). The carcass was found wrapped in a cast net; however, close inspection of net marks indicates that they were caused after death (this was verified in person by Bill McLellan of University of North Carolina, Wilmington). Numerous teeth were missing, especially in the upper arcade. Those teeth present were worn. There were numerous conspecific tooth rakes on the peduncle, flukes, dorsal fin, and flippers.*

Initial incisions (Figure 2.1). Take care that the first few cuts are not too deep, particularly if the carcass is distended with gas, because viscera and their contents may be extruded explosively from the carcass. With the carcass right laterally recumbent (if

possible), make cuts through the blubber and superficial muscles as illustrated in Figure 2.1. Make cuts parallel to the long axis of the body along the dorsal and ventral midlines and perpendicular to the long axis at nuchal and umbilical regions (or caudal insertion of dorsal fin).

Keep any HI evidence (e.g., fishing gear, lines, bullets) in appropriate containers; if it appears that the event might be a criminal case, notify law enforcement and make every effort to maintain chain of custody and events.

Use cuts around the base of each flipper to remove it. Examine flipper joints for lesions. If the carcass is fresh enough to have intact and representative fat stores (i.e., no fats have been lost from decomposition or rendering), blubber and skin thickness measurements should be taken at mid-dorsal (slightly off-midline if there is a dorsal ridge), mid-lateral, and mid-ventral—all taken at the level of the umbilicus—and the measurements recorded on the blubber-thickness data sheet (Appendix 2-E). Examine and measure nuchal fat thickness. Be sure that the skin and blubber, when measured, are not stretched from bloating; this can be accomplished by making two parallel circumferential cuts about 3–5 cm apart to relieve the stress; measurements are made on the undistorted section. Make these circumferential transverse cuts at the level of the umbilicus to measure blubber thickness (with epidermis, note thickness of epidermis). Make transverse flensing cuts (the spacing of which is determined by the size of the pieces that are most easily handled). Check each cut surface of the blubber for parasite tracks or encysted parasites (e.g., *Crassicauda* or *Phyllobothrium,* respectively).

If the carcass is an adult female, care must be taken to delineate and measure the entire extent of the mammaries, which are located below the blubber and the superficial-most muscle fibers, just cranial and dorsal to the mammary slits at the lateral margins of the urogenital (U/G) opening.

If only a single sample is to be acquired, collect a sample of blubber at the level of the umbilicus, on the dorsal or dorso-lateral aspect of the carcass. Blubber varies at different depths and at different sites on the body; thus, if possible, multiple blubber samples should be collected; the blubber collection data sheet (Appendix 2-E) is a guide to this multi-site collection. Once the blubber is removed from the dorsal body, epaxial muscle samples can be collected (collect histology and archive

samples from the epaxial muscles near the site of the single blubber sample).

If care is taken when removing the blubber and abdominal wall muscles, the peritoneum can be left intact. This is accomplished by removing the blubber and superficial muscles of the thorax first. At the caudal margin of the ribs, slide a finger between the abdominal wall muscles and the peritoneum to separate them before proceeding with the cuts through the blubber and muscle of the abdominal wall. The hypaxial muscles dominate the caudal abdomen; examine their surfaces carefully for vascular lesions before continuing. Look for evidence of emboli and describe (include photographs) if present; the procedure for quantifying emboli is in the developmental stage. Care must be taken while making a cut on the dorsal aspect of the abdominal peritoneum (if the peritoneum was kept intact when the abdominal wall muscles were removed). Maintaining as much sterility as possible, examine the serosal surfaces of the viscera and any ascites. Abnormal (flocculent or fibrous) ascites should be sampled either with a sterile (aerobic and anaerobic) bacterial swab (from peritoneum and ascites)—see below.

Tissues to be collected. Collect samples of epibiota (in 70% ETOH) if appropriate, superficial lesions (in 10% NBF), and skin biopsies for genetics (include epidermis and dermis and store in DMSO). Collect superficial lesions such as bruises, scrapes, scars, and shark bites. Blubber and muscle samples for archive; mammaries if female.

The intestines and gonads may be exposed at this point. Before cutting anything new, examine the serosal surfaces of all organs visible at this time and describe the occurrence of any lesions (e.g., blood clots, fibrin, adhesions, lacerations, parasites, gassiness). The stomachs and liver may also be visible at this time. The condition of the liver (firmness, sharpness of margins, resistance to tearing by fingers, separation of serosa from parenchyma) is often a good indicator of the stage of decomposition of the carcass as a whole. The stomachs are typically empty in single strandings but may have contents in mass stranded individuals or anthropogenic vents.

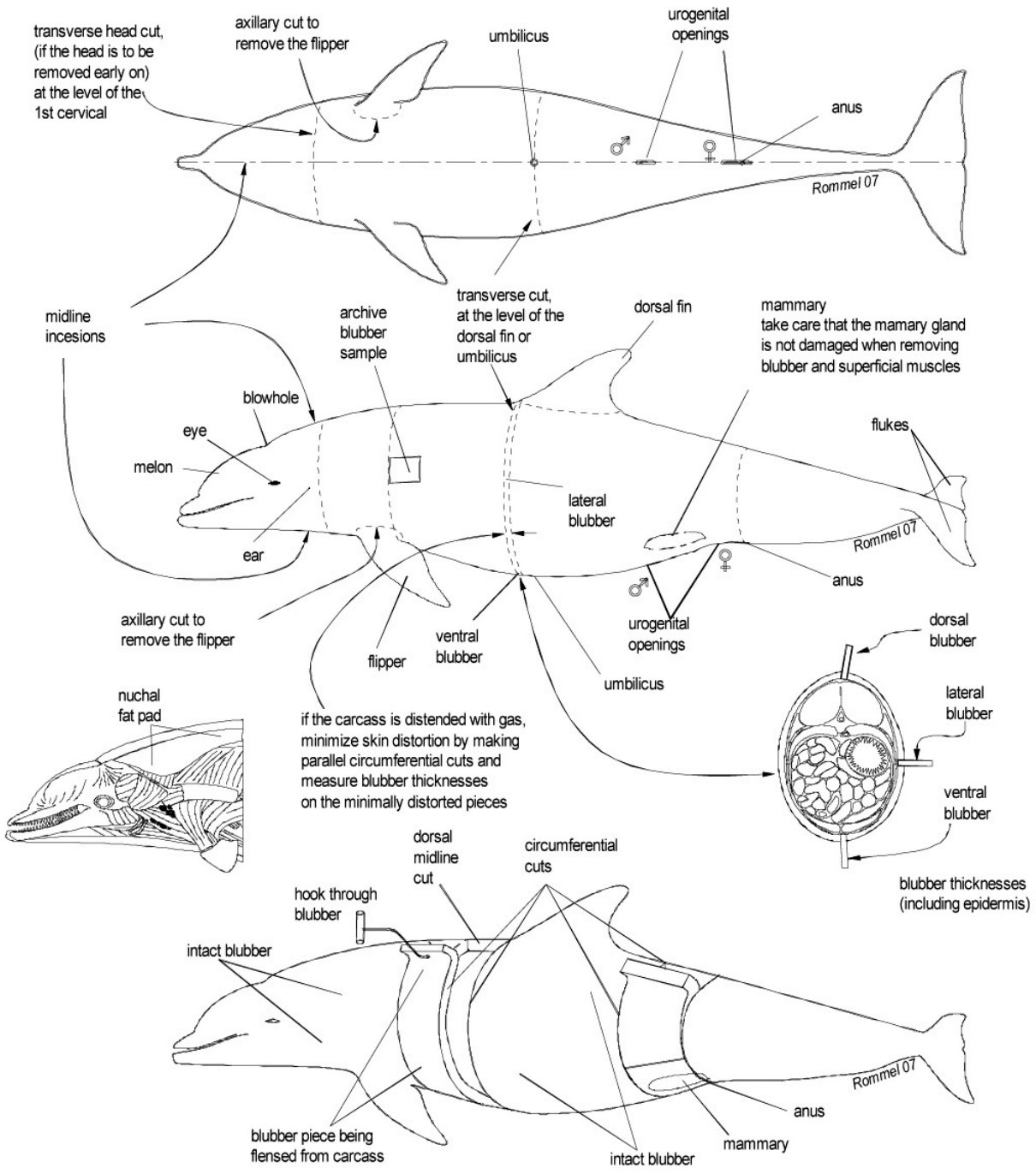

Figure 2.1 Illustration of flensing procedure; compare with Appendix 2-E.

B. Abdominal Organs and GI Tract—This section is primarily a description of the abdominal cavity, gastrointestinal (GI) tract, abdominal vascular plexuses, and the parietal peritoneum. Some or all of the ribs can be removed now or later. The left ribs can be separated at the joints between the vertebral and sternal ribs (sternal ribs are cartilaginous in beaked

whales); the sternal ribs can be left with the sternum or removed, depending on the specimen. Vertebral ribs can be disarticulated at the costo-vertebral joints starting at the caudal end. The cranial-most ribs are double headed, and these joints and the adjacent retia may be sites of sound-related lesions. Be sure to carefully examine the thoracic rete when the pleural cavity is open before the cranial ribs are removed. Examine the margins of the epidural retia at this time; when the vertebrae are separated examine retia and epridura veins at each of the sections

1. Abdominal Cavity (fluid description (i.e., color, texture, volume[1])—foreign objects (i.e., blood clots, GI tract contents) —adhesions, mesenteric and perinodal fats)

Incise the abdominal wall musculature along the caudal margin of the ribs and dorsal limit of the abdominal cavity (just ventral to the transverse processes of the lumbar vertebrae) and reflect downwards; avoid puncturing the intestines. Examine the organs in place, noting color, consistency, orientation, and any abnormalities. Normally, the abdominal cavity contains a small amount of clear serous fluid (ascites). If copious amounts of fluid are present, or the fluid has a flocculent and colored appearance, collect and freeze a sample for protein and lymphocyte analysis. If able to expose the cavity in a sterile manner, collect a swab of the surface of the peritoneum (especially where reddened or roughened) for microbiology (the fluid is less optimal for culture, because of the etiologic agent is diluted and dead). The peritoneum should be smooth and glistening, without irregularities. In fresh carcasses, the colors of the serosal surfaces of the intestines and parietal peritoneum should be light tan to pink. Note the root of the mesenteries; examine its vessels for signs of emboli and collect photos if any are present.

Sample narratives:

e.g., The abdominal cavity contains approximately 0.5 liters of clear fluid. NGVL.

e.g., There are small well-formed blood clots free within the abdominal cavity.

---

1 To simplify estimates of volume and length, you can measure the sizes of parts of your hand and arm. By submerging each part of your hand in water and observing the displacement of fluid the approximate volume of that part can be calibrated. For example, a finger on a large hand may be ~10 ml and a fist ~250 ml; in larger individuals, the distance between finger tips when both arms are extended is ~ 2m. This can be helpful in field or rushed conditions; whenever possible, however, actual measurements should be made.

Take care when cutting the parietal peritoneum, particularly if the animal is young and the gonads are small. The gonads are supported by mesenteries that are coincident with the peritoneum. Prior to removing any mesenteries or peritoneum, carefully examine them and the blood vessels of the root of the mesentery for signs of emboli (Figure 2.2) before making any additional cuts. Note if there is milky fluid in the lymph channels of the mesenteries or if the lymph channels appear unusually conspicuous.

Remove the GI tract (Figure 2.3), starting with the intestines, by cutting their mesenteries at the root; trim them a few centimeters from the intestines. Tie off the ends of the GI tract (at the esophagus a few centimeters in front of the stomach and at the rectum) with string. Remove and examine. When collecting thin-walled GI tract histology layers of the full-thickness, collect one or two sections from *each* compartment. Do not rub or scrape the mucosa to clean it. Rinse the sample with gently flowing water. Record your observations on the Odontocete Necropsy Report (Appendix 2-D) and the Abdominal Cavity Data Sheet (Appendix 2-F).

Figure 2.2 Gas bubbles in mesenteric veins. Paul Jepson

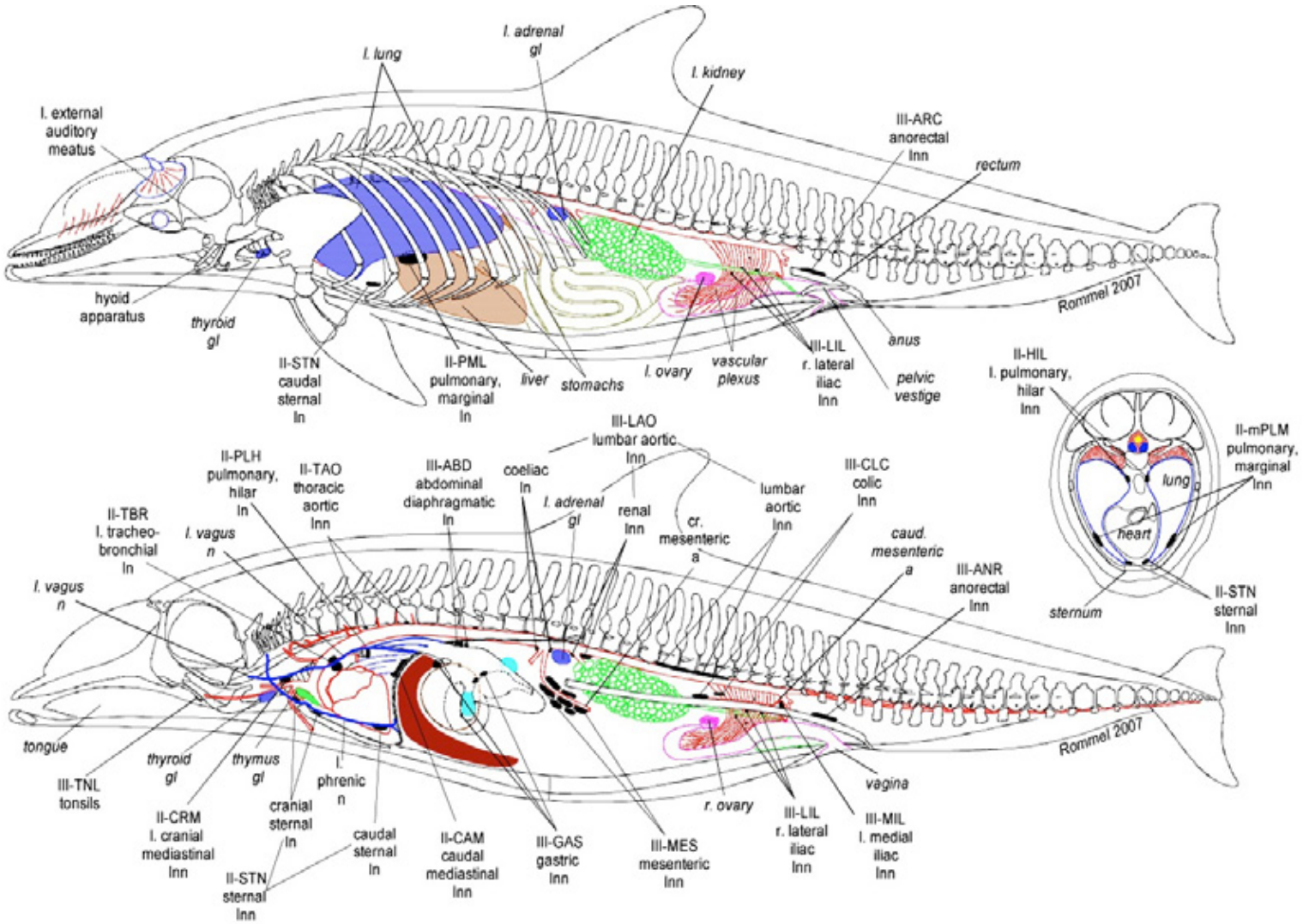

Figure 2.3 Reference drawings for lymph node identification and relative positions of thoracic and abdominal organs of *Tursiops truncates* (modified from Rommel *et al.* 2002)

2. Stomachs—Contents description (i.e., color, moisture, texture, lenses, beaks, otoliths)—mucosa description (i.e., smooth, rugose, sloughing)—parasites (i.e., type, degree of infestation, live or dead)

Normally, the stomachs are empty in most single strandings (there are cases where healthy cetaceans that have died of trauma, bycatch, etc., have stomachs full of recently ingested prey); however, in mass strandings, stomachs may contain fresh or partially digested food or remnants such as lenses, beaks, and bones. The mucosa of the first and third stomachs should be tan in color and smooth, but folded, in texture. The mucosa of the second stomach should be dark purple and smooth, but deeply folded and reticulate in texture.

Sample Narratives:

e.g., The stomach was significantly reduced in size (photos) and contained a small amount of ingesta. The stomachs were tied off and collected in entire for Nelio Barros, Mote Marine Lab. No Monorhygma and no Phyllobothrium were present. All of the abdominal organs were flaccid and slightly gassy (muscle and kidney bubbled in vacuum sealer), and the parietal peritoneum was slightly gassy.

e.g., The mucosae were unremarkable. No parasites were observed. The first stomach was full (~3 L) of moist, partially digested herring (the exact number could not be determined). Stomachs two and three were empty, and the mucosae were unremarkable.

Tissues to be collected: **Collect intact and freeze entire stomach series for examination by a specialist. Alternatively collect and freeze the contents (especially otoliths, squid beaks and lenses, spines, barbs) of each chamber. If the carcass is thought to be a HAB-suspect mortality, collect a small, finger-size or lemon-slice-sized stomach contents sample for ELISA (or RBA/LCMS). If the carcass is fresh, collect a full-thickness sample from each of the stomachs with caution to not tear mucosa from deeper layer.**

Open each of the stomach chambers; if possible, collect histology prior to examination and manipulation to avoid damage to the mucosa. For each separate chamber, examine the contents and make sure to note the decomposition, degree of digestion, texture, quantity, color, and moisture as well as the presence of any inorganic objects. Freeze contents for later evaluation; incise and drain the contents into a plastic bag or bucket (if the GI track is kept intact, freeze entire). Note any ulcerations (including depth and diameter), foreign objects, or parasites, both free and embedded in the mucosa. Make a note of the quantity of any parasites present (also note if they are alive or dead), and remark on the appearance of the mucosa. In cases where a sample of the stomach wall is required, but the stomach must be saved for analysis, collect the sample and then use string to suture it. Collect a small, full-thickness sample of the stomach wall from each compartment. Take Polaroid and high-resolution electronic (preferred or 35 mm) photographs of any significant lesion.

3. Intestines

Note—the intestines of odontocetes do not have a cecum, and there are no grossly visible differences between the large and small intestines. Lay out the GI tract on the necropsy table, and fold it in a manner similar to that in Figure 2.4. Subdivide the intestines into three (equal) parts or sections. Examine the serosa for nodules, perforations, segmented discolorations, or adhesions. Open and examine the intestines for hemorrhage, parasites, obstructions, and other abnormalities—describe and then collect histology samples from the center of each section. These samples can be collected before the entire intestine is examined or as that general region of the tract is reached during exam.

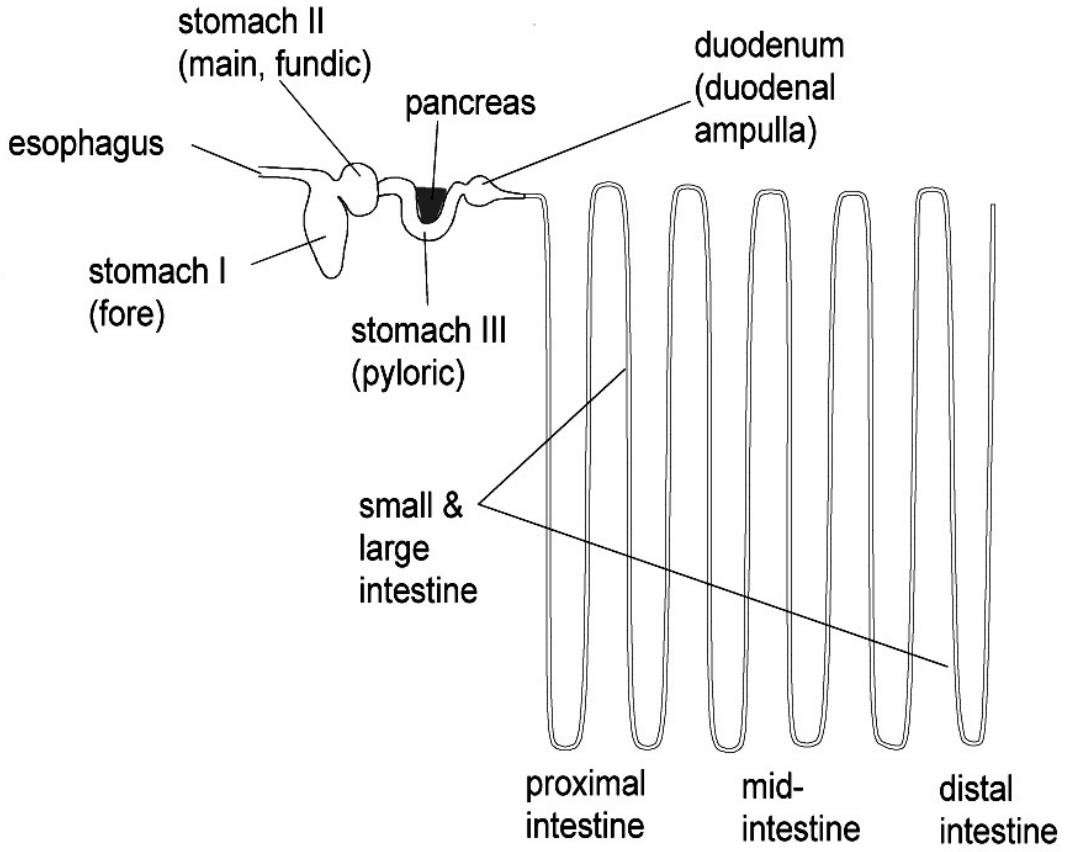

Figure 2.4 Arrangement of GI tract to differentiate and identify intestine sample sites

a. Duodenal Ampulla—contents description (i.e., color, moisture, texture, lenses, beaks, otoliths—mucosa description (i.e., ulcerated, smooth, rugose, sloughing)—parasites (i.e., type, degree of infestation, live/dead)

Tissues to be collected: **Full-thickness section of the duodenal ampulla and contents if present; caution with the mucosa.**

Normally, the duodenal ampulla is loosely filled with mucus or with bile-stained, watery ingesta and mucus. Cut open the duodenal ampulla and examine its contents. Be sure to note the quantity, color, wetness, and viscosity of the contents. Note the presence of and quantify parasites or other lesions, and remark on the appearance of the mucosa. Take Polaroid and high-resolution electronic (preferred or 35 mm) photographs of any significant lesions.

Sample Narratives:
e.g., The duodenal ampulla contained a very small amount of wet, mottled light-tan digesta. The mucosa was unremarkable. No parasites were observed.
e.g., The duodenal ampulla contained a minimum of 5 otoliths. The mucosa was unremarkable.

b. Proximal Intestine (~small intestine)—contents description (i.e., color, moisture, texture, lenses, beaks, otoliths)—mucosa description (i.e., smooth, rugose, sloughing)—parasites (i.e., type, degree of infestation, live or dead)—enteritis

Normally, this section of the intestine should be mostly empty and should contain small amounts of digesta coated with bile-stained mucus. There should be little or no intestinal gas in fresh specimens. Use ball shears to slit open the proximal intestine and examine its entire length. Note the quantity, color, moisture, and overall appearance of the contents. Note the presence and quantity of parasites or other lesions, and describe the appearance of the mucosal lining.

Tissues to be collected: **If the carcass is fresh, collect full-thickness rings (~2 cm wide) of intestine from the middle region of the proximal intestine for histology. Additional samples can be collected from specific lesions of interest.**

Take Polaroid and high-resolution electronic (preferred) or 35 mm photographs of any significant lesion. Remove and examine the mesenteric lymph nodes and sample for histology and virology (see **section F** in subsequent text).

Sample Narratives:
e.g., There were numerous stenoses along the length of the entire intestine. The proximal intestine contained watery, yellow fluid. The mid intestine was empty. The distal intestine contained watery, yellow fluid and wet, dark-green material. No parasites were observed.
e.g., The small intestine contained wet, mottled light- and dark-green material. The mucosa was roughened and rugose, with multifocal hemorrhagic lesions (enteritis). No parasites were observed.

c. Mid-Intestine (~large intestine)—contents description (i.e., color, moisture, texture)—mucosa description (i.e., smooth, rugose, sloughing)—parasites (i.e., type, degree of infestation, live or dead)

Tissues to be collected:
If the carcass is fresh, collect full-thickness rings (~2 cm wide) of intestine from the middle region of the mid-intestine. Additional samples can be collected from specific lesions of interest.

Normally, this section of the intestine should be mostly empty and should contain small amounts of material coated with bile-stained mucus. There should be little or no intestinal gas. The mucosa is typically light tan in color and smooth (with longitudinal folds) in appearance. Use ball shears to slit open the mid-intestine and examine its entire length. Note the quantity, color, moisture, and overall appearance of the contents. Note the presence and quantity of parasites or other lesions, and describe the appearance of the mucosal lining. Take Polaroid and high-resolution electronic (preferred or 35 mm) photographs of any significant lesion.

Sample narratives:

e.g., The mid-intestine was empty of contents; there was a small amount of watery mucus. The mucosa was sloughing. No parasites were observed.

e.g., NVL

d. Distal Intestine (Rectum)—contents description (i.e., color, moisture, texture)—mucosa description (i.e., smooth, rugose, sloughing), parasites (i.e., type, degree of infestation, live or dead)

Tissues to be collected: If the carcass is fresh, collect full-thickness rings (~2 cm wide) of intestine from the middle region of the distal intestine. Additional samples can be collected from specific lesions of interest.

Normally, this section of the intestine should be mostly empty and should contain small amounts of ingesta coated with bile-stained mucus. There should be little or no intestinal gas. Typically, the mucosa is light tan in color and smooth (with longitudinal folds) in appearance. Use ball shears to slit the distal intestine and examine its entire length. Comment on the quantity, color, and moisture of the digesta. Note and quantify the presence of parasites and other lesions, and examine the mucosal lining. Take Polaroid and high-resolution electronic (preferred or 35 mm) photographs of any significant lesions.

4. Pancreas—serosal surface description (i.e., color)—texture (fibrosis, extent of decomposition)

Tissues to be collected:
If the carcass is fresh, collect a histology sample.

The pancreas is located in the lesser curvature of the U-shaped third stomach (in species such as *Tursiops* that have three stomachs) proximal to the duodenal ampulla. The pancreas and

spleen can be removed before or after removal of the GI tract. Take care when separating the pancreas from the adjacent organs, and note any indications of fibrosis or parasites in this region. Normally, the pancreas has a light pinkish-gray color; it is firm but lobulated. Its enzymes make it autolyze quickly.

Examine the serosal and cut surfaces of the pancreas, and note the color and texture of the pancreas and its connective fats and tissues. Note any significant lesions.

> *Sample narratives:*
> *e.g., The pancreas was soft, very gassy, and non fibrotic.*
> *e.g., The serosa of the pancreas was light pink. Its texture was firm.*

5. Spleen—serosal and cut surface description (i.e., color, texture)—lesions—number of accessory spleens

> *Tissues to be collected:* **If the carcass is fresh, collect a sample through the midsection of the spleen for histology, virology, and biotoxicology.**

The spleen is a subspheroid located on the right side of the first stomach. Normally the spleen has a slightly mottled, dark-plum and black color, on the serosal surface; and a firm, dark reddish-plum parenchyma. If accessory spleens are present in the region, note their number and sizes. Examine the serosal surface(s) of the spleen(s) and remark on color and texture. Measure and record the weight and largest linear dimensions of the spleen(s) if fresh. Slice through the spleen(s) in a bread-loaf fashion, and examine the cut surfaces. Note the color, texture, wetness, and bloodiness of the cut surfaces.

> *Sample narrative:*
> *e.g., The spleen was pale on serosal and cut surfaces.*
> *e.g., The spleen was dark-plum on serosal and cut surfaces and was enlarged.*

6. Liver—serosal and cut surface description (i.e., color, texture, margin roundness, bloody cut surfaces)—lesions

Prior to removing the liver, examine portal veins for evidence of gas bubbles. Normally the liver is a uniform or slightly mottled, shiny metallic blue on its serosal surfaces. The serosa should be uniformly and smoothly attached to the parenchyma. Some of the margins may be sharp. Roundness of the margins and separation of the serosa and mucosa from the parenchyma can reflect decompositional state of the liver and other organs, so be sure to record the integrity of these surfaces and the sharpness of the margins.

The parenchyma should be reddish-brown, firm, and moist. Bread-loaf the liver and examine the parenchyma on all cut surfaces. Record the color, texture, and bloodiness and wetness of the cut surfaces. Examine sinuses and hepatic portal and caval systems. There are large venous sinuses in the liver; palpate their margins and carefully look for evidence of gas bubble trauma (Figure 2.5).

Tissues to be collected: **If the carcass is fresh, collect four samples of liver for histology. These samples should be from right and left lobes at the cranial and caudal aspects of each (alternatively they could be collected proximal and distal to the portal circulation to reflect distribution of emboli). Collect a playing-card–sized sample for archive toxicology. If the carcass is from a harmful alagal bloom (HAB) region, a lemon-sized sample of liver should be collected each for ELISA and virology regardless of decompositional state.**

Sample narratives:
e.g., The liver was firm, with sharp margins. The serosal surfaces were metallic blue to plum, and cut surfaces were dark red-brown and bloody.
e.g., The serosal surfaces of the liver were dull metallic plum, and the cut surfaces were red-brown and wet. No sharp margins were observed.

Figure 2.5 Chronic gas bubble lesions in the liver (Delphinus delphis). Paul Jepson

7. Adrenal Glands

Tissues to be collected: **If the carcass is fresh, collect both adrenals for histology; bread-loaf if large, and store in 10% NBF.**

Examine the abdominal cavity, and locate the adrenal glands (at or near the dorsal attachment of the diaphragm cranial to the kidneys near the midline); remove, describe, and measure. Bread-loaf the adrenals, and examine the parenchyma on all cut surfaces. A central cross-section of each adrenal should be submitted for histology (a small amount from one adrenal can

be collected for virology, if appropriate). Before fixation, photograph the sections so that cortical and medullary areas can be measured. Trim fats from samples prior to weight and size measurements.

Sample narrative:
e.g., The adrenals were very firm. Periadrenal fats had serous atrophy but were abundant.

Tissues to be collected: **Separate the ovaries from the rest of the reproductive tract (uniquely label the right ovary before removal), and remove any excess connective tissue from the ovary surfaces before weighing and measuring. Collect both ovaries, bread-loaf if large, and store in 10% NBF (the ovaries may be stored separately from histology in 10% NBF for life-history evaluation). If the entire tract and/or placenta is collected, uniquely label or tie a string to the right uterine horn; attach labels to both the tract and the outside of the container. Collect genetics from fetus.**

C. Urogenital System

Reproductive—mature and/or immature—Females: multiparous, parous, or nulliparous, description of ovaries and follicles —Males: dimensions of testes, weight of testes and epididymides, seminal fluid presence, sperm presence

1. Female Reproductive Tract: Examine the serosal surfaces for any lesions. Take particular care with the nearby vascular plexuses for signs of emboli.

Uterine exam—Examine the broad ligaments for edema, parasites, extent of vascularization, opacity, and thickness. Remove the entire reproductive tract, and label one side before proceeding. Cut open the cervix and uterine horns. Examine the mucosa for evidence of placentation, regions of discoloration, or other lesions. Evaluate thickened uterine horns by measuring the dimensions of each uterine horn: length (from midline to distal tip) and outside diameter at mid-length; then examine each horn (Figure 2.6).

If the specimen is pregnant, the uterine horn in which the placenta is located is defined as the pregnant horn. Fetus gender, length, and external features (including presence of rostrum whiskers, teeth, meconium-staining of skin, fetal folds) should be recorded, and the fetus with placenta (including the amniotic sac and umbilical cord) should be preserved for additional workup. When available, collect and freeze a sample of the amniotic fluid for bioassay (seal and freeze). *See following perinatal section.*

Ovarian exam—Look for surface irregularities (e.g., corpora lutea of pregnancy and ovarian scars from past pregnancies). These qualities are used to determine reproductive maturity, history, and status.

Sample narrative:
e.g., The carcass was pregnant, and the fetus was in the left uterine horn. Left mammary dimensions: 32 × 10 × 3 cm. The male fetus's total length was 98 cm, and it did not have whiskers, teeth, or meconium-staining of the skin, but did have fetal folds.

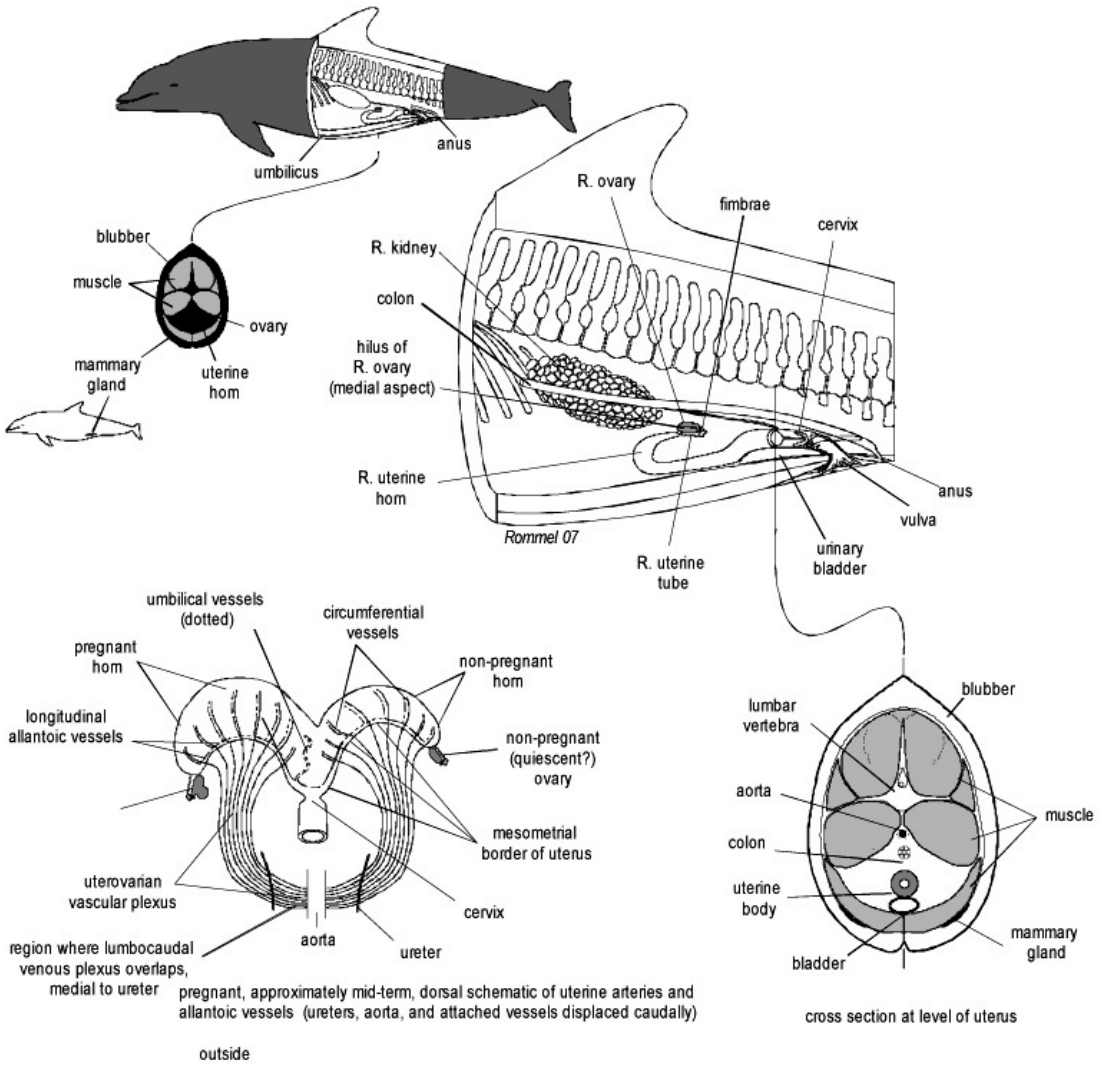

Figure 2.6 Female reproductive system and sampling sites—after Rommel *et al* (in press)

Tissues to be collected: **Collect a smear from one of the testes or epididymides (preferable) on a glass slide, and examine under a microscope (40×) for presence of sperm. If the carcass is fresh, collect a tissue sample from the head of the testes (because tendency for infection to develop first at this site), the middle of the testes for reproductive history (may be stored in 10% NBF separately from histology for life history), and from the proximal and the distal epididymides for histology.**

2. Male Reproductive System: Examine the serosal surfaces of the testes and epididymides for general appearance (color, size, shape, firmness, fullness, flaccidity) and lesions (Figure 2.7). Prior to cutting in this region, take particular care with the vascular plexuses associated with reproductive cooling to be sure there are no signs of emboli (a sample of the plexuses should be collected for histology). Cut the epididymides, and note the presence, color, and viscosity of any liquid present. Examine the cut surfaces for any lesions. Separate the testes from the rest of the reproductive tract, and remove any excess fat or connective tissue from the outside before weighing and measuring length, width, and thickness.

Sample Narrative:
e.g., Right testes had dimensions of 27.5 × 8 × 2.5 cm; left testes had dimension of 29 × 8.5 × 2 cm. The testes were flaccid and autolyzed. There was no grossly visible milky fluid.

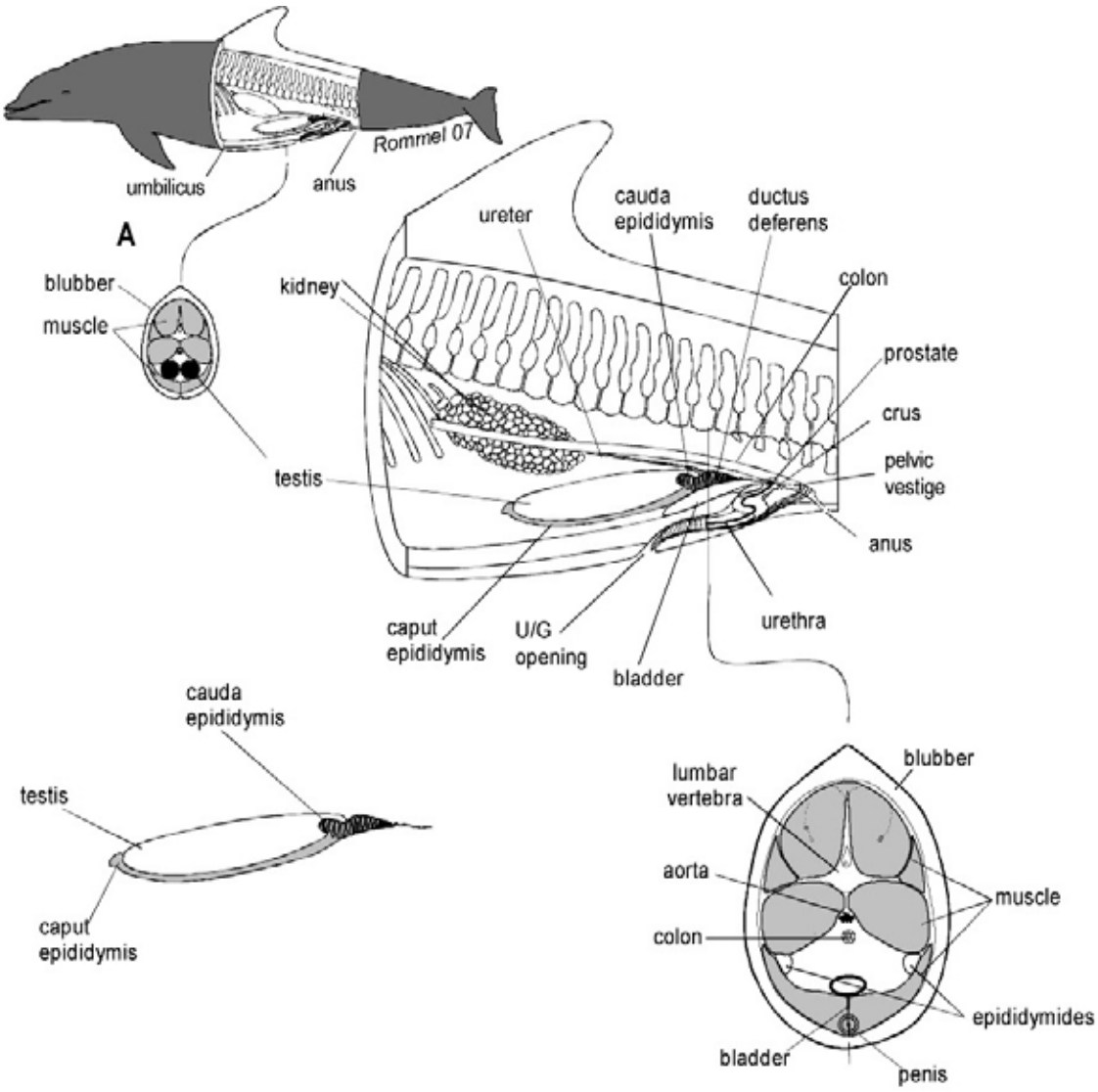

Figure 2.7 Male reproductive system—after Rommel *et al.* (in press).

Urinary bladder tissues to be collected: **If the carcass is fresh, collect a full-thickness sample of the bladder (preferably the apex where infection tends to start) for histology. If the carcass is from a HAB region then, if possible, use a syringe to collect 1-5 ml of urine for ELISA toxi-cology; to store, either tape the syringe or transfer fluid to a small seal-able container; if no urine is available, collect a finger-sized (~10 ml.) piece of kidney.**

3. Urinary Bladder—mucosa description (i.e., congested)—contracted or dilated—empty or full (i.e., volume, color, transparency)—lesions

Examine the mucosal and serosal surfaces for any lesions, and note whether or not the bladder is contracted. Make a small incision at the cranial apex of the bladder; note the total amount, color, consistency, and transparency of the urine, and collect a sample before draining the bladder. In beaked whales, examine the blood vessels and urinary ducts for nematodes or obstructions. Examine the ureters for patency, and note any lesions.

Sample narrative:
e.g., The urinary bladder contained approximately 15 cc of cream-colored fluid. The mucosa was unremarkable.

4. Kidneys—serosal or cut surface description (i.e., color, wetness and bloodiness, presence of fat—cortico-medullary boundary description (i.e., cortex and/or medulla color)—lesions (i.e., infarcts, gas bubbles)

Check the region surrounding the kidneys for lesions such as hemorrhage, infarcts, and emboli (Figure 2.8), and check the ureters for dilation to suggest presence of obstruction. The serosal surfaces of each reniculus are typically plum in color, although lividity may make some surfaces darker than others. On cut surfaces, the cortices typically are darker than the medullae, and there are distinct cortico-medullary boundaries, which are often delineated by a dark-red rim of congested blood vessels. Parasites are common in some species of odontocetes. Examine the intact kidneys, and then remove them (in the case of suspected ureteral obstruction, locate the cause for obstruction prior to removing the kidneys). Closely examine all the surfaces, and remark on the color, firmness, and texture; note the presence of any blood clots or other lesions. Measure the maximum dimensions and the weight of each kidney. Cut the kidneys longitudinally along one of the blood vessels or the ureter, and note the color and bloodiness of the cut surfaces. Record the color of the cortices and medullae and any lesions present. If the carcass is from a HAB area and no urine is found in the bladder, be sure to collect a kidney sample for ELISA.

Tissues to be collected: **If the carcass is fresh, collect a tissue sample for histology from each kidney and an addi-tional sample for archive toxi-cology. Note and collect parasites, if present. A sam-ple from a kid-ney lesion should extend from one cortex through the medulla and to the contra-lateral cortex.**

Sample narrative:
e.g., The kidneys were pale to dark-red on serosal surface, and, on cut surfaces, the cortices were diffusely pale with occasional dark-red foci and with multifocal loss of corticomedullary differentiation. The ureters were unremarkable. No parasites were observed.

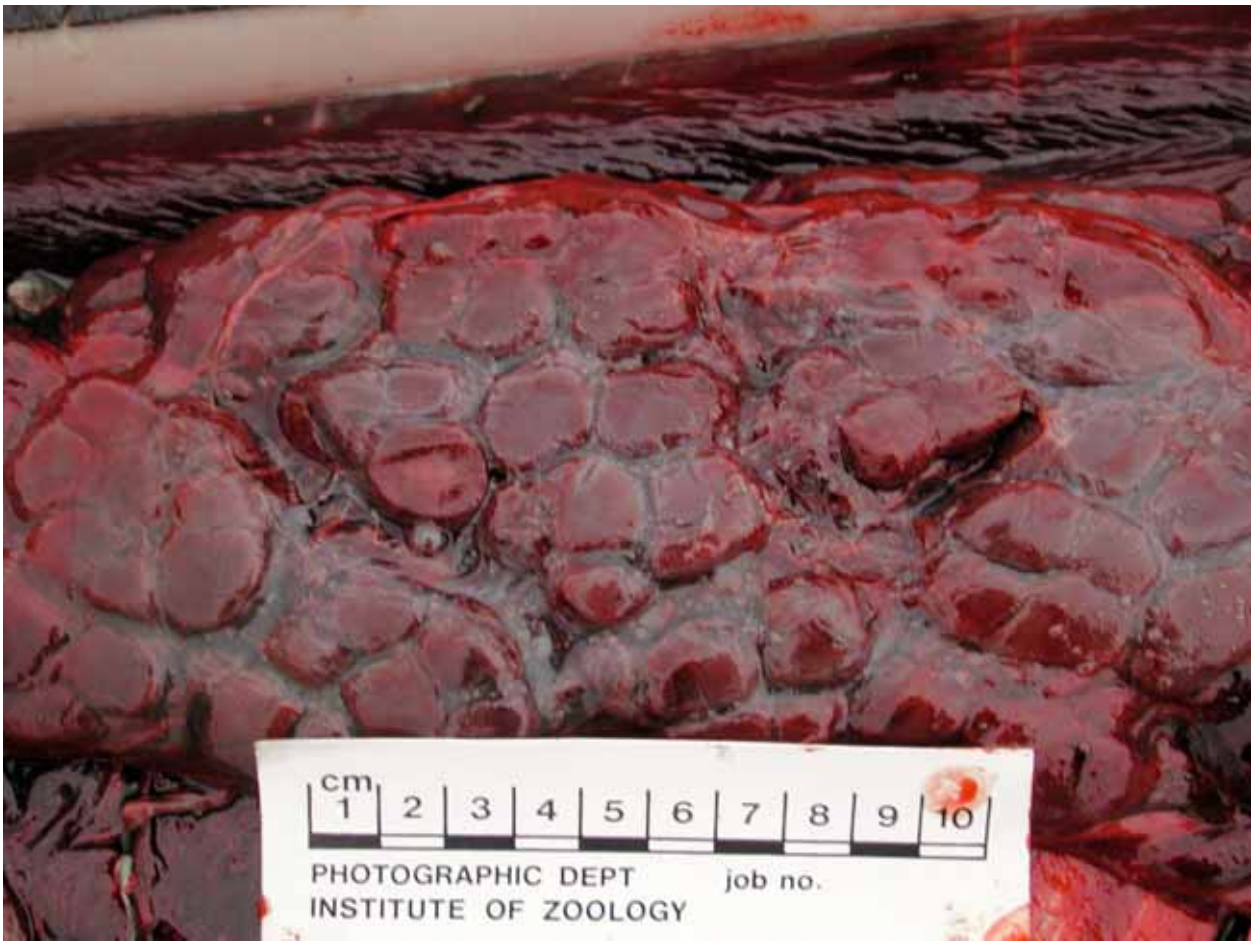

Figure 2.8 Perirenal gas emboli in *Mesoplodon bidens*. Paul Jepson

D. Thoracic Cavity

Prior to entering the pleural cavity, note the presence of tears or lesions on the diaphragm. Cut the muscular portion of the diaphragm along the ribs to expose the left lung. Note the presence, amount, color, and viscosity of any excess fluid in the pleural cavity, and note whether it is on one or both sides of the diaphragm. If able to expose the cavity in a sterile manner, collect a swab of the surface of the pleural surface (especially where it is reddened or roughened) for microbiology (the fluid is less optimal for culture, because the etiologic agent is diluted and/or dead).

E. Vascular System (see Figure 2.9 and Appendices 2-G and 2-H)

1. Heart—valves and chambers (i.e., check color, transparency, and texture of myocardium and valves), look for foci of pallor (again, necrosis is too interpretive and easily can be wrong).

Normally, the heart should be uniform in color, and the valves should be translucent and smooth in texture. Open the pericardial sac, and note the quantity and color of the pericardial fluid. Examine superficial cardiac blood vessels for presence of gas bubbles (emboli).

Tissues to be collected: **For histology, collect a sample of each atrium and ventricle and any areas with lesions. If the heart is to be weighed, be consistent; trim great vessels to margins of pericardium and remove**

Examine the proper position of the great vessels relative to the heart and for patency of the ductus arteriosus prior to removing the heart. Place the heart in your hand with the auricles facing you and note a) whether the left ventricular free wall does not curve slightly (i.e., shifting of the apex left); b) whether there is a double apex (i.e., thickening of the right ventricle) (be careful not to overinterpret should the right ventricle be filled with a large blood clot); and c) whether the left ventricle is flaccid and contains a large amount of blood (the animal should die in contraction of the left ventricle). Use a coronal approach to each valve to check for infection (enabling a sterile approach) or rupture of valves. Make a cross-sectional cut at the apex of the ventricles, and look for discoloration and/or banding or pallor in the myocardium. Cut the ventricular wall of both ventricles upward into the atria. Examine the papillary muscles and endocardium for any discoloration or scarring. Examine the interatrial septum for patency of the foramen ovale or other septal defects. Examine the atrioven-tricular (A/V) valves for signs of thickening, roughening, or other lesions. Cut into the aortic and pulmonary inlets, and examine the semilunar valves for signs of thickening, granulation, or other lesions.

Sample narrative:
e.g., Valves and chambers were unremarkable. On cut sections, there was banding on the myocardium of the left ventricle and interventricular septum, which was not noted in the right ventricle nor the atria.

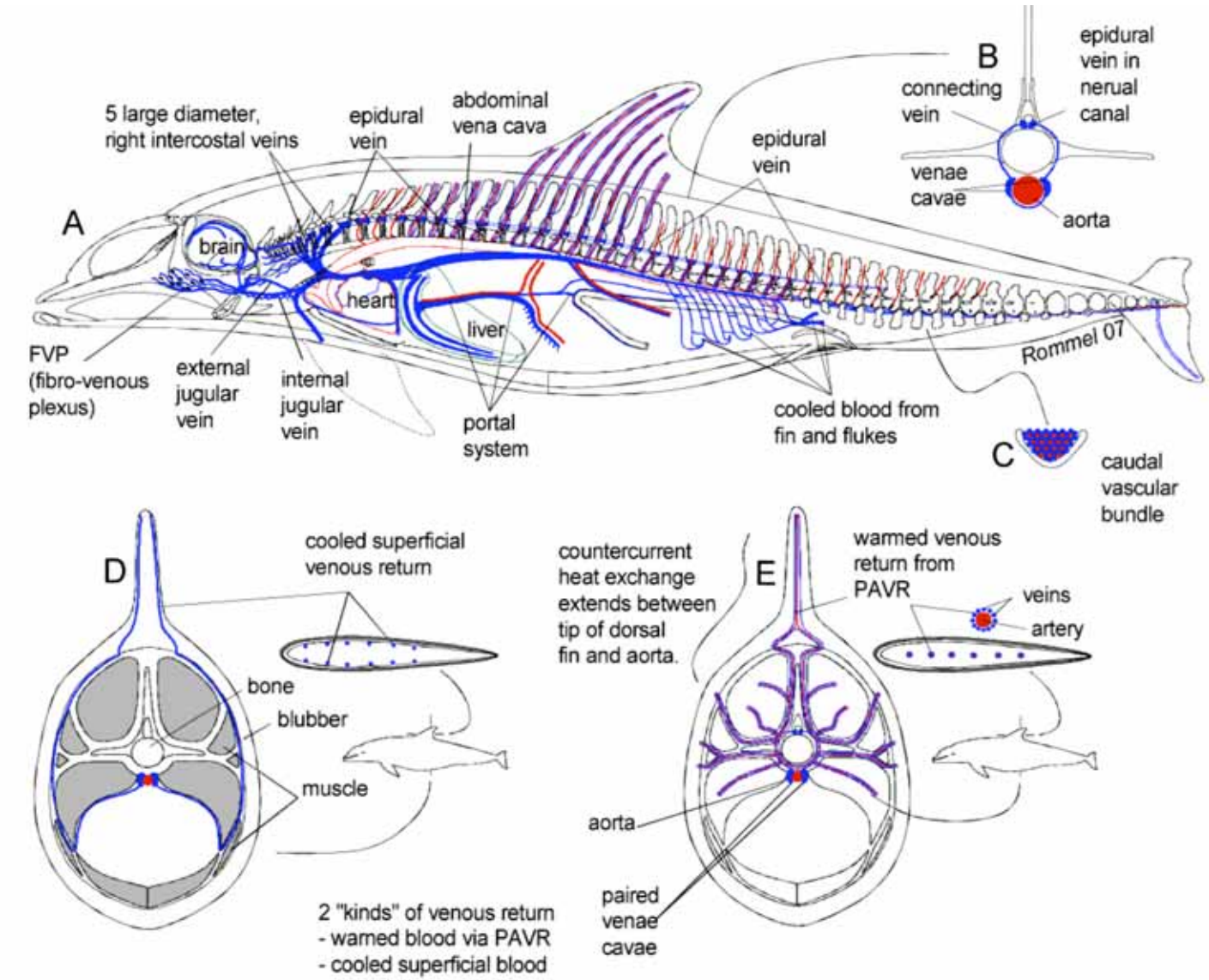

Figure. 2.9 Anatomical guide for the deep venous circulation—after Rommel *et al*. (2006).

Great vessels tissues to be collected: **For histology, collect sample of the thoracic rete from one pleural cavity and any areas with lesions. Remove two vertebrae (T2–3, if possible for double-headed rib attachment) with the proximal ribs attached; this will be sub-sampled after preservation for intervertebral and synovial joints, spinal cord, epidural, and thoracic retia.**

Perinatal indicators tissues to be collected: **For histology, collect sample of the umbilicus, the umbilical arteries at the level of the urinary bladder, umbilical vein at the level of the liver, urachus at or near the bladder tip, the ductus arteriosus with small pieces of the aorta and pulmonary trunk attached, and the foramen ovale. Sample any lesions or infections of the umbilical structures for histology.**

2. "Great" Vessels

Closely examine the serosal and luminal aspects of the aorta, vena cava, and pulmonary trunk. Look for adhesions and other lesions.

3. Perinatal Indicators

Dissect the heart, great vessels, and arterial supplies to the head and neck—for small animals, this should be done anyway to remove the thymus. In perinatal carcasses, record the presence or absence of external features (whiskers, neonatal folds, teeth, meconium staining of the skin, patency of umbilical vessels and urachus, and parts of the umbilical cord that remain attached to the perinatal carcass). Also record the patency of the umbilical arteries, umbilical vein, and the urachus (a neonate odontocete may have a patent urachus). Observe the ductus arteriosus and note if patent; record its flat (or round) diameter and the flat diameters of both pulmonary arteries (note if flat or round diameters). Examine the foramen ovale and note its overall closure, as a percentage, of the total area if multiple openings in the septum are observed. Ventricular wall thicknesses are valuable—because of the irregular internal surfaces, it is better to record the thicknesses of both walls (double-wall thickness) of each ventricle, measured with the heart intact. Be sure to examine the lungs and note whether they are consolidated. In very fresh specimens, a piece of lung can be placed in water or formalin. A floating lung is suggestive of previous inflation; however decompositional gasses in tissues that are not very fresh can cause the lung to float. When examining the lung, be sure to note the presence of lungworms in the airways, or lungworm cysts in the parenchyma (transplacental migration).

F. RESPIRATORY SYSTEM—diaphragm condition (i.e., tears, color, concavity, or cavity compromised lung serosal and/or cut surfaces (i.e., color, texture, wetness, airway contents or parasites)—lesions (i.e., lung adhesions, torn parietal pleura, abscess)

1. Diaphragm

Normally, the diaphragm is intact and—if the pleural cavity has not been compromised—tautly stretched between the midline and the lateral aspects of the abdomen, with a dorsal bulge

(concavity). When first cut, the diaphragm will spring ventrally as the negative pressure in the pleural cavities is released. There should be a scant amount of clear, watery serous fluid in the pleural cavities. The parietal pleura should be smooth, glistening, and light tan or pink.

2. Trachea and Airways

The mucosal surfaces of the major airways should be examined carefully, and their color, texture, and degree of congestion should be described. In fresh carcasses, the mucosae of the airways should be pale pink to pale red in color. The mucosal surfaces should be smooth and are often coated with a thin layer of mucus. Any coating or contents (e.g., froth, parasites, sediment) should be noted and quantified.

Sample narrative:
e.g., The tracheal mucosa is dark-red and moderately congested. There is a thick, heterogeneous coating of viscous, ropey mucus and silt-like sediment. On cut sections, the mucosa appear severely engorged.

Tissues to be collected: **If the carcass is from a HAB area, collect a finger-sized tissue sample from the cranial pole for ELISA. If the carcass is fresh, collect three tissue samples—one on the margin, one in the middle, and one along the main airways. Include a piece of bronchus in at least one of the lung sections.**

3. Lungs

The lungs should be spongy and well-inflated. The serosal surfaces of the lungs should be uniformly light in color and the pleura be clear and moist. Lung worms may occur, depending on species and feeding history; note parasites and tissue reactions to them. Look for lymph nodes and highlighted lymph channels on the surfaces of the lung. Examine the serosal surfaces of both lungs, and remark on the color, texture, and any lesions present.

Excise the primary and secondary airways with scissors, and remark on the presence, color, and viscosity of any material; also remark on any parasites or other lesions observed. Palpate the surfaces of the lung and note irregularities, then subsample any unexpected textures. Bread-loaf the entire lung, and examine the cut surfaces. Note the color, wetness, congestion, and any lesions observed. Photo-document any irregularities that are observed.

Sample narratives:
e.g., The lungs had scattered small focal nodules affecting approximately 25% of the total surface area. Both lungs were dark-red on serosal surfaces and dark-red to purple on cut surfaces. The airways are unremarkable.
e.g., The pleural cavity was distended with gas. The diaphragm was intact. There was a moderate trematode infestation in both lungs. The left lung was diffusely collapsed. There was a long laceration, approximately 2 cm, on the dorsal aspect of the left lung associated with a rib fracture. The laceration had a dark-red margin. The rib fracture was a closed, simple transverse fracture of the mid-diaphysis with displaced fragments that have sharp margins. Cut sections of the left lung sank in formalin. The right lung was diffusely dark-red, slightly wet, and heavy. There was an adhesion (approximately 2 × 3 cm) between the dorsal aspect of the mid-lobe and the parietal pleura (deep to a well-healed rib fracture). The primary and secondary airways contained a moderate amount of opaque, tan-to-red, slightly viscous fluid.

G. Lymphoid Tissues (Note: spleen was discussed previously, and tonsil will be discussed subsequently.)

1. Lymph Nodes (see Figure 2.3)

Tissues to be collected: **If the carcass is fresh, collect a sample of every major lymph node, especially lung- and GI-associated ones, for histology. If major lymph nodes are bilaterally paired, be sure to collect and label a lymph node from each side. Lymph nodes may also be frozen (preferably at –70° C) for immunological studies.**

Lymph nodes can be quite variable in appearance; however, a healthy, inactive lymph node should be pale yellowish-brown or off-white in color, should be located within a perinodal fat pad, and should be a solid structure without any cavities or hollow regions. The gross appearance of the perinodal fat can provide some clues regarding activation of the lymph node. The perinodal fat should not be gelatinous (i.e., serous atrophy), and the serosal surfaces of the lymph node should be smooth. Activated lymph nodes are typically dark-brown to black in color, but may have a heterogeneous (lumpy, nodular) external appearance; may appear wet, and the serosa may have irregularities; and the cortex may have regular, pinpoint white foci (nodular lymphoid hyperplasia). Prior to fixation, section lymph nodes, and describe cut surfaces. Describe the color, presence of serous fluid, and any structural irregularities (e.g., small pits on cut surfaces). Note that, in some species, some lymph nodes (i.e., axillary) are nearly impossible to find unless active and enlarged.

The narrative for this section should be dictated as one progresses through the carcass and each lymph node is encountered. Each lymph node should be described even though it may not be collected. Be sure to note the general appearance of the lymph nodes as well as any lesions or irregularities. Special attention should be given to the major lymph nodes draining important physiological systems (e.g., the

respiratory and digestive systems). Pulmonary and mesenteric lymph nodes are often noticeably irregular if there are respiratory or digestive complications, respectively.

a) Superficial and/or associated with extremity: Examine all superficial lymph nodes as the blubber is removed, prior to entering the abdominal cavity. Examine the axillary and superficial cervical lymph nodes while removing the axillae and scapulae. Examine the retropharyngeal and mandibular lymph nodes prior to decapitation.

b) Thoracic: Examine all pertinent thoracic lymph nodes after exposing the pleural cavities and during the lung examination.

c) Abdominal: Examine all pertinent abdominal lymph nodes after removing the gastrointestinal tract and during the abdominal organ examination.

Tissues to be collected: **Collect section of the thoracic duct at the level of the receptaculum chyli for histology. If fat emboli are suspected, be sure to collect a second cross-section to be fixed in special adipose-tissue fixative (i.e., `Pen-fix–http://www.rallansci.com/histology/histology.aspx?id=14`). Collect any irregularities or lesions observed.**

Other lymph channels tissues to be collected: **If the carcass is fresh, collect a sample of every major lymph node, especially lung- and GI-asso-ciated ones, for histology. If major lymph nodes are bilaterally paired, be sure to collect and label lymph nodes from both sides. Lymph nodes may also be frozen (preferably at –70° C) for immunological studies.**

Sample narratives:
e.g., The axillary, pulmonary marginal, and mesenteric lymph nodes were darkened and enlarged. The superficial lymph channels on the lateral aspect of the lung, joining at the pulmonary marginal lymph node, were very conspicuous. The mesenteric lymph nodes exuded serous fluid on cut sections.
e.g., The mesenteric lymph nodes were darkened and severely enlarged. The serosal surfaces of one mesenteric lymph node were nodular in texture, which on cut section was associated with regular, pinpoint, white foci in the cortex and exuded serous fluid when cut.

2. Thoracic Duct and Mesenteric Lymph Channels

The thoracic duct is located just dorsal to the dorsal aorta. External appearance of the thoracic duct is variable but may be important. Make a transverse cut at the distal thoracic duct, and check to see if it is significantly enlarged; open the duct cranially as far as possible. Also examine the receptaculum chili, the ampulla chyli, and the chyle cistern. Examine the lumen for signs of emboli.

Sample narrative:
e.g., The thoracic duct was unremarkable externally.

3. Other Lymph Channels

All applicable lymph channels should be examined. Most notably the lateral superficial lymph channels of the lungs should be examined and described.

Thymus tissue to be collected: **Collect a piece of thymus (near the aortic arch where least amount of involution seems to occur) for histology. A piece of thymus can also be frozen (preferably at –70˚C) for immunological studies and for virology.**

4. Thymus

In fresh carcasses, the thymus should be pale pink. The thymus involutes with age; therefore, in older animals, it can be significantly reduced in size and/or very fatty. The thymus should be examined for any irregularities. If possible, and if in good enough condition, be sure to dissect out the entire thymus and weigh it.

Sample narrative:
e.g., The thymus was pale-red on serosal and cut surfaces, but was otherwise unremarkable.
e.g., The thymus was dark-red on serosal surfaces, dark-red and wet on cut surfaces.

***H. Head and Neck*—**lesions (i.e., bruising, abscesses, edema, clots)—description of lesions present—periotic collected, tooth collected, nuchal fat collected.

The narrative for this section should be dictated as one progresses through the blubber and muscle toward the skull. Note the nuchal fat pad located on the dorsal midline just deep to the blubber.

Sample narratives: e.g., The fats in the head and neck were very edematous. The nasopharynx was almost occluded by thick, slightly viscous, ropey, pink-to-dark-red mucous. The proximal trachea was approximately one-third to one-half occluded by the same material. This material was not observed in the lungs. The nasopharyngeal mucosa was slightly congested. The meninges of the brain and spinal cord were moderately congested. The retropharyngeal lymph nodes were darkened and enlarged

Tissues to be collected: **Collect a piece of tongue and any oral lesions present for histology. Additionally, collect a cross-section of the larynx or goosebeak and sections of the oropharynx, thyroid glands, and tonsils. Collect teeth for ageing.**

1. Oral Cavity and Throat

The tongue, lips, gums, and oropharynx should be examined for orogential ulcerations. The goosebeak and larynx should be examined for signs of human interference (HI) (e.g., monofilament, fish hooks, ingestion of marine debris) and other lesions. The tonsils should be sampled. Teeth should be examined, and the extent of fractures and/or truncation should be described.

Examine the lips, then open the mouth and examine the tongue, gums, and roof of the mouth. Describe any irregularities and lesions. If the head is not being collected intact for research, remove the ventral throat blubber and examine the hyoid bones for irregularities before dissecting out the thyroid glands. Describe the color and consistency of the thyroid glands, and note any fluid-filled follicles or thyroid cysts. Take a cross-

section of each thyroid gland for histology. Remove the dorsal blubber caudal to the blowhole, and examine and collect the external auditory meatus inn.

Sample narrative: *e.g., There were small (~0.5 cm), focal, bilateral ulcerations visible along the gum line. There were large (1.5–2.5 cm diameter), diffuse and coalescing, nodular proliferations on rostral half of the lip of the right mandible. Most of the teeth were severely truncated from wear; five teeth had oblique fractures.*

2. Sinuses and Vascularized Spaces

Special attention should be given to the mandibular fat pads, the pterygoid sinuses, and the fibrovenous plexuses between them (Appendix 2-H). This region may be susceptible to acoustic and/or barotrauma and could be a source of fat emboli (an extra section should be collected and placed in Pen-fix or other special fat fixative). The peribullar sinuses should also be examined. Be sure to note the presence of parasites, blood clots, or unusual lesions within the sinuses or mandibular fat pads.

Brain and pituitary tissues to be collected: **If the carcass is fresh, collect a coin-sized tissue sample of pituitary, cerebrum (from occipital lobe) and cerebellum (from dorsal vermis) for ancillary diagnostic tests. Place the brain on piece of paper towel (do not wrap) and submerge in formalin (7–10 days fixation required prior to sectioning for histology). For large brains, more concentrated formalin can be used. Collect any active lymph nodes or other affected tissues according to your needs. Collect nuchal fat samples (frozen).**

If necessary, dissect, and examine the superficial cervical and retropharyngeal lymph nodes before decapitation. The axillary lymph nodes may be more readily located if the scapula is removed from the body starting at the dorsal border of the scapula. The axillary LNN are located at or near the brachial nerve plexus.

3. Eyes

Remove and examine the eyes. Examine the fatty tissue (retrobulbar periobital fat) behind the eyes for hemorrhage, and sample for histopathology.

4. Brain and Pituitary

Skin the top and sides of the head in order to search for bruising or other signs of trauma. If possible, once the soft tissue surrounding the skull has been examined and removed, the brain should be extracted. Cut away at the soft tissues over the cranial vault. Make two horizontal cuts: one through the occipital condyles and the other posterior to the nuchal crest. Joint these laterally with two vertical cuts. Use a chisel to break the bony septum that separates the hemispheres. Remove the bony plate to expose the brain. Examine the brain and associated meninges for congestion and lesions. Peel the dura

matter away from the brain case and examine the skull for fractures.

5. Ears

See procedure in Chapter 3.

I. Skeleton**—**lesions (i.e., any fractures, luxations, lacerations caused by broken or luxated bones)—remodeling—joint problems (i.e., dry and/or lumpy nucleus pulposus, osteoarthopathy)

Examine the synovial fluid of all large joints, particularly the glenohumeral and condylar joints. Additionally, the costovertebral and chevron joints have been implicated with DCS-like lesions in some divers and should therefore be examined for changes in the joint cartilage and underlying bone—osteonecrosis and osteoproliferative lesions. After exposing the ribs when flensing, the ribs can be disarticulated at the costo-vertebral joints. At least one costovertebral joint set (double-headed rib [Appendix 2-I]) should be collected for histology and the caudal vertebra of this pair could be examined for skeletal maturity. Additionally, a chevron-vertebral joint should also be collected. After removing the lungs, be sure to run your hand across all the ribs while moving the rib tips to locate any fractures. If evidence of trauma is found, remove the skin from the affected side of the carcass, look for bruising, and examine the vertebral column for fractures. Record the rib or vertebral number of the elements that are either fractured or luxated. Look for mandibular fractures (fresh or healing), particularly in adult males, and record presence and location. Photo-document any evidence of trauma or remodeling, and record the information on the skeleton and skull-lesion data sheet (Appendix 2-I and 2-J).

For description of a fracture include the following: (A) bone affected; (B) open or closed to body surface; (C) communicates with another structure; (D) type of fracture (simple transverse or oblique; spiral; comminuted; greenstick, etc.); (E) whether fractured ends are aligned or displaced; (F) whether fracture margins are sharp or smooth and have callus formation; (G) presence of foreign material, purulent material, osseous sequestrum; (H) presence of blood, edema, fibrosis, or purulent material in surrounding soft tissue or structure with which it communicates. All of this information helps determine the type

Tissues to be collected: **Collect samples of unusual fractures or unusual observations for further interpretation or for teaching.**

of trauma sustained, whether the fracture contributed to morbidity or mortality, possible sequelae, the potential for healing, and whether the fracture occurred antemortem.

Sample narrative:
e.g., Left ribs #s 9 and 10 had closed, simple transverse fractures of the proximal diaphysis with slightly rounded, nondisplaced ends and early callus formation. Left rib #11 had a compound (open), comminuted fracture of the proximal diaphysis. Left rib #11 was deep to the superficial wound pattern. There were well-formed blood clots in the intercostal regions adjacent to the rib fractures.

J. Other—lesions (i.e., any comments that don't fit in previous categories)—organ weights and dimensions (i.e., of organs not in previous list)

Lesion tissues to be collected: **If the carcass is fresh, and the lesions are indicative of cause of death or are of special interest, collect a sample (see tissue checklist, Appendix 2-I).**

Record any nonspecific lesions or comments such as weights of organs or tissues that have no specific category.

K. Morphological Diagnosis

A gross morphological diagnosis is a summation of the description of gross observations. It is, for most observations save for most traumatic injuries, inherently subjective because histologic examination of tissues is needed to corroborate findings. The structure of a morphological diagnosis varies among pathologists, but there are certain important elements:

- Tissue
- Modifier (if applies): Suppurative (abscess)
- Duration: Acute, subacute, chronic, etc.
- Distribution: Focal, multifocal, diffuse, etc.

Sample:

Description: The cranial surface of the left lung lobe had a focal, 2 × 4 × 2 cm, raised, white-gray, mass rimmed by a 1 mm to 3 mm erythematous line. On cut surfaces, the mass was filled with abundant cheesy-white, sticky, fetid material and was encapsulated.

Diagnosis:

Respiratory System:
Lung: abscess, focal, chronic

1. Significant Findings—important lesions and/or findings (i.e., enteritis, trauma, emboli)

Sample narrative:
e.g., Lesion in colon was associated with red mucosa; dark-red regions in each lung; nasopharynx was obstructed with thick mucus; depleted serous atrophied and edematous fats; meninges were moderately congested; numerous penetrating propeller wounds; fractured kidney; rib fractures (early healing), well-formed blood clots.

2. Most Probable Cause of Death—proximal cause of death **and suspected contributory causes of morbidity**—underlying conditions or conditions resulting from (i.e., sequelae to) a primary condition

Sample narratives:
e.g., natural; other (red tide)
e.g., watercraft

3. Necropsy Conducted by—examiners, participants, and/or observers present during necropsy (note: primary prosector and recorder)

NECROPSY PROCEDURE—SAMPLE-COLLECTION AND -CURATION

Samples from live and dead cetaceans provide valuable insights into the health of the individual and also contribute to studies to evaluate the health of the population. In collecting samples, three factors are important: (1) the development and use of standardized collection protocols; (2) the use of quality-assurance methods in specimen collection and analyses; and (3) the sharing of data and protocols among regional, national, and international groups (Rowles *et al.* 2001).

Carcasses may not be in the optimal state for all sample-collection protocols; depending on the condition code and state of decomposition, it may not be possible to collect all of the information. The best samples are obtained through careful dissection—avoiding contamination of tissues through contact with dirty instruments, other organs, or body fluids and avoiding cross-contamination during sterile sampling by resterilizing instruments between sample collections. At the beginning of the necropsy, be sure the type and quality of equipment and packaging materials are satisfactory for the task at hand; have a subset of the team dedicated only to sample-collection and processing under the direction of the primary prosector. Table 2.1 provides a guideline for the types of samples that can be collected by condition code. It is important

to note that information can be gleaned from carcasses in all states of decomposition.

In collecting information, there are three levels of data-collection:

> **Level A**—basic information primarily used to document and verify a stranding. Secondarily, this may include some (qualitative) information about cause and circumstance of stranding (and/or death of the animal). *Example:* Level A form, photographs, voucher specimens.
>
> **Level B**—Detailed, in-depth (supplemental) information about a stranding, individual, or life history. This information is generally the result of examination of samples obtained from the animal. Example: tooth age analysis, general histology, parasite identification and enumeration, herd composition.
>
> **Level C**—Detailed information about the cause and circumstance of stranding (or death). This information is generally the result of tests on samples that have been collected from the animal. *Example:* histopathology, bacteriology, virology.

Although stranding network respondents only are required to collect Level A data, this procedure's goal is to encourage the most complete necropsy possible with data-collection up to and including Level C. Chapter 1 focused on examination of and collection of important information from live animals; in this chapter and section, the discussion focused on tissue collection for freshly dead and Code 2 animals.

Table 2.1 Types of samples, by condition code, that can be collected

	Code 1 Collection Protocol	**Code 2 Collection Protocol**	**Code 3 Collection Protocol**	**Code 4 Collection Protocol**	**Code 5 Collection Protocol**
Document/Record/Report (all)					
1. Assign Field Number	×	×	×	×	×
2. Level A Data Use the National Stranding Form	×	×	×	×	×
Morphometrics	Obtain as many measurements as feasible considering human and animal safety. Total length is the priority. Use Cetacean and Pinniped Data Record.	Obtain as many measurements as possible. Use Cetacean and Pinniped Data Record. Tooth count	Obtain as many measurements as possible. Use Cetacean and Pinniped Data Record. Tooth count	Obtain as many measurements as possible. Use the Cetacean and Pinniped Data Record. Tooth count	Total length. Sex (?) Tooth and/or socket count
Sample Collection (ID verification/archive) (#1 for common; #1–3 for rare)					
1. Photographs **Suggested Photographs**	Whole animal, left and right sides Dorsal fin, left and right sides Close-up of the head Lesions, Abrasions, Net marks, Flukes	**Suggested Photographs (*close-up)** <u>External</u> Whole animal, left and right sides Dorsal fin, left and right sides Head, jaw, mouth* Lesions, Abrasions Ventral surface, genitalia	**Suggested Photographs (*close-up)** <u>External</u> Whole animal, left and right sides Dorsal fin, left and right sides Head, jaw, mouth* Lesions, Abrasions, Ventral surface, genitalia	**Suggested Photographs (*close-up)** <u>External</u> Whole animal, left and right sides Dorsal fin, left and right sides Head, jaw, mouth* Lesions, Abrasions, Ventral surface, genitalia	<u>External</u> Whole animal

	Code 1 Collection Protocol	Code 2 Collection Protocol	Code 3 Collection Protocol	Code 4 Collection Protocol	Code 5 Collection Protocol
		Flukes <u>Internal</u> Thoracic cavity Abdominal cavity Organs, if unusual Parasites * Lesions * Fetus <u>Circumstantial (document HI)</u> Net marks Foreign objects Possible (or reported) trauma	Flukes <u>Internal</u> Thoracic cavity Abdominal cavity Organs, if unusual Parasites * Lesions * Fetus <u>Circumstantial (document HI)</u> Net marks Foreign objects Possible (or reported) trauma	Flukes <u>Internal</u> Thoracic cavity Abdominal cavity Organs, if unusual Parasites * Lesions * Fetus <u>Circumstantial (document HI)</u> Net marks Foreign objects Possible (or reported) trauma	
2. Life History Samples		Stomach and contents, with ends tied off at the esophagus and small intestine—frozen in plastic Large intestine with fecal (seals) for otoliths—frozen in plastic Whole head, lower mandible or six teeth taken from the center of the lower mandible.	Stomach and contents, with ends tied off at the esophagus and small intestine—frozen in plastic Large intestine with fecal (seals) for otoliths—frozen in plastic Whole head, lower mandible or six teeth taken from the center of the lower mandible.	Stomach and contents, with ends tied off at the esophagus and small intestine—frozen in plastic Whole head, lower mandible, or six teeth taken from the center of the lower mandible. At least two unseparated vertebrae (include intervertebral disk, from cetaceans)	Whole head or skull, or at least jawbone with teeth. At least two unseparated vertebrae (include intervertebral disk, from cetaceans) ***Entire skeleton if rare species.***

	Code 1 Collection Protocol	Code 2 Collection Protocol	Code 3 Collection Protocol	Code 4 Collection Protocol	Code 5 Collection Protocol
		At least two unseparated vertebrae (include intervertebral disk, from cetaceans) **<u>*Entire skeleton if rare species.*</u>** **Reproductive Systems** Gonad measurements /slice of testis preserved in 10% neutral buffered formalin. Whole ovaries (preserved in 10% NBF)	At least two unseparated vertebrae (include intervertebral disk, from cetaceans) **<u>*Entire skeleton if rare species.*</u>** **Reproductive Systems** Gonad measurements /slice of testis preserved in 10% neutral buffered formalin. Whole ovaries (preserved in 10% NBF)	**<u>*Entire skeleton if rare species.*</u>**	
3. Genetic Samples	1. Sloughed skin 2. Buffy coat	"tissue" or bone Skin sample, 1" × 1" minimum. Preserved in DMSO, if possible. If not, frozen.	"tissue" or bone Skin sample, 1" × 1" minimum. Preserved in DMSO, if possible. If not, frozen.	"tissue" or bone Skin sample, 1" × 1" minimum. Preserved in DMSO, if possible. If not, frozen.	"tissue" or bone (frozen or in DMSO)
Sample Collection (health and/or cause of death)					
1. Parasites		Preserved in ETOH or 70% isopropyl (or NBformalin as substitute if neither is available)	Preserved in ETOH or 70% isopropyl (or NBformalin as substitute if neither is available)		

	Code 1 Collection Protocol	Code 2 Collection Protocol	Code 3 Collection Protocol	Code 4 Collection Protocol	Code 5 Collection Protocol
2. Histopathology		Only for special cases (i.e., if unusual species, human interaction, mass stranding, unusual mortality event, or unusual lesion present) Collect samples from all major organs and from any other tissues with lesions Lymph node samples should be labeled with collection site. *See AFIP histopathology checklist.	Early Code 3s Only for special cases (i.e., if unusual species, human interaction, mass stranding, unusual mortality event, or unusual lesion present) Collect samples from all major organs and from any other tissues with lesions Lymph node samples should be labeled with collection site. *See AFIP histopathology checklist.		
3 Virus isolation		Frozen in plastic, golf ball-to soft ball–sized sample if virus is suspected • Lung (×4) • Lung-associated lymph node (×2) • Spleen (×2) • Thymus (×2) • Brain (×2)	Frozen in plastic, golf ball–to soft ball–sized sample if virus is suspected • Lung (×4) • Lung-associated lymph node (×2) • Spleen (×2) • Thymus (×2) • Brain (×2)		

	Code 1 Collection Protocol	Code 2 Collection Protocol	Code 3 Collection Protocol	Code 4 Collection Protocol	Code 5 Collection Protocol
Preserved in 10% Neutral Buffered Formalin					
1. Toxicology (general and/or chemistry)		(biotoxi-cology) (call reference lab) Organics—50 100 g samples (baseball sized), frozen in foil (shiny side down), then wrapped in plastic. Liver, kidney, blubber, muscle Metals—same size, same tissue frozen in plastic—or hair (without skin 2 g)	Organics—50 100 g samples (baseball sized), frozen in foil (shiny side down), then wrapped in plastic. Liver, kidney, blubber, muscle Metals—same size, same tissue frozen in plastic—or hair (without skin 2 g)		

	Code 1 Collection Protocol	Code 2 Collection Protocol	Code 3 Collection Protocol	Code 4 Collection Protocol	Code 5 Collection Protocol
2. Bacteriology		Collect samples into sterile containers or transport media; transport to lab (check with lab for specific procedures for different organisms) (<24 hrs at room temperature; >24 hrs refrigerated) External openings (mouth, nose, genital) lesions, tissue surface associated with exudates discharge)			
3. Tissue Bank		Contact NIST for • Cetaceans with known time of death (24 hrs or less) • Mass strandings			
Clinical Samples (hematology and chemistry)					
1. Serology serum collected for detection of antibodies for:	•Morbilli-virus • Brucella • Herpes				

	Code 1 Collection Protocol	Code 2 Collection Protocol	Code 3 Collection Protocol	Code 4 Collection Protocol	Code 5 Collection Protocol
2. Serum Bank—save approx 1 cc serum frozen	Buffy coat (frozen white blood cells washed from green or blue top tubes—not EDTA)				

The following is a guide to help organize, prioritize, and understand procedures used to collect samples and specimens.

Code 2: Dead, fresh, intact. No bloating; as if just died. From time of death until just after rigor. No noticeable signs of autolysis.

I. Assign Field Number

II. Level A Data—

Use the National Stranding Form. See Chapter 1 for a description of Level A data

III. Morphometrics

Morphometrics provide basic biological and historical information. Obtain as many measurements as possible. Measurements are taken following the morphometric data sheet in Appendix 2-C. The procedure is straightforward, requiring one or two persons with a tape measure and, ideally, a third person to record. The measurements should be supplemented with photographic documentation. All measurements can be valuable, but standard length is consistently useful. Except for girth and other specified dimensions, **measurements are always taken in a straight line from point to point** and should not follow the contours of the animal. **Standard length** is the straight line distance from the tip of the snout (or the melon, if more anterior) to the tip of the tail or notch of the flukes. Girth measurements are useful only when there is no evidence of bloating. The girth of large whales is recorded as two times the measured distance between the mid-ventral and mid-dorsal points on one side of the body. Measurements or

weights that are estimated must be clearly indicated as such on the data sheet.

Count the number of teeth in the mouth of the carcass and record the tooth count on the data sheet.

Blubber measurements and thickness (does not include skin) are measured from a perfectly perpendicular cut; distorting the tissue distorts the results. The measurements are taken from a number of specific locations on the carcass, and multiple measurements are taken because blubber thickness varies with body region (See Appendix 2-E, blubber thickness data sheet).

IV. Sample Collection (ID verification/archive)

A. Photographs

Photographs are critical to documenting the collection of samples, Level A data, and the necropsy.

Suggested photographs with a marker of animal and ruler (*close-up):

External	Internal
Whole animal, left and right sides	Thoracic cavity
Dorsal fin, left and right sides	Abdominal cavity
Head, jaw, mouth*	Organs, if unusual
Lesions, Abrasions,	Parasites *
Ventral surface, genitalia	Lesions *
Flukes	Fetus

Circumstantial (document HI)
Net marks
Foreign objects
Possible (or reported) trauma

B. Life History Samples

Information on age, genetics, reproductive status, and feeding habits is vital to understanding the general biology of the species, developing demographic models, identifying discrete stocks, and planning conservation and management strategies (Geraci and Lounsbury 2005). Certain life-history information makes interpretation of pathologic and toxicological data more meaningful and, sometimes, essential. In general, biological data are additive; the more we can obtain on a given specimen, the more meaningful each element becomes (Geraci and Lounsbury 2005).

1. Teeth for Age Determination

In the field, teeth (or sections of skull or mandible) can be placed temporarily on ice, frozen, or packed in salt to retard tissue decomposition. Take the lower mandible or six teeth from the center of the lower mandible. In the laboratory, teeth can be extracted, cleaned in an enzyme preparation such as trypsin, labeled, and stored in 70% ethanol. It is wise to avoid drying, prolonged boiling, or use of solutions containing glycerin.

2. Other Bone Specimens

Bone specimens for aging studies can be frozen, preserved in 10% formalin or alcohol, or cleaned and dried without affecting the clarity of periosteal layers. The sample should include a bone end incorporating a cartilaginous growth plate or a scar of an old growth plate. Take at least two unseparated vertebrae (include intervertebral disk, from cetaceans) ***Entire skeleton if rare species.***

3. Genetic Samples

Skin and liver are the most commonly collected tissues for genetic analysis. White blood cells, muscle, gonads, teeth, and bone have also been collected from carcasses. Only a small sample is needed for genetic analysis, a 0.5 cm^3 or 1"×1" minimum sample (1 ml of whole blood, whole teeth, or a piece of bone). Preserve soft tissue in 5% to 20% dimethylsulfoxide (DMSO) in saturated salt solution at 1 volume to 10 to 20 volumes of preservative. The solution containing the tissue sample should then be frozen for long-term storage (Rowles *et al.* 2001). Soft tissues also may be frozen or preserved in 70% to 85% ethanol (one part sample to two to three parts preservative).

4. Stomach Contents

Collect contents from each stomach by carefully and gently flushing the contents into separate

labeled containers (plastic bag or bucket) and freeze or preserve in 70% ethanol (neutral buffered formalin will dissolve otoliths). Contents may include recognizable prey species, macerated flesh, skeletal fragments, otoliths—some so small as to be unapparent to the naked eye—numerous parasites, and a variable amount of fluid. Alternatively, after sample collection for histology, the stomach and its contents, with ends tied off at the esophagus and small intestine, can be collected as a whole and frozen in plastic. Another approach is to weigh full stomach, sieve stomach contents, dry otoliths and fish bones or spines, and place beaks and fresh remains in 70% ethanol (Rommel *et al.* 2001). There are three basic analysis: identification of prey, identification of parasites, and toxicology (biotoxin or anthropogenic). Because each type can affect the others, these analyses should be carefully coordinated. Subsamples for toxicology or biotoxins are collected from the stomach contents of fresh carcasses when they are first opened, and the subsamples are frozen for later evaluation.

Also the large intestine with fecal sample should be collected and frozen in plastic

5. Reproductive Systems

Remove, weigh, and preserve (in 10% neutral buffered formalin [NBF]) the entire reproductive tract and organs. Collect both (whole) ovaries (one uniquely identified) in glass jar with 10% NBF; if entire tract is collected, use a sealable plastic bucket to ensure ample formalin; label one horn and collect a sample of mammary tissue. Measure, weigh if possible, and preserve entire testes; repeat for epididymis. Cross-section (0.5 cm thick) from the center portion of left testis and section of vas or epididymis. Slice large testes to ensure proper fixation. Measure, weigh, and determine the sex of the fetus.

6. Core Temperatures

Postmortem temperatures (e.g., epaxial—just anterior to the dorsal fin—muscle, liver) give some indication of time since death. This is an undocumented aspect that might provide some insights, particularly if regional heterothermy plays a role in the biology of these animals (NOTE: carcass temperature roughly relates to the condition of the animal relative to environmental temperature. Temperature will go down [become uniform] then rise as animal decomposes.) To be complete, it is good to collect core temperature readings as it can help fix time of death relative to time of recovery.[2]

Temperature should be taken in deep epaxial muscle, mid-lumbar, or halfway between dorsal fin and blowhole. Drive deep temperature probe through blubber at 45º between transverse process and neural spine to the depth of the vertebral centrum. (Long stainless puncture probes and hand held readouts are available from Omega Engineering).

C. Sample Collection (health/cause of death)

1. Parasites

Collection and examination of parasites are important from both health and life-history perspectives. Collect and preserve samples of loose parasites, lifting them carefully with forceps or fine needles. Parasites should be collected intact—especially to preserve the head and mouth of the parasite—and fresh, and any associated lesions should be collected in 10% neutral buffered formalin, in 70% ethanol (preferable), or 70% isopropyl (preferable). ***Epibiota***—If you see any parasites or other epibiota collect as many as possible into a jar of fresh water, noting where they

---

2 NMFS observer program (in the NE anyway) has been taking temps for some years from a standard location—epaxial muscle just anterior to dorsal fin—see http://www.nefsc.noaa.gov/fsb/ Biological Sampling Manual—Marine Mammal section p. 44.

were found. If they are embedded, cut the surrounding tissue out. Put any associated lesions in 10% NBF.

2. **Histopathology**

Histology samples are most useful when collected from fresh (Code 2) carcasses; however, in many cases, tissues from moderately decomposed carcasses can provide invaluable insights into primary and even secondary pathological processes. Tissues for histopathology can vary significantly in form, texture, and location. Perhaps the most important aspects of histological sampling procedure are sampling location, proper and/or adequate labeling, and proper handling of the tissues. Tissues with important yet delicate mucosal surfaces such as the gastrointestinal tract and respiratory tree, should be handled or manipulated as little as possible, making sure that the mucosal surfaces are not scraped, rubbed, or palpated.

Care should be taken when using forceps to ensure that regions of the sample remain untouched or are not manipulated. Care should be taken with delicate organs such as the brain and lungs, to avoid squeezing or applying pressure to the tissue.

Collect samples from all major organs and from any other tissues with lesions; all tissue types, see histology check list (Appendix 2-K). Samples can be as long as desired, but must be thin enough for the formalin to penetrate and to properly fix the tissue (maximum thickness 0.5 cm), no thicker than a large wedding band. If larger tissues are collected, bread-loaf the organ by making parallel slices 0.5 cm apart[3]. Place the sample in 10% NBF, allowing for a tissue-to-formalin ratio of 1:10. Samples include all major organs, appropriate lesions, all major lymph nodes—for tissues that are not unique (e.g., lymph nodes, right and left lungs, and adrenals) and for those which it is important to

3Formalin penetrates about 1mm per hour (e.g., 0.5 cm per 5 hrs). If conditions limit the amount of formalin available, collect thinner pieces.

distinguish—identifiers such as laundry tags, spaghetti tags, or histology cassettes clipped on to an edge of the tissue should be used.

Lymph node samples should be labeled with collection site (see Appendix 2-K). Whole hearts should be sectioned (bread-loafed) according to the Kogia heart dissection protocol (e.g., Bossart *et al*.). After sampling for virology and bacteriology, whole brains should be placed in 10% NBF for at least six days in order to harden prior to sectioning. Once firm, brains should be sectioned (bread-loafed) and placed back into NBF for further fixation.

Whenever possible, livers should be sampled in multiple locations. A section should be collected from the margin as well as through the center of one of the lobes. Liver sections should include part of the hepatic portal and caval circulations. Lungs should also be sampled along the margins as well as near the center. For examination of mucosal surfaces, center samples should include primary and/or secondary airways.

Immunohistochemistry. Immunohistochemistry is a means of detecting cellular components and cell products; determining cell origin; and detecting pathogens. It can be done with formalin-fixed tissues, cytological specimens (immunocyto-histochemistry) and, less often, with frozen specimens specially embedded and preserved. Unfortunately, long-term storage in formalin may affect the quality of DNA and other cell components. It is best to paraffin-embed tissues within six to 14 days. If unable to meet this timeline, once tissues are fixed in formalin (two to three days depending on tissue thickness; four to six days for the brain), they can be transferred to ethanol for longer-term storage.

Fatty or adipose-rich tissues such as acoustic fats from the jaw or melon should be examined for gross signs of acute and/or chronic trauma, and should be sampled for histopathology and lipid constituent analysis. Fat samples for lipid/FA

analysis should be frozen. Histopathology samples of adipose tissues should be placed in 10% NBF.

3. Virus Isolation

A systematic approach to disease and viral detection is needed as part of a baseline approach to investigate the prevalence of disease and viruses in marine mammals. Most viruses are fragile and have a short life span in decomposing tissue. Viruses that persist long enough to be harvested and identified, however, are generally responsible for some infectious process. Cultures, polymerase chain reaction (PCR), serology, and electron microscopic evaluations are used for the detection of viruses.

Samples for viral culture should be collected as aseptically as possible. Tissue specimens or swabs are placed in viral transport media or in 1 to 2 ml of physiological saline with 5% bovine serum albumin containing approximately 50 μg/ml of gentamicin, and shipped immediately. If immediate shipment is not possible, tissues may be frozen at –70 to –80°C or colder for later shipment. PCR or nucleic acid hybridization can be performed on either frozen or fixed samples, although fresh-frozen samples are preferred (–70 to –80°C) The samples should be golf-ball to softball–sized sample if virus is suspected. Following are the tissues to be collected:

a. Lung (×4)
b. Lung-associated lymph node (×2)
c. Spleen(×2)
d. Thymus(×2)
e. Brain(×2)

4. Contaminants and Biotoxins (Toxicology and biotoxicology)

Marine mammals are the potential ultimate repository for oceanic contaminants passed through the food chain. Cetaceans may reveal the influence of contaminants and toxins on health. To be effective, the collection and preparation of

contaminant and biotoxin specimens must be impeccable and the samples matched with reliable life-history information. Deterioration of tissues after death leads to change in contaminant load, with the extent of change depending on the tissue and the analyte involved. Samples for the National Biomonitoring Specimen Bank must be taken within six hours of documented death.

A rigorous sampling protocol has been developed by the National Biomonitoring Specimen Bank (U.S. National Institute of Standards and Technology) and the Alaska Marine Mammal Tissue Project.[4] Following is the sample collection for contaminant and biotoxin analyses for non-NIST sample:

a. Blubber and other body fats concentrate lipid-soluble organic contaminants. Blubber is always accessible and may be the only practical tissue to collect. Samples (300–400 g, about 10 cm square) include the full thickness of the layer, without skin or muscle. Standardization of sampling sites is suggested for more accurate cross-comparison purposes. Two sites are recommended for cetaceans: one about 10 cm caudal to the blowhole and the other directly below the dorsal fin on the mid-lateral line.

b. Liver accumulates all known organic and inorganic contaminants and some biotoxins. Collect the entire liver from small carcasses. For

4 The NIST National Biomonitoring Specimen Bank protocol includes a target species list and specific criteria for each animal that must be met before samples can be collected for banking. Persons collecting samples specifically for the NMMTB must first be approved and trained by NIST personnel. The National Biomonitoring Specimen Bank protocol requires that the carcass be opened with clean stainless-steel instruments and that personnel wear talcum-powder–free vinyl gloves. Samples should be taken with a clean stainless steel or titanium knife (washed, rinsed with high-purity water followed by ethanol, and air dried). Each sample should then be trimmed using a clean titanium knife, washed with high-purity water, and cut into subsamples of suitable size for storage. Each subsample is placed in a pre-weighed Teflon® jar with a Teflon-lined lid; the jar is labeled and weighed again. Containers are then refrigerated for immediate analysis or frozen at –70 ° C or in liquid nitrogen for shipping or storage. At every stage of the procedure, care is taken to avoid chemical contamination of the tissues. All chemicals must be pesticide-free grade.

large ones, slice 300–400 g samples from the distal end of each side of the medial indentation.

c. Kidneys concentrate metals. Take both kidneys from small animals; from cetaceans, take the entire left kidney or a 300–400 g slice from the caudal end.

d. Brain and muscle are of questionable value. Brain decomposes quickly, and its removal from small animals requires skill and is often difficult. It is possible to measure changes in acetylcholinesterase resulting from exposure to short-lived pesticides and herbicides in brain tissue; for this purpose, it may be worthwhile to collect (and immediately freeze) the brain from small Code 2 animals. Indicate location in the brain from which any sample was taken.

e. Liver and blubber samples of about 100 g (about one-quarter pound or hamburger–sized) and lung (cranial pole), urine (if not available, then kidney), contents from stomachs or duodenal ampulla, feces, and blood are taken for biotoxin analysis such as Harmful Algal Bloom (HAB) Toxicology for ELISA (thumb-size samples) placed in whirl-packs and frozen.

f. Organics samples—collect 50 100 g samples (baseball-sized) using a clean (solvent washed, if possible) stainless-steel knife. Tissues are collected in clean glass jars, Teflon bags or jars, or placed in foil (shiny side down), then in plastic. The samples should be stored at temperatures less than –80°C.

g. Metals samples—collect the same size, same tissue, and freeze in plastic.

5. Bacteriology

Cetaceans harbor a variety of microorganisms, some of which are pathogenic. Even under ideal conditions, it is often difficult to associate bacteria isolated from a carcass with specific lesions.

Bacteria that are part of the normal flora may proliferate rapidly after death and may interfere with successful isolation of an offending pathogen (Geraci and Lounsbury 2005). Any study on normal flora requires that only the freshest, uncontaminated specimens be used. Bacteria associated with active infectious processes tend to endure longer in viable concentrations, and certain species may be isolated from more deteriorated carcasses, even frozen stored specimens (Geraci and Lounsbury 2005).

Sample selection for bacteriology is determined largely by the nature of the gross pathologic findings. Samples should be taken aseptically, first from external surfaces and then from body cavities and internal organs as soon as they are exposed. The core of a fleshy or hollow organ or fluid-filled lesion (e.g., abscess) is sampled by inserting a swab in an incision made through the sterile surface, prepared by searing or disinfected with 10% formalin or 70% ethanol and allowed to dry (Geraci and Lounsbury 2005). Fluid samples from a cavity are taken by aspiration (through a sterile surface) before or moments after opening (Geraci and Lounsbury 2005). *Note:* Bacteria within effusions or exudates are more diluted and often dead; therefore, sampling the associated surface often is more rewarding. Tissues destined for laboratory sampling (sear-sampling, cultures, impression smears) should be large enough (about 6 × 6 × 6 cm) to allow for trimming and must have one capsular or serosal surface intact (Geraci and Lounsbury 2005). Take separate samples and freeze additional tissues for later use.

Large lesions are sampled from two or three distinct regions; collect any lymph nodes in the vicinity. If intestinal infection is suspected, tie off a 10 cm loop and place in a sterile container (Geraci and Lounsbury 2005). Place swabs in the appropriate transport medium (generally available from diagnostic laboratories). Aspirated pus from abscesses and other lesions where anaerobic

organisms are suspected should be transported in anaerobic vessels (Geraci and Lounsbury 2005). *Note:* Bacteria within effusions or exudates are more diluted and often dead; therefore, sampling the associated surface often is more rewarding. Package tissues in sealed, sterile, leak-proof bags or jars (Geraci and Lounsbury 2005). Label, cool, and transport to the laboratory immediately. Avoid freezing samples for bacteriology; however, if long delays are unavoidable, freezing at –70° C is preferable to decomposition. Record conditions of collection and storage.

Fecal samples that cannot be cultured immediately can be placed in a stool preservative (equal volumes of 0.033 M phosphate buffer and glycerol) to prevent changes in pH.

Material taken for examination of mycotic agents (usually from the skin) is obtained by scraping with a scalpel blade and/or by removing a number of hairs from the affected area. The samples should be refrigerated until they can be inoculated onto a suitable growth medium (Geraci and Lounsbury 2005).

6. Entire head—If not scanning the head, remove the head intact, examine the oral cavity for abnormalities, and hold chilled.

7. Eyes—Collect aqueous humor, collect eyes entire (sans fluid from one). Remove the anterior segments and the globes, and immerse in either a modified Davidson's solution (available commercially) or in phosphate-buffered formalin (3%, pH 7.4) for 24–48 hours, and then transfer to formalin or alcohol (longer fixation in Davidson's solution will reverse the effect and harden the eye).

8. Immunology—Tissues taken for microbiology and virology (described previously) can be use to assess immune system function. Samples swabs should be taken from the blowhole, anus, U/G opening, eye, and mouth are in descending order of importance and placed in viral or bacterial transport media. These swabs can be stored frozen at –70° to –80°C. Samples should be taken of the liver, spleen, lymph nodes, kidneys, and

abdominal cavity when first opened and should be approximately 6 cm^3. Place tissue sample in a whirl-pack bag and store frozen at –70° to –80°C until shipped. Serum should also be collected, when possible, for evaluation of serum antibody titers.

9. Cerebro-spinal Fluid (CSF)—CSF may be collected by two methods: dorsal or ventral once the pluck has been removed. A sterile 16- to 20-gauge needle on a 3 to 6 ml syringe is inserted into the vertebral canal at the junction between the head (occipital condyles) and cervical vertebrae. When the syringe is inserted, a "pop" may be felt at the dura is breached. CSF fluid can be utilized for serology (morbillivirus), chemistry (alkaline phosphatase, creatinine, and total protein), and cytologic examination. If cytology and clinical chemistry cannot be completed within a few hours, freeze a portion (at least 1.0 ml) at -–80°C and place a small aliquot (0.5 to 1.0 ml) of CSF with a few drops of formalin. CSF degrades quickly, so freezing some and putting some with formalin may help preserve cells if they can't be analyzed within a few hours. Similarly samples of CSF should be taken for alkaline phosphatase, creatinine, total protein analysis.

10. Skeleton—Flense, dry, and store (frozen if practical) for final osteoprep.

11. Tympano-periotic Bones—See Chapter 3.

BIBLIOGRAPHY

Bossart, G.D., T.H. Reidarson, L.A. Dierauf, and D.A. Duffield. 2001. Clinical Pathology. Pp. 383–436 *In:* L.A. Dierauf and F.M.D. Gulland, eds., *CRC Handbook of Marine Mammal Medicine,* 2nd Edition, CRC Press, Boca Raton, Florida.

Hensley, G., G. Gregory Bossart, R. Ewing, *et al*. 2005 *Kogia Heart Dissection Manual.* Harbor Branch Oceanographic Institution, Inc. Technical Report No. 90.

Clark, L.S., D.C. Pfeiffer, and D.F. Cowan. 2005. Morphology and Histology of the Atlantic Bottlenose Dolphin *(Tursiops truncatus)* Adrenal Gland with Emphasis on the Medulla. Anat. Histol. Embryol. 34, 132–140.

Clark, L.S., D.F. Cowan, and D.C. Pfeiffer. 2006. Morphological Changes in the Atlantic Bottlenose Dolphin (*Tursiops truncatus*) Adrenal Gland Associated with Chronic Stress.

Crile, G., D.P. Quiring. 1940. A Record of the Body Weight and Certain Organ and Gland Weights of 3,690 Animals. Ohio Journal of Science 5:219-259—*for standards on trimming organs for weight comparisons.*

Daily, M.D., and R.L. Brownell, Jr. 1972. A checklist of marine mammal parasites. pp 528–589. *In:* Ridgway, S.A. (ed.) *Mammals of the Sea.* Charles. C. Thomas, Springfield, Illinois.

Duignan, P. 2000. Marine Mammal Autopsy Techniques and Sample Collection. Pp 387–428. *Marine Wildlife: The Fabian Fay Course for Veterinarians (Proceedings 335)*. Post graduate Foundation in Veterinary Science, Sea World, Gold Coast, Australia.

Duignan, P.J. 2000a. Diseases of Cetaceans and Pinnipeds. Pages 431-462. *Marine Wildlife: The Fabian Fay Course for Veterinarians (Proceedings 335)*. Postgraduate Foundation in Veterinary Science, Sea World, Gold Coast, Australia.

Duignan, P.J. 2000b. Marine Mammal Autopsy Techniques and Sample Collection. Pages 387–428. *Marine Wildlife: The Fabian Fay Course for Veterinarians (Proceedings 335)*. Postgraduate Foundation in Veterinary Science, Sea World, Gold Coast, Australia.

Dunn, J.L., J.D. Buck, and T.R. Robeck, 2001. Bacterial diseases of cetaceans and pinnipeds. Pages 309–335 in L.A. Dierauf and F.M.D. Gulland, eds. *CRC Handbook of Marine Mammal Medicine*. CRC Press, Boca Raton, Florida.

Evans, D.L., and G.R. England (eds.), 2001. Joint Interim Report Bahamas Marine Mammal Stranding Event. U.S. Department of Commerce (NOAA)/US Navy.

Fernández A., M. Arbelo, R. Deaville, I.A.P. Patterson, P. Castro, J.R. Baker, E. Deg, Ollada, H.M. Ross, P. Herrááez, A.M. Pocknell, E. Rodrííguez, F.E. Howie, A. Espinosa, R.J. Reid, J.R. Jaber, V. Martin, A.A. Cunningham, and P D. Jepson. 2004. Pathology: Whales, sonar and decompression sickness (reply). Nature 428.

Frantzis, A. 1998. Does acoustic testing strand whales? *Nature* 392:29.

Geraci, J.R and V.J. Lounsbury. 2005. Marine Mammals Ashore; A Filed Guide for Strandings. U.S. National Oceanic and Atmospheric Administration.

Houser, D.S., R. Howard, S. and Ridgway. 2001. Can diving-induced tissue nitrogen supersaturation increase the chance of acoustically driven bubble growth in marine mammals? J. Theor. Biol. 213:183–195.

Jepson, P.D., M. Arbelo, R. Deaville, *et. al.* 2003. Gas-bubble lesions in stranded cetaceans. Nature 425:575–576.

McLellan, W., S. Rommel, M. Moore, and D.A. Pabst. 2005. Right Whale Necropsy Protocol. Contract Report, Marine Mammal Health and Stranding Response Program, National Marine Fisheries Service. Pp 1–39.

Reynolds, J.E., III, S.A. Rommel, and M.E. Bolen. 2002. Post-cranial anatomy: orientation and organization of the soft tissues. Pp. 21–30 in: W.F. Perrin, B. Wursig, and H. Thewissen (eds.), *Encyclopedia of Marine Mammals,* Academic Press, San Diego, California.

Rommel, S.A., D.A. Pabst, and W.A. McLellan. (in press). Functional anatomy of the cetacean reproductive system, with comparisons to the domestic dog. Pp 127–145 *in*: Miller, D.E. (ed.) *Reproduction Biology and Physiology of Cetacea.*

Rommel S.A., A.M. Costidis, A. Fernandez, P.D. Jepson, D.A. Pabst, W.A. McLellan, D.S. Houser, T.W. Cranford, A.L. van Helden, D.M. Allen, and N.B. Barros. 2006. Elements of Beaked Whale Anatomy and Diving Physiology, and Some Hypothetical Causes of Sonar-related Stranding. Journal of Cetacean Management and Research 7:189–209.

Rommel, S., E. Haubold, A. Costidis, G. Bossart, and R. Meisner. 2002. Comparative Distribution of Lymph Nodes in Marine Mammals. Poster presented at the Florida Marine Mammal Health Conference. University of Florida Hotel and Conference Center, Gainesville, Florida. April, 2002.

Rommel, S.A., and L.J. Lowenstein. 2001. Gross and microscopic anatomy of marine mammals. Pp. 129–163 in: L.A. Dierauf and F.M.D. Gulland (eds.), *CRC Handbook of Marine Mammal Medicine,* 2nd Edition, CRC Press, Boca Raton, Florida.

Rommel, S.A., D.A. Pabst, W.A. McLellan. 2001. Functional morphology of venous structures associated with the male and female reproductive systems in Florida Manatees *(Trichechus manatus latirostris)*. Anatomical Record 264:339–347.

Rommel, S., D. Pabst, and W. McLellan. 2002. Skull morphology of marine mammals. Pp. 1103–1117 in: Perrin, W.F., B. Wursig, and H. Thewissen (eds.), *Encyclopedia of Marine Mammals*, Academic Press, San Diego, California.

Rommel, S.A. and J.E. Reynolds, III. 2002. Skeletal Anatomy. Pp. 1089–1103 *In*: W.F. Perrin, B. Wursig, and H. Thewissen (eds.), *Encyclopedia of Marine Mammals*, Academic Press, San Diego, California.

Schaller, O. (ed.) 1992. *Illustrated Veterinary Anatomical Nomenclature.* Ferdinand Enke Verlag, Stuttgart.

Appendix 2-A
External Lesions and Non-acoustic Human Interaction Data Sheet

BEAKED WHALE EXTERNAL LESIONS & NON-ACOUSTIC HI

Field # _____ **Date**_____ **Observer**_____

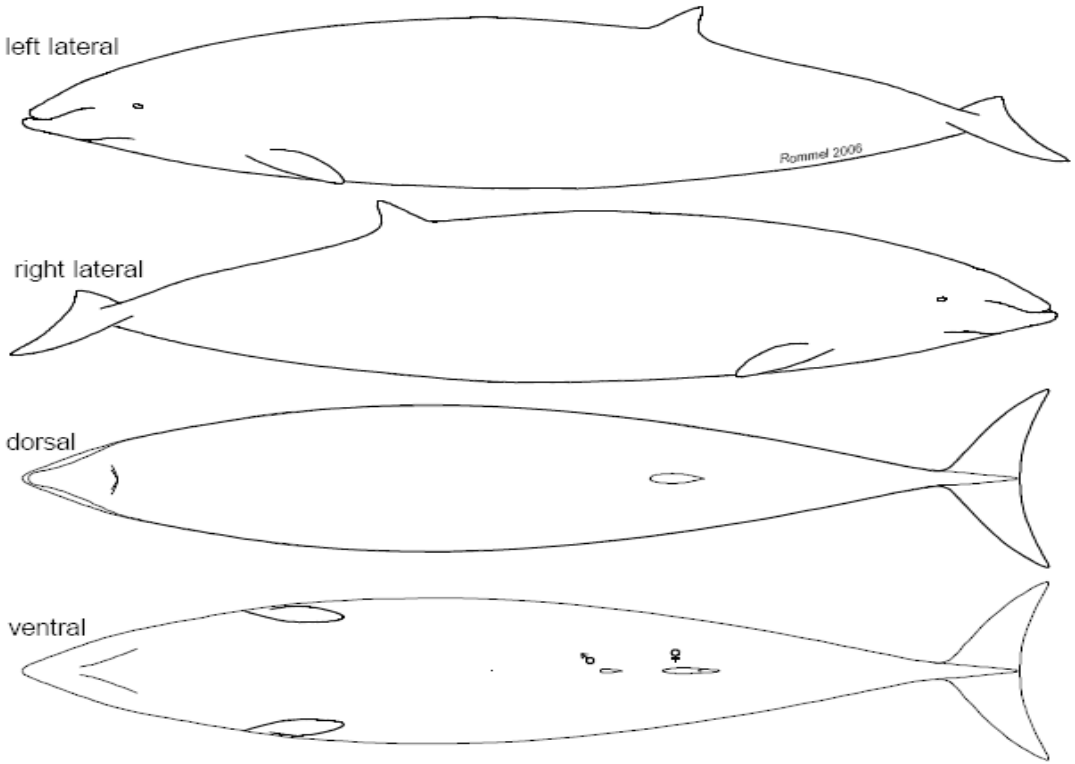

Left Side Observations:

_____
_____
_____
_____
_____

Right Side Observations:

_____
_____
_____
_____
_____

Dorsal Observations:

_____
_____
_____
_____
_____

Ventral Observations:

_____
_____
_____
_____
_____

Appendix 2-B
Paper Scale Templates

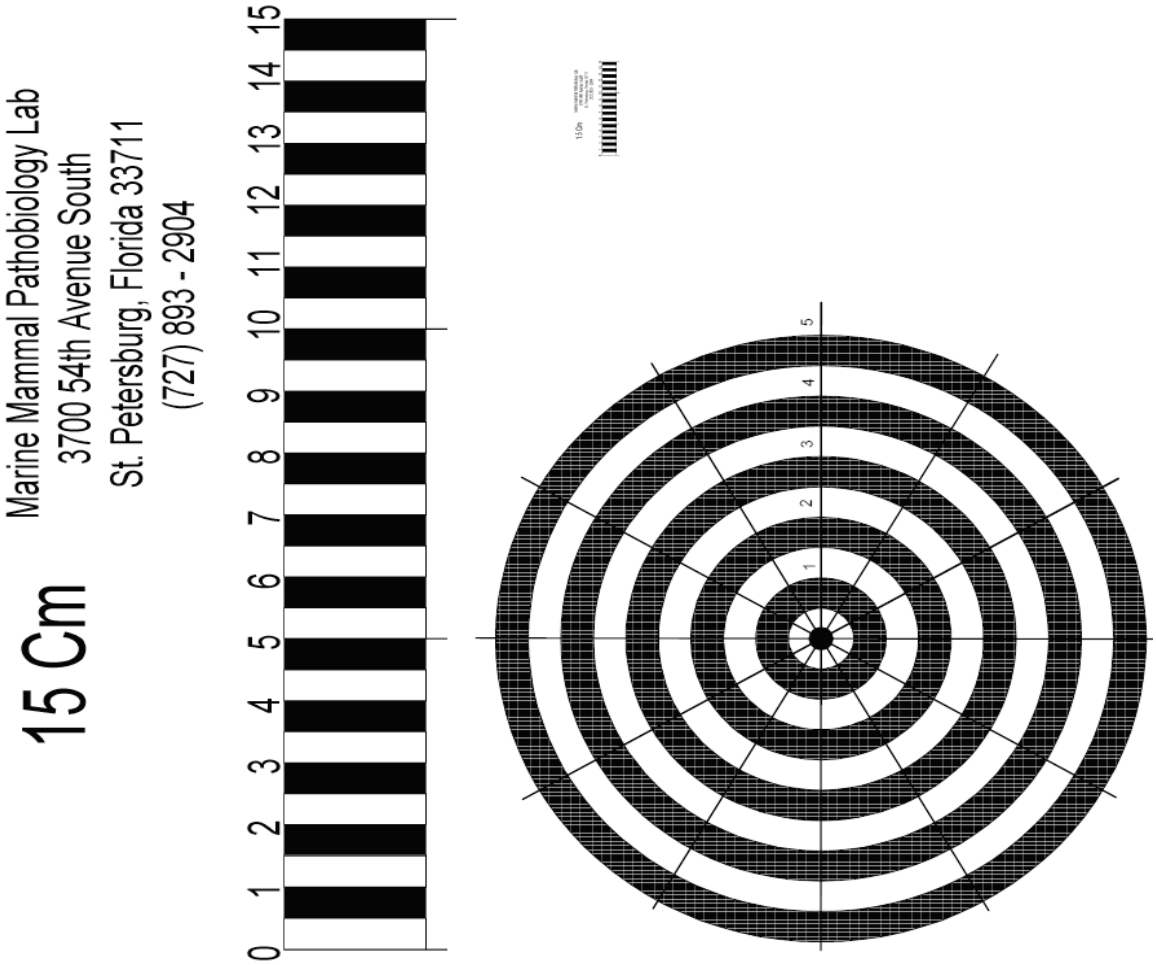

Periodically check scale for copying errors

Appendix 2-C
Necropsy Morphometrics Data Sheet

BEAKED WHALE MORPHOMETRICS

Field # _____ Date_____ Observer_____

Measurements are made from the tip of the snout, parallel to the long axis of the body

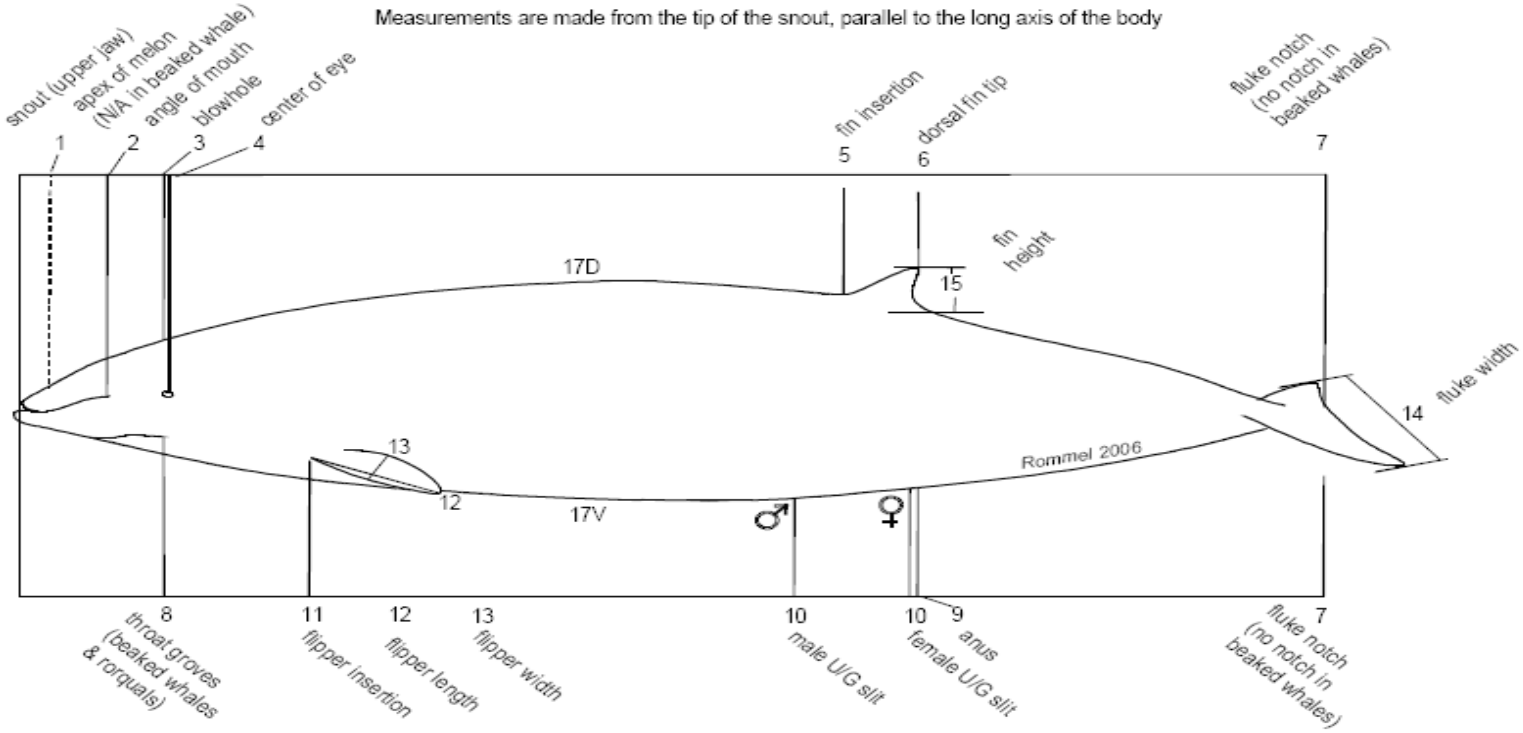

1. Snout to melon _____
2. Snout to angle of mouth _____
3. Snout to blow hole _____
4. Snout to center of eye _____
5. Snout to ant. insertion of fin _____
6. Snout to fin tip _____
7. Snout to fluke tip (notch if present) _____
8. Snout to caudal end of ventral grooves _____
9. Snout to center of anus _____
10. Snout to center of genital aperture _____
11. Snout to ant. insertion of flipper _____
12. Flipper length _____
13. Flipper width _____
14. Fluke width _____
15. Fin height _____

Appendix 2-D
Odotocete Necropsy Report

ODONTOCETE NECROPSY REPORT

SPECIES _____ FIELD NUMBER _____

LOCATION _____LAT_____/LONG_____

DATE _____ GENDER _____ TOTAL LENGTH _____

HISTORY:

EXTERNAL EXAM:

INTERNAL EXAM:

Field Number _____

Reminder for lesion description: general guidelines.

All descriptions should include at least the information listed below. Lesions should be described AFTER examining the cut surface. Lesions should be noninterpretative. The description should be thought of as if conveyed to a blind person (the histologist is often blind to the gross exam).

- Lesion type (e.g., laceration, mass, ulcer, effusion).
- Organ affected and the lesion's potential communication with adjacent structures
- Precise location within the organ (i.e., serosa/parenchyma; superficial/deep/full-thickness; cranial/caudal/middle; dorsal/ventral/lateral; left/right)
- Distribution within the organ (i.e., focal, multifocal, multifocal to coalescing, diffuse).
- Approximate total percentage of entire organ affected (<5%, 10%, 25%, 50%, 75%, 99%)
- Amount (mL) or size range (three dimensions, in cm) of lesion
- Modifiers: color, heterogenous/homogenous of appearance, texture, etc.

For a mass, include the following: encapsulated/unencapsulated, whether pushes or infiltrates adjacent tissue, whether central necrosis is present, and the location of the largest mass

For description of a fracture include: A) bone affected; B) open/closed to body surface; C) communicates with another structure; D) type of fracture (simple transverse or oblique; spiral; comminuted; greenstick, etc); E) whether fractured ends are aligned or displaced; F) whether fracture margins are sharp/smooth and have callus formation; G) presence of foreign material/purulent material/osseous sequestrum; H) presence of blood/edema/fibrosis/purulent material in surrounding soft tissue or structure with which it communicates. All of this information helps determine the type of trauma sustained, whether the fracture contributed to morbidity/mortality, possible sequelae, the potential for healing, and whether the fracture occurred antemortem.

Tissue sampling for histology:
When a lesion is present, take a sample of the lesion (including the leading edge), AND take a sample that does not appear to have the lesion. Should the lesion have more than one appearance, take a sample from each different appearing region. A sample from a bone lesion should extend from one cortex through the medulla and to the opposite cortex.

When possible, samples taken for ancillary diagnostic tests, such as microbiology, should be taken adjacent to that section submitted for histology.

a. Digestive System

Mouth:

Tongue:

Esophagus:

Fore Stomach:

Field Number _____

Main Stomach:

Pyloric Chambers:

Duodenum:

Intestine:

Colon:

Anus:

Describe content found in GI tract per each segment:

Describe parasites found in GI tract:

Liver:

Pancreas:

Mesenteric lymph nodes:

b. Blubber:

Field Number _____

c. Musculoskeleton

Axial Muscle:

d. Axial Skeleton

Thoracic Vertebrae:

Lumbar Vertebrae:

Caudal Vertebrae:

Ribs and Sternum:

Flippers:

Flukes:

Cranium:

Field Number _____

e. Circulatory System

Heart:

Great Vessels:

Cranial Circulation:

Spinal Circulation:

f. Respiratory System:

Blowholes:

Nares:

Larynx:

Trachea:

Lungs:

Bronchi:

Alveoli:

Field Number _____

g. ***Urinary System:***

Kidneys:

Ureters:

Bladder:

Urethra:

h. Endocrine and Hemolymyphatic Systems:

Thymus:

Thyroid:

Adrenals:

Pituitary:

Spleen:

Lymph Nodes:

Field Number _____

i. Reproductive System

FEMALE

Ovaries:

Uterine Horns:

Uterus:

Cervix:

Vagina:

Mammaries:

MALE

Testes:

Epididymis:

Vas Deferens:

Prostate:

Seminal Vesicles:

Penis:

Field Number _____

j. Central Nervous System

Brain:

Spinal Cord:

k. Sensory Organs

Eyes:

Ears:

l. Conclusions:

m. Cause of Death from Field Determination:

n. Contributory Conditions from Field Determination:

Field Number _____

This report was generated by:

Field Number _____

o. Additional Observations:

1. Evaluation of Human Interaction

Field Number _____ Species_____

Date_____ Location_____

Code 1 2 3 4 5

External Examination

A. Body Condition: Emaciated specimens often exhibit sunken epaxial musculature and neck

Emaciated_____ Not Emaciated_____ CBD_____ N/E_____

B. Net or Line Marks: Indicate Y/N/CBD/NE for each area and carefully describe net or line marks:

Head _____ D.Fin_____ L.Flipper_____ R.Flipper_____ Peduncle_____Other__

C. Fishing Gear Present on Animal (Yes) or (No)

D. Gear Retained (Yes) or (No)

E. Penetrating Wounds: Yes____ No____ CBD____ N/E____

F. Mutilations: Body Slit or Mutilated? Yes____ No____ CBD____ N/E____

G. Hemorrhaging / Bruising: Yes____ No____ CBD____ N/E____

Describe extent and area:

_____

_____

Internal Examination

A. Sub-Dermal Hemorrhaging: Yes____ No____ CBD____ N/E____

Describe extent and area:

_____

_____

B. Broken Bones: Yes____ No____ CBD____ N/E____

Describe:

_____

_____

D. Stomach Contents Retained: Yes ____ No____

E. Histopathology Samples Retained: Yes ____ No____

F. Gross Pathology: Yes____ No____ CBD____ N/E____

Describe:

_____

_____

*CBD—Cannot be determined

*N/E—Not examined

Appendix 2-E
Blubber Thickness Data Sheet

BEAKED WHALE BLUBBER THICKNESS

Field # _____ **Side Examined** _____ **Observer** _____ **Date** _____

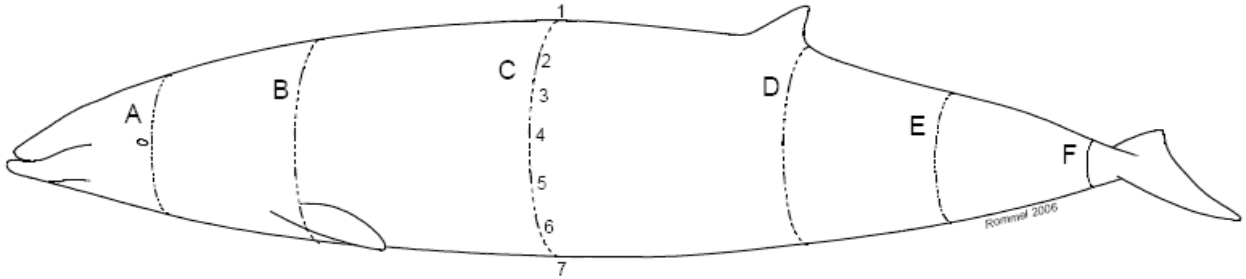

	A Nuchal Crest	B Axilla	C Umbilicus	D Anus	E Mid peduncle	F Fluke insertion
Dorsal 1	_____	_____	_____	_____	_____	_____
2	_____	_____	_____	_____	_____	_____
3	_____	_____	_____	_____	_____	_____
4	_____	_____	_____	_____	_____	_____
5	_____	_____	_____	_____	_____	_____
6	_____	_____	_____	_____	_____	_____
7 Ventral	_____	_____	_____	_____	_____	_____
Circumference with blubber	_____	_____	_____	_____	_____	_____
Circumference w/out blubber	_____	_____	_____	_____	_____	_____

Appendix 2-F
Abdominal Cavity Data Sheet

BEAKED WHALE ABDOMINALCAVITY illustrations of *Tursiops*

Field # _____ Date_____ Observer_____

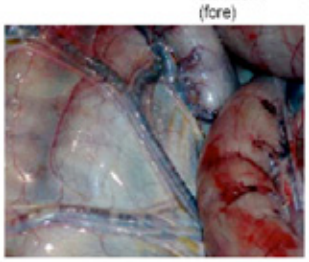

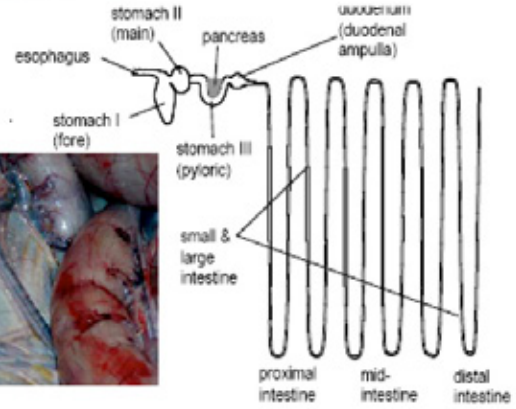

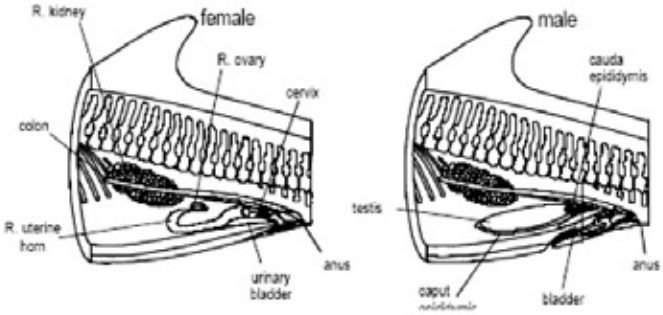

Liver Observations:

_____
_____
_____
_____
_____
_____
_____

GI Tract Observations:

_____
_____
_____
_____
_____
_____
_____

Kidney & Repro Observations:

_____
_____
_____
_____
_____
_____
_____

Appendix 2-G
Thoracic Cavity Data Sheet

Field # _____ **Date**_____ **Observer**_____

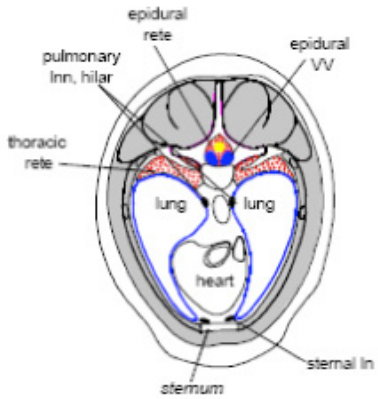

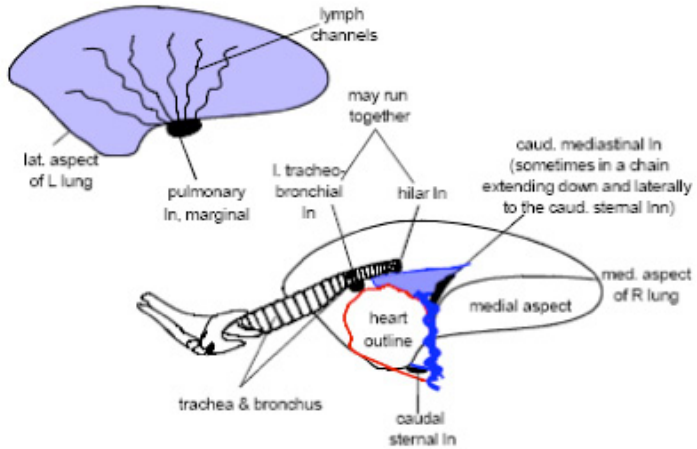

Left Side Observations:

_____
_____
_____
_____
_____
_____
_____
_____

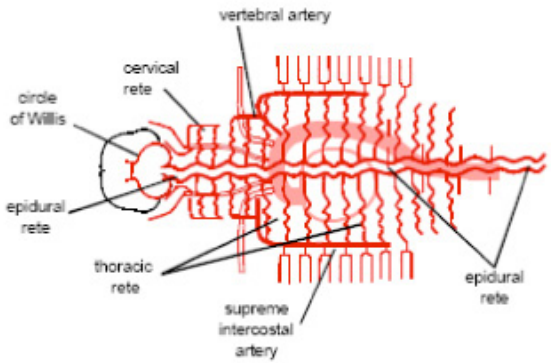

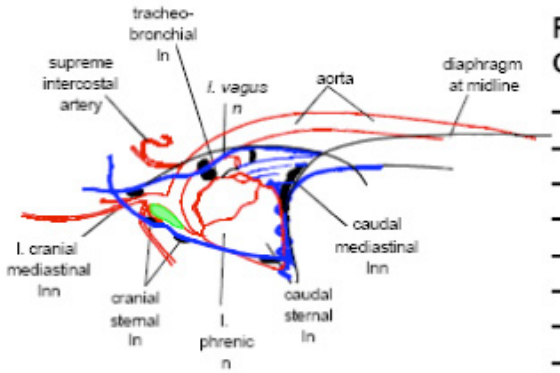

Right Side Observations:

_____
_____
_____
_____
_____
_____
_____
_____

Appendix 2-H
Reference Drawings of Head

REFERENCE DRAWINGS FOR HEAD from *Tursiops* after Rommel *et al* 2006; mark lesion sites

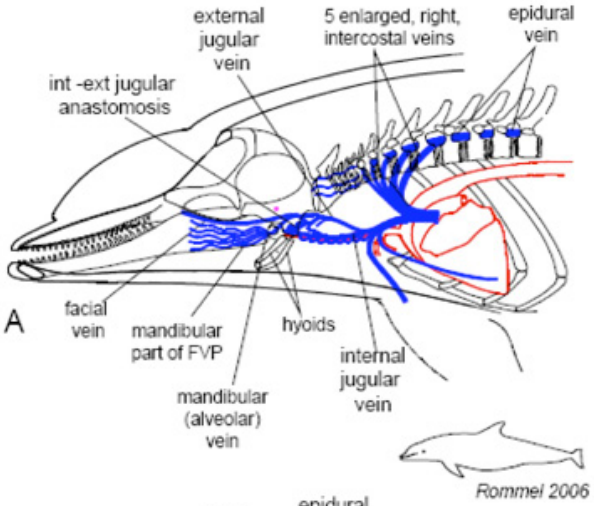

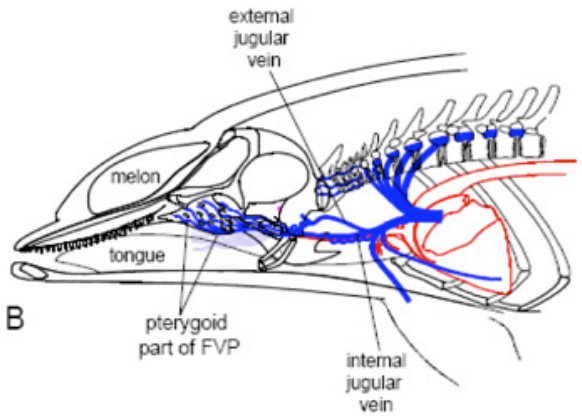

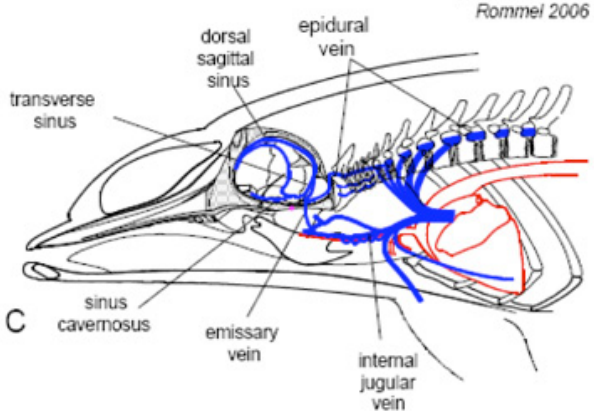

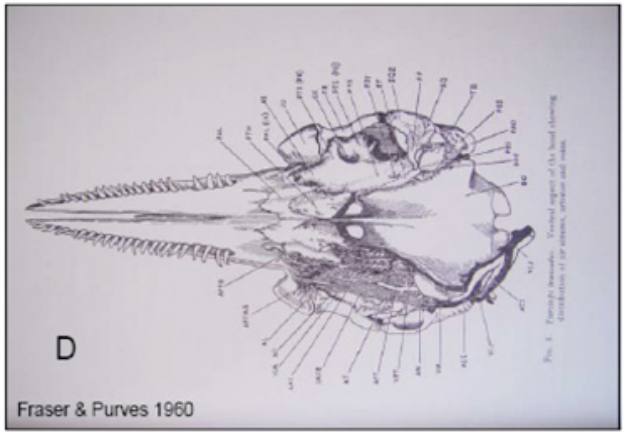

Appendix 2-I
Skeleton Lesions Data Sheet

BEAKED WHALE SKELETON LESIONS

Field # _____ Date_____ Observer_____

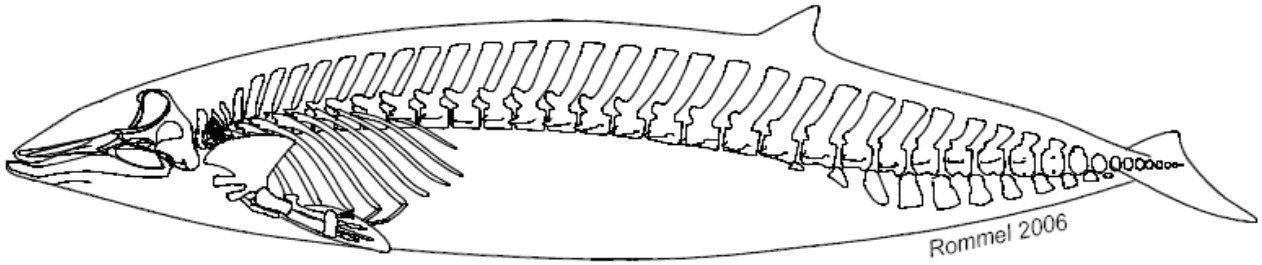

Left Side Observations: _____

_____

_____

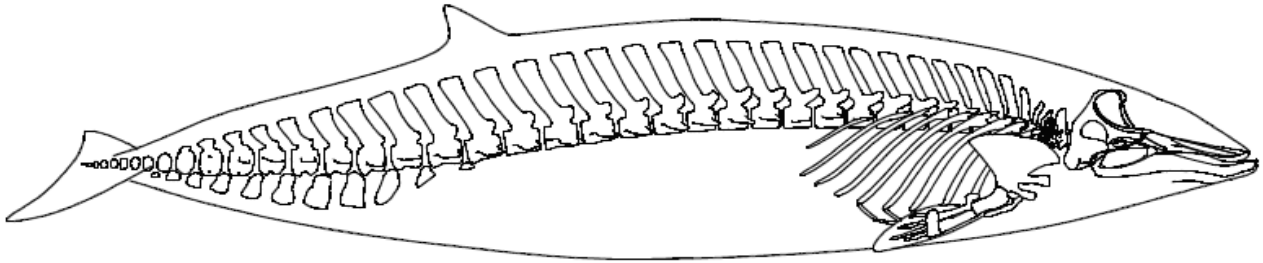

Right Side Observations: _____

_____

_____

Appendix 2-J
Skull Lesions Data Sheet

BEAKED WHALE SKULL LESIONS

Field # _____ **Date**_____ **Observer**_____

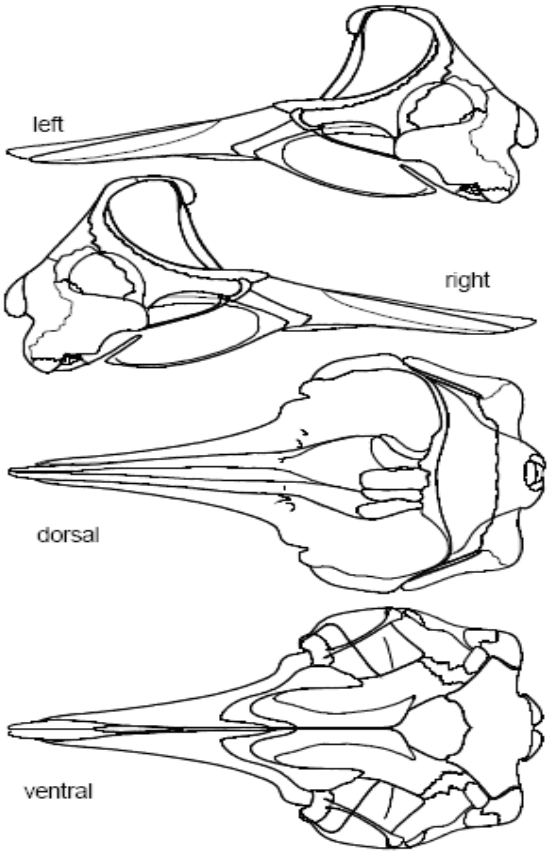

Left Side Observations:

_____
_____
_____
_____
_____

Right Side Observations:

_____
_____
_____
_____
_____

Dorsal Observations:

_____
_____
_____
_____
_____

Ventral Observations:

_____
_____
_____
_____
_____

Appendix 2-K
Tissue Collection Check List

Tissue collection check list --- three-letter abbreviations standardized for histology cassettes
A= archive, F=Formalin, C = culture, T = toxicology, FT=fat protocols (signature & stains), TH= thoracic, AB= abdominal, lnn = lymph nodes

Collected Y/N	*Tissue*	*Site*			*A*	*F*	*C*	*T*	*FT*	*Comments*
Head & Neck		**Left**	**Right**							
	Conjuctiva of the Eye (CNJ)					F	C?			culture of subconjunctival region if evident ocular lesions (ulcers, discharge)
	Cerebrospinal fluid (CSF)				A		C			
	Melon					F			FT	
	Larynx					F				
	Eustachian tube					F	C			
	Peribullar plexus					F	C		FT	
	Mandibular fat					F			FT	include vascular tissue
	Fibrovenous plexus (FVP)					F			FT	
	Pterygoid sinus (PTS)					F				collect both medial & lateral walls of cavity (labeled)
	Tonsils w/ pharynx (TNL)				A	F				
	Superficial cervical lnn (SPC)				A	F				
	Larynx (LRX)					F				
	Thymus (THM)					F				
	Thyroid (THR)					F				
	Brain case w / dura @ hiatus (BC@H)					F				When brain is exposed collect bone sample
	CNS									examine both sides of brain, sub-sample for encephalitis/infection, sample 1/2 brain 1/2 frozen @ -80°F -- if CT'd or MRI'd & abnormality detected then section accordingly, if not or if results are negative then sample as protocol
	Cerebrum (CBR)				A	F	C	T	FT	
	Cerebellum (CBL)					F				
	Brainstem (BST)					F				
	Pituitary (PIT)					F				
	Cranial nerves					F	C			swab and collect sample of CNVIII

A= archive, F=Formalin, C = culture, T = toxicology, FT=fat protocols (signature & stains), TH= thoracic, AB= abdominal, lnn = lymph nodes

Thorax		*Left*	*Right*							
	Thoracic cavity						C			swab pleura
	Trachea (TRA)					F				
	Lung (LNG)	cranial	cranial		A	F		T	F	
		middle	middle			F				
		caudle	caudle			F				
	Heart	Atria (HTA)				F				use Kogia protocol if applicable
		Ventricles (HTV)				F				
		Valves (HVA)				F	C?			culture if high profile case
	Vascular Structures	Aorta				F				
		Epidural rete			A	F			FT	include spinal cord in histo sample
		Thoracic rete			A	F			FT	
	Tongue	Tip (TGT)	Root (TGR)			F				
	Mediastinal lnn (MDS)					F				
	Tracheobronchial lnn (TRB)				A	F				
	Pulmonary lnn (PLM)	Marginal	Hilar			F				
Abdomen		*Left*	*Right*							
	Abdominal cavity						C			swab peritoneum
	Liver (LVR)	Proximal	Distal			F		T		
	Stomach walls (STM)	1st	2nd	3rd		F				additional chambers in beaked whales
	Stomach contents					A				seal in bag, & and freeze
	Duodenal ampulla					F				
	Intestine	Proximal (PIN)				F				
		Mid (MIN)				F				
		Distal (DIN)				F				

A= archive, F=Formalin, C = culture, T = toxicology, FT=fat protocols (signature & stains), TH= thoracic, AB= abdominal, lnn = lymph nodes

	Feces				A			T		
	Kidneys (KID)				A	F		T	FT	
	Gonads (GND)					F				
	Uterine Horns (UTH)	Mucosa, mid-length on both horns				F				if present, collect scar and adjacent region
	Vas Deferens (VDF)					F				
	Epididymis	Proximal (PED)	Distal (DED)			F				
	Urinary Bladder (BLD)				A	F		T		cranial pole of bladder for histo
	Colic lnn (CLC)									
	Anorectal lnn (ANR)					F				
	Spleen (SPL)				A	F	C	T		
	Thoracic spinal cord epidural rete (TSC)				A	F			FT	sample both spinal cord and rete for histo ~@ mid-thoracic level
	Mesenteric lnn (MES)				A	F				
	Adrenal (ADR)				A	F				
	Pancreas (PAN)					F				
	Mammary (MAM)				A	F				
Other Tissues		*Left*	*Right*			F				
	Diaphragm (DIA)					F				
	Rib marrow				A	F			FT	
	Skin	Lip (LIP)	Urogenital (UGN)	Mediolateral (MLT)	A	F				
	Synovial joints	Occipital condyle (OCC)	glenohumeral joint (GHJ)			F				
		Costo-vertebral joint @ T-2,3	Chevron-vertebral joint			F				

		(CVJ)	@ anus (CHJ@A)							
	Blood				A		C	T		from thoracic vena cava
	Urine				A			T		
	Muscle?									
Other Lymph Nodes		**Left**	**Right**							In general for abnormal lymph node(s) culture node(s), freeze a piece @ -80^{0}F, and send a swab for routine culture. Be sure to label all individual lnn!.
	Axillary (AXL)									
	Ext. Auditory Meatal (EAM)									may be important in trapping FE
	Retropharyngeal (RPH)									
	Sternal (STN)	Cranial	Caudal (L/R)							
	Aortic (ART)	Thoracic	Lumbar							
	Gastric (GTR)	Hepatic	Pancreatic	Gastric						
	Diaphragmatic Abd. (ABD)									
	Iliac (ILC)	Medial	Lateral							
	Head parasites	middle ears								only if extruding from it; 70% ETOH
		pterygoid sinus								70% ETOHl
	Other									

General Rules:
1) If lesion: culture (bactT / Fungal); archive
2) If suspect sepsis: culture liver, spleen, lung, lymph node, kidney, heart valve
3) If suspect virus: LN, Lung, spleen, liver, tonsil + other
4) Abnormal lymph node(s) culture node(s), freeze a piece @ -80^{0}F, and send a swab for routine culture
5) Fat protocol must define appropriate storge – formalin?, freezing? etc.

Chapter 3
Procedure for the Removal, Fixation, and Preservation of Cetacean Ears

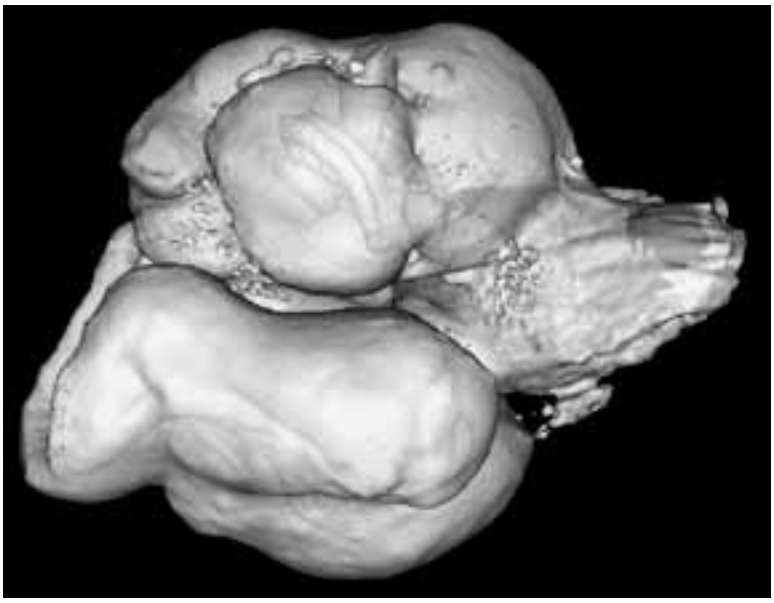

Darlene R. Ketten
Scott Cramer
Julie Arruda

Biology Department
Woods Hole Oceanographic Institution
Woods Hole, Massachusetts

Department of Otology and Laryngology
Harvard Medical School

July 2007

PREFACE

This chapter is intended as an instructional guide for the removal, fixation, and preservation of auditory system tissues of marine mammals. Each section describes procedures for a major ear type for marine mammals. The main intention is to provide both inexperienced and seasoned stranding responders with sufficient instructions to locate, document, and remove all structures related to the ears and hearing in order to optimize the fixation and preservation of these tissues for later, more-extensive examination. It is strongly recommended that examination be performed collaboratively with auditory system experts, but careful documentation and preservation are the critical first steps that will allow accurate diagnoses.

Key Terms: inner ear; cochlea; ossicles; vestibular system; auditory bulla, temporal bones, peribullar tissue, round window, oval window, hearing, auditory system

CONTRIBUTORS

Text
Darlene Ketten
Scott Cramer

Photographs
Darlene Ketten
Scott Cramer

CT Imaging
Darlene Ketten
Julie Arruda
Scott Cramer

Illustration
Darlene Ketten
Inge Milde

EQUIPMENT

Animal size, condition, and location influence the equipment available for any necropsy. Items cited in bold and italics are useful in all necropsies. Items cited in plain text are helpful, but not critical. **At a minimum, for most ear extractions, you will need one small, thin-bladed knife and one large heavy-bladed knife**.

—Surgical Tools—	
Knives—multiple lengths, serrated and plain edged	***Hammer***
Scalpels—handles and blades	Chain Saw
Clamps—forceps and hemostats	***Chisels—narrow to broad blade***
Saws—hand and electric	Rope
Narrow flexible tubing or catheters	Twine
Probe Sharp	Plastic Ties
Probe Blunt	***Duct® Tape***
Metzenbaum Scissors Straight *	***Measuring Tape Nylon or Plastic (metric)***
Metzenbaum Scissors Curved *	***Ruler (metric)***
Syringe (1, 5, 10 and 50 cc)	***Thermometer—electronic probe type or conventional***
Suture Kits	***Headlamp***
Calipers	***Flashlight***
Femoral Disarticulator	***Screwdriver—Flathead; Long Blade***
Ronguers and Bone Shears	***Crow Bar***
Meat Hooks (with handles and/or hooks with attached chain)	**Hack Saw and Blades**
Cutting Board or Sheet (plastic)	***SawzAll® and Blades***
Scalpel Blade Remover	Cordless Drill
Sharpening Stone	

—Safety and First Aid—		
Safety Glasses	Wet Suits	Elastic Bandage
Survival Suits	***Ice Packs***	QuickClot® *
First Aid Kit—Professional	***Sunscreen***	***Disinfectant Soap and/or Hand Cleaner***
Hand Warmers	***Soap and Shampoo***	***DermaBond® or generic super glue***
Ear Plugs	Dry Suits	

—Bag, Containers, Labels, Pens, and Pencils—		
Whirl-paks®	***Permanent Markers***	Histology Cassettes
***Sealable Plastic Bags* (e.g., ZipLoc®)**	Cooler	Duffel Bag
Plastic Bags	***Labels and Tags***	***Lidded buckets***
Garbage Bags	***Pencils***	
Body Bags	***Plastic Containers (25 to 500 mL)***	
—Miscellaneous—		
Necropsy Forms	Cloth Towels	**Compact Discs for archiving images**
Formalin®	Microscope Slides	
Expanding Foam	Ethanol	
—Audio and Video Equipment—		
Digital Video Camera and Tapes	**Waterproof Housing for Camera(s)**	
35mm Digital Camera	**Tripod Stand and Case**	
35mm SLR Camera	**Storage Media**	
—Clothing and Gloves—		
Disposable Latex® Gloves	Rain Suit	
Sterile Gloves	***Rubber Boots***	
Nitrile Gloves	Surgical Gowns	
Dish Gloves	Scrubs	
Plastic/Rubber Aprons		

***** Available through medical or veterinary supply outlets.

FIELD AND LABORATORY NECROPSY KIT CHECKLIST—SAMPLE

Date:_____ Location:_____Description:_____

Item	S	M	L	Other	Item	S	M	L	Other
Surgical Instruments and Tools									
Autopsy Handle, Grey					Needles (Gauge 22 or smaller—25, 28)				
Scalpel Handle, No. 4					Sutures				
Scalpel Handle, No. 5					Calipers				
Scalpel Handle, No. 6					Femoral Disarticulator				
Scalpel Handle, No. 7					Bone Shears				
Scalpel Handle, Long Straight					Spreaders				
Scalpel Handle, Long Curved					Meat Hooks				
Autopsy Blade, No. 60 (pointed tip)					Rib Cutters				
Autopsy Blade, No. 70 (rounded tip)					Endoscope				
Scalpel Blade, No. 10					Methyl Blue				
Scalpel Blade, No. 11					Contrast				
Scalpel Blade, No. 12					Scalpel Blade Remover				
Scalpel Blade, No. 15					Sharpening Stone				
Scalpel Blade, No. 20					Sharpening Steel				
Scalpel Blade, No. 21					Crow Bar				
Scalpel Blade, No. 22					Hack Saw and Blades				
Scalpel Blade, No. 23					SawzAll and Blades				
Hemostats Straight					Cordless Drill				
Hemostats, Curved					Dremmel Tool				
Forceps					Hammer				
Gigli Saw and Wires					Electric Chain Saw				
Stryker Saw and Blades (with cord)					Chisels				
Stryker Saw and Blades (portable)					Rope				
Knives					Twine				
Probe, Sharp					Wire Ties				
Probe, Blunt					Duct Tape				
Histology Cassettes					Measuring Tape Metal				

Item	S	M	L	Other	Item	S	M	L	Other
Surgical Instruments and Tools *(continued)*									
Metzenbaum Scissors Straight					Measuring Tape Nylon				
Metzenbaum Scissors Curved					Ruler (cm)				
Balloon Catheters					Thermometer				
Catheter Sheaths					Thermocouple and T-wires				
Vacuum Catheters					Flashlight				
Syringe Barrels (any size—1 cc needed for injection)									
Safety and First Aid									
Safety Glasses					Wet Suits				
Survival Suits					Ice Packs				
First Aid Kit					Sunscreen				
Hand Warmers					Soap and Shampoo				
Ear Plugs					Hand Cleaner				
Dry Suits									
Bags, containers, Labels, Pens, and Pencils									
Whirl Paks					Sharpie Markers				
Ziploc Bags					Cooler				
Plastic Bags					Plastic Containers				
Garbage Bags					Glass Containers				
Body Bags					Vials				
Labels and Tags					Histo Cassettes				
Pencil					Duffel Bag				
Miscellaneous									
Necropsy Forms					Cloth Towels				
Formalin					Gauze				
MO Discs					ETOH				
Microscope Slides					**Compact Discs for archiving images**				
Great Stuff Expanding Foam Insulation									

Item	S	M	L	Other	Item	S	M	L	Other
Audio and Video Equipment									
Sony Digital Video Camera and Tapes					Olympus SLR 35mm Camera				
Sony Digital 35mm Camera					Waterproof Housing for Sony Digital 35mm Camera				
Olympus Dig ital 35mm Camera					Waterproof Housing for Sony Digital Video Camera				
Nikon Digital 35mm Camera					Tripod Stand and Case				
Clothing and Gloves									
Latex Gloves					Rain Suit				
Sterile Gloves					Rubber Boots				
Nitrile Gloves					Surgical Gowns				
Dish Gloves					Scrubs				
Plastic Aprons									

ODONTOCETE EAR REMOVAL

EXTRACTION

Documenting the procedures and tissue condition as you proceed with ear extraction is crucial. Photograph the area you are working on before and after each stage of the procedures, being sure to add a scale and a marker indicating any abnormal area. Take wide-area and close-up shots of such areas. Label areas on the photograph consistent with the labeling of tissues subsampled from each area.

Approach odontocete ears from the side of the animal unless the lower jaw has been removed. Each ear consists of two joined spheres of dense bone: one hollow (tympanic), which forms the middle ear cavity; and one nearly solid (periotic), which contains the inner ear. These paired bones sit in a cavity (peribullar sinus) below the brain case, bounded by the squamosal (lateral and dorsal) and the exoccipital (posterior and medial).

Figure 3.1a—Bottlenose Dolphin (Tursiops truncates) with a marker for lateral ear extraction incisions.

Figure 3.1b—Lateral view of a harbor porpoise (Phocoena phocoena) head heavily flensed to show the right tympanic ear bone and anterior region of the peribullar sinus.

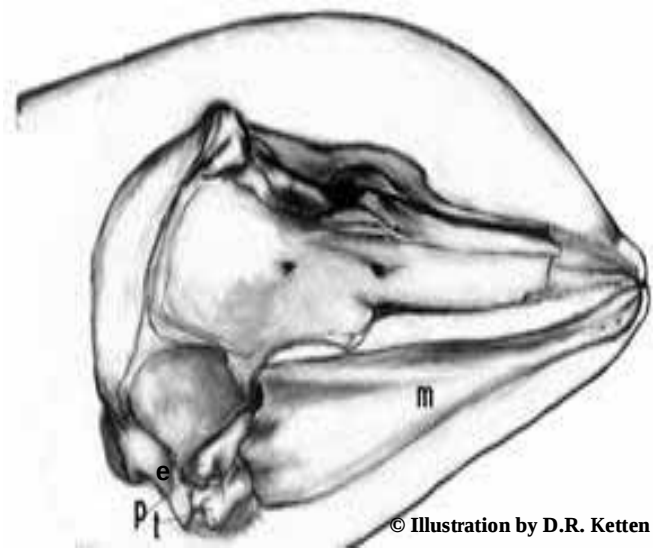

Figure 3.1c—Harbor porpoise *(Phocoena phocoena)* head showing the ear position in relation to the lower jaw (mandible). Periotic (p); Tympanic (t); Mandible (m); Exocciptial (e).

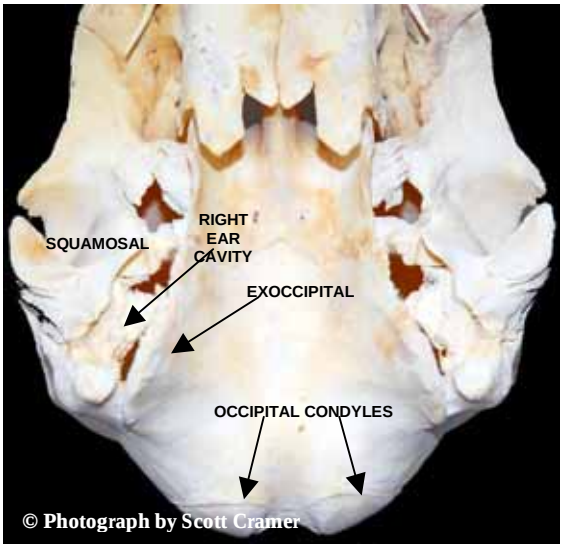

Figure 3.1d—Ventral view of a harbor porpoise *(Phocoena phocoena)* skull. Ear bones have been removed.

The ears are located just behind and deep to the lower jaw, on a line about midway between the eye and the insertion of the pectoral fin (Figures 3.1a through 3.1d). To extract the ears from a lateral approach, first make an ×-shaped incision about midway between the eye and the pectoral fin, with the midpoint of the × in line with the lower jaw. Pull the flaps back and down, cutting through the blubber and muscle. There is considerable soft tissue filling the cavity around the ear bones, and you will probably not see either the tympanic or periotic at this point. Pushing a probe straight in, you will feel a hard surface, which is the posterior section of the tympanic bone. If possible, photograph the area to document its appearance before cutting further. Then, gently cut away the tissue with a scalpel or knife until you find the tympanic bone. In a typical delphinid, the tympanic will be about 40 mm long and 25 mm wide. It resembles a conch shell, with a hollow interior that contains the middle ear bones (ossicles), a spongy soft tissue (corpus cavernosum), and the eardrum. The periotic bone contains the inner ear. It is slightly smaller and is located just dorsal and medial to the tympanic (Figure 3.2). The hyoid bones are generally attached to the posterior/lateral edge of the tympanic by a cartilaginous cap. Cut this juncture with bone shears or a scalpel.

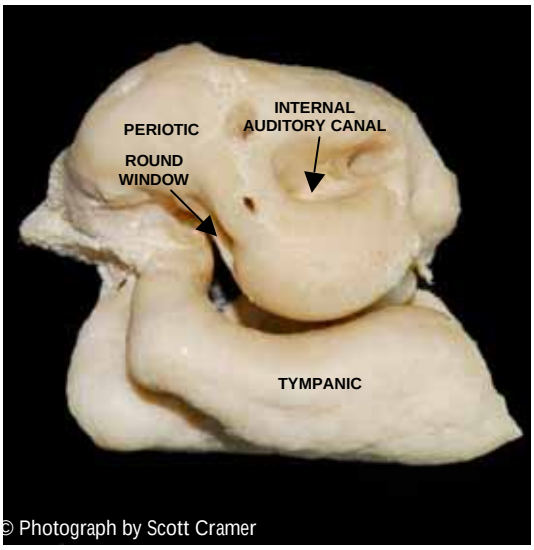

Figure 3.2a—Medial view of a delphinid left ear; tympanic, periotic, and neural canals. This ear is slightly rotated downward from the image at the right.

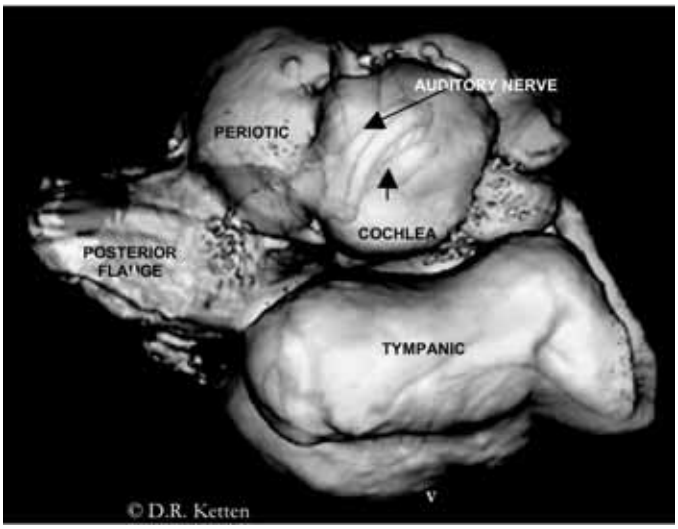

Figure 3.2b. Medial view of a 3-D reconstruction of a pygmy sperm whale *(Kogia breviceps)* right ear from CT scans. The periotic is rendered transparent to show the actual position of the cochlea and auditory nerve (VIII) in the periotic.

The tympanic and periotic are partly fused to each other at the rear edge by a semi-fused (synosteotic) joint and at the lateral edge by a curved or sigmoid process. These joints are relatively weak. Try to keep the two halves together and remove them as a unit. If the tympanic separates from the periotic during removal or is loose, be sure to extract both, and check for ossicles that may have fallen from the middle ear.

Having cleared enough tissue to identify the two bones, you will now need to cut a set of five to eight suspensory ligaments and the facial and auditory nerves located on the medial surface of the ear (Figure 3.2.). Gently rock the ear while cutting the attached soft tissue on the medial, anterior, and posterior surfaces with a narrow, sharp knife or scalpel. If the ear is difficult to move, the periotic may be attached to the skull by a short bony process or the ligaments may be calcified. This is particularly common in older animals. (*Note:* Some groups such as Ziphiids [beaked whales] and Physeterids [sperm whales] have substantial bony connections. Separate protocols are given for these ears).

Any bony attachments that are resisting removal should be cut with bone shears or pried loose with a small chisel, screwdriver,

or flat-bladed instrument. Scrape the posterior area where the periotic joins the exoccipital, and try to locate suture margins. Insert your screwdriver or chisel into these lines and gently tap it into the bone, periodically wiggling the blade to see if the flange can be levered free of the skull. Do not use a scalpel blade for this procedure; it will snap. Some soft tissue will be attached to the ear. Simply leave that in place.

Fixation and Preservation

After removal, place the ears in fixative immediately. The best fixative is 10% buffered formalin. If concentrated formaldehyde liquid or formaldehyde powder is used, mixing it with sea water in lieu of distilled water or a chemical buffer provides sufficient buffering. If formalin is not available, 70% ethanol may be used. If the specimen is very fresh, and if you are comfortable with the anatomy, it is best to inject formalin through the round window with a 22–25 gauge needle. The round window is located at the posterior/medial edge of the periotic, ventral to the stapes (Figure 3.2a). *If you are not familiar with the anatomy, please do not attempt this injection. Also, please do not inject if only large bore needles are available.* **If trauma is suspected, do not inject** at the round window; instead, insert the needle into the center of the VIIIth nerve, and slowly inject formalin. If you are injecting the round window, insert the needle in the middle of the membrane approximately 3 mm and **slowly** inject a small quantity of formalin. Be certain to record the location, needle size, and fluid quantity injected in all cases, and send with the other data for the animal's ears to the examiner.

In the field, getting the tissues into any quantity of formalin that surrounds them is acceptable; ideally, however, place the ears in a fixative volume five times that of the specimen as soon as possible. After one week, move them to half that volume, changing to fresh formalin once or twice weekly until they are well fixed. Once fixed, the soft tissues will be moderately stiff and brown and the formalin clear or light tan in color. The ears can be held for several months as they are, moved to another preservative, or shipped at this point.

Freezing is acceptable only if fluid fixation is not possible. If possible, try to obtain fixative later, and place the frozen specimens in the fixative to thaw. Do not thaw in water or in air. If the ears are frozen, do not thaw before shipping. Hold

them without thawing, and contact the receiving lab to discuss shipping methods.

SPERM WHALE (*PHYSETER MACROCEPHALUS*) EAR REMOVAL

EXTRACTION

As is most important in any necropsy procedure, document photographically the tissue condition at each major step, external to final removal. Label all images consistent with any cassette labels of tissues sampled from the region photographed. Include in the picture a label with the animal ID; indication for dorsal, ventral, anterior, and posterior directions; and a metric or other scale. Take both wide and close-up views of suspected abnormalities.

Sperm whale ears can be approached from the ventral or lateral side. Ventral approaches require the removal of the lower jaw. The ears sit in cavities below the brain case, located either side of the occipital condyles and behind a large squamosal shield (Figure 3.3). If you are taking a ventral approach, part of the ears will be visible as two large, white, egg-shaped bones (Figure 3.4).

From the side, the ears are located just behind and deep to the lower jaw, about midway between the eye and the posterior insertion of the pectoral fin (Figure 3.5)[1]. On a newborn or very young sperm whale, they are located approximately 17 cm behind the rear edge of the lower jaw on a head that is 120 cm long. The distances should be proportional on an adult

For a lateral approach, make an ×-shaped incision about midway between the eye and the pectoral fin, with the midpoint of the X in line with the lower jaw. Pull the flaps back and down, cutting through the blubber and muscle. Your incision should be just posterior to the jaw. As you probe towards the center of the head, the next bone you will come to is the squamosal, which in this species is a large, lateral wing or shelf extending from the skull. Because of this “squamosal shield”, it is easier in this species to approach the ears ventrally or to remove the head and work from the posterior face than to attempt a lateral approach.

Figure 3.3—Ventral view of an adult sperm whale (Physeter macrocephalus) skull.

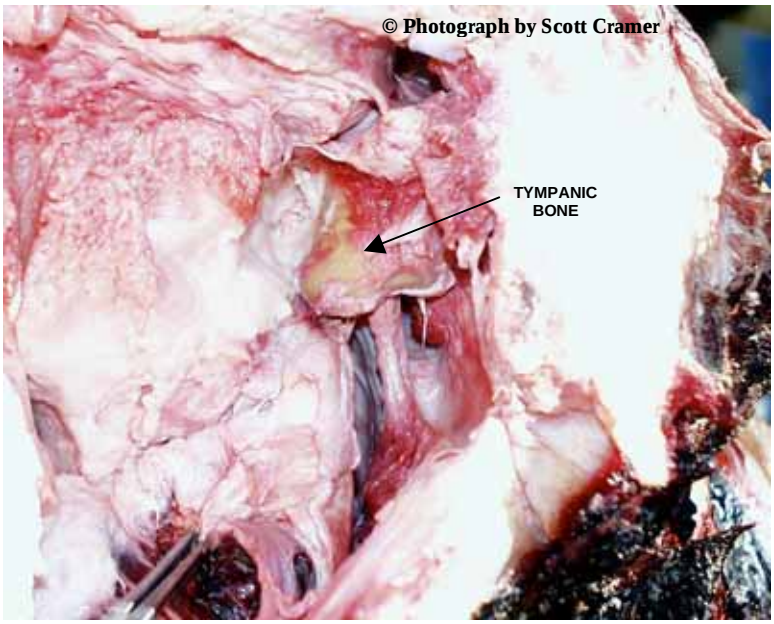

Figure 3.4—Posterior view of the right ear of a young sperm whale (Physeter macrocephalus) head**.**

Figure 3.4—Incisions for a lateral approach to remove the ear of a sperm whale *(Physeter macrocephalus)*. Photos by D. Ketten and S. Cramer

Depending upon the animal's position and the need to preserve the skull parts, you can either reach under the squamosal flange or cut through its narrow neck, which is just above the two bones (tympanic and periotic) that make up the ear. You may also cut away a block of tissue using a SawzAll or chain saw. The block should be approximately 20 cm on a side to include both ear bones, but please be certain that you have included both parts of the ear, described in the following text, in the block.

Each ear consists of two dense, joined bones that sit in the cavity below the brain case adjacent to the squamosal(s) and the

exoccipital(s). Each of the bones is about the size of a tightly closed fist (Figure 3.5).

There is considerable soft tissue surrounding the ear bones. Remove this tissue with a scalpel or knife until you find the tympanic, the lower and more ventral and lateral of the two bones.

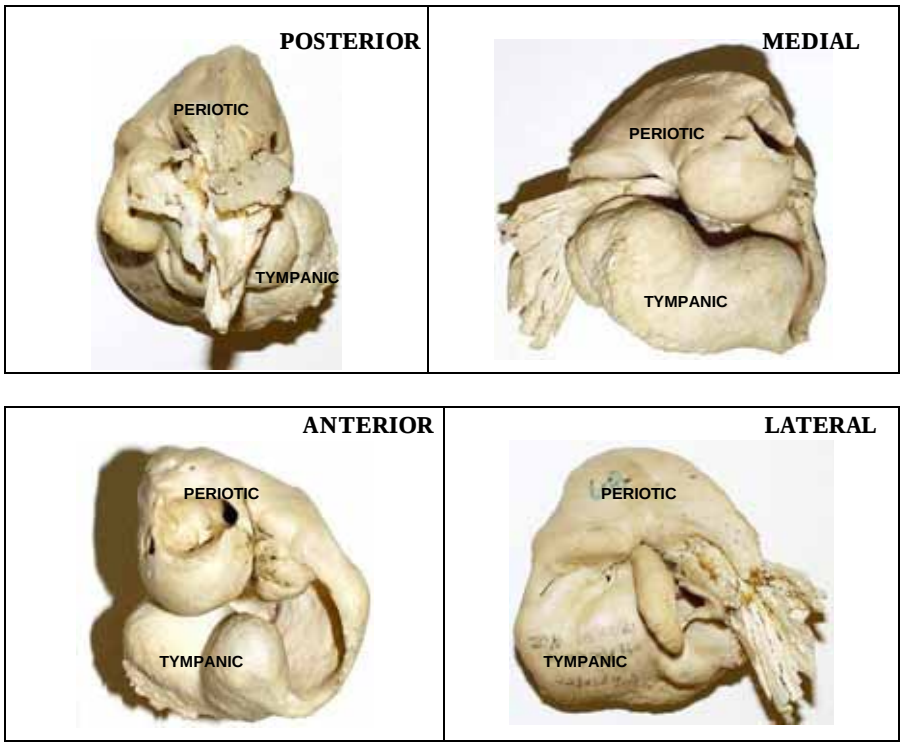

Figure 3.5—Left ear of a sperm whale *(Physeter macrocephalus)* (© Photographs by Scott Cramer)

The tympanic resembles a dense conch shell, with a hollow interior that contains the middle ear bones (ossicles), a spongy soft tissue (corpus cavernosum), and the eardrum. With the jaw removed, the ventral tympanic is readily visible. The periotic contains the inner ear and is just above and medial to the tympanic. The tympanic and periotic are fused, but the joint may be weak. Remove the ears as a unit if at all possible. If the tympanic separates from the periotic during removal or is loose, be sure to preserve the ossicles and any soft tissue from the middle ear.

Once you locate both bones, you will be able to locate five to eight ligaments as well as the auditory nerve on the medial and posterior faces of the periotic. In the sperm whale, there are also substantial flanges protruding from the posterior edge of

the periotic. The ear will likely be difficult to move, and the periotic flanges will need to be cut or levered out of the skull. Chisel any bony attachments that are resisting removal using a screwdriver, narrow chisel, or other stiff, flat-bladed instrument. Do not use a scalpel blade to pry the ear; the blade will snap, and it is difficult to remove from the ear cavity. Do not attempt to chisel into the dense periotic. Instead, probe until you find softer, spongy bone on its posterior margin. Wedge your chisel or screwdriver into this flange or into the skull at its juncture. Pry gently until the suture separates or the flange breaks. If this specimen is to be used for osteologic studies, try to maintain the flange.

Once the ear bones can be moved, try to locate the ligaments and nerves retrobullar (behind and medial to the ear bones). Cut these with a sharp knife or scalpel. Grasping the two ear parts, rock the ears gently until they can be cut. Do not pull soft tissue to free them or they may evulse the nerve (i.e., rip the nerve out of the ear).

Fixation and Preservation

After removal, place the ears in fixative immediately. The best fixative is 10% buffered formalin. If concentrated formaldehyde liquid or formaldehyde powder is used, mixing it with sea water in lieu of distilled water or a chemical buffer provides sufficient buffering. If formalin is not available, 70% ethanol may be used. If the specimen is very fresh, and if you are comfortable with the anatomy, it is best to inject formalin through the round window with a 22–25 gauge needle. The round window is located at the posterior/medial edge of the periotic, ventral to the stapes (Figure 3.2a). *If you are not familiar with the anatomy, please do not attempt this injection.* Also, please do *not* inject if only large bore needles are available. **If trauma is suspected, do not inject** at the round window; instead, insert the needle into the center of the VIIIth nerve and slowly inject formalin. If you are injecting the round window, insert the needle in the middle of the membrane approximately 3 mm and **slowly** inject a small quantity of formalin. Be certain to record the location, needle size, and fluid quantity injected in all cases and send with the other data for the animal's ears to the examiner.

In the field, getting the tissues into any quantity of formalin that surrounds them is acceptable, but, ideally, place the ears in a

fixative volume five times that of the specimen as soon as possible. After one week, move them to half that volume changing to fresh formalin once or twice weekly until they are well fixed. Once fixed, the soft tissues will be moderately stiff and brown and the formalin clear or light tan in color. The ears can be held for several months as they are, moved to another preservative, or shipped at this point.

Freezing is acceptable only if fluid fixation is not possible. If possible, try to obtain fixative later, and place the frozen specimens in the fixative to thaw. Do not thaw in water or in air. If the ears are frozen, do not thaw before shipping. Hold them without thawing, and contact the receiving lab to discuss shipping methods.

EXTRACTION

Documenting the procedures and tissue condition as you proceed with ear extraction is crucial. Photograph the area you are working on before and after each stage of the procedures, being sure to add a scale and a marker indicating any abnormal area. Take wide-area and close-up shots of such areas. Label areas on the photograph consistent with the labeling of tissues subsampled from each area.

Approach beaked whale ears from the side of the animal, or ventrally, if the lower jaw has been removed. Each ear consists of two joined, dense bones—one hollow (tympanic) and one spherical (periotic)—that sit in the cavity lateral to the brain case and are bordered by the squamosal laterally and the exoccipital posteriorly (Figure 3.6 and Figure 3.7).

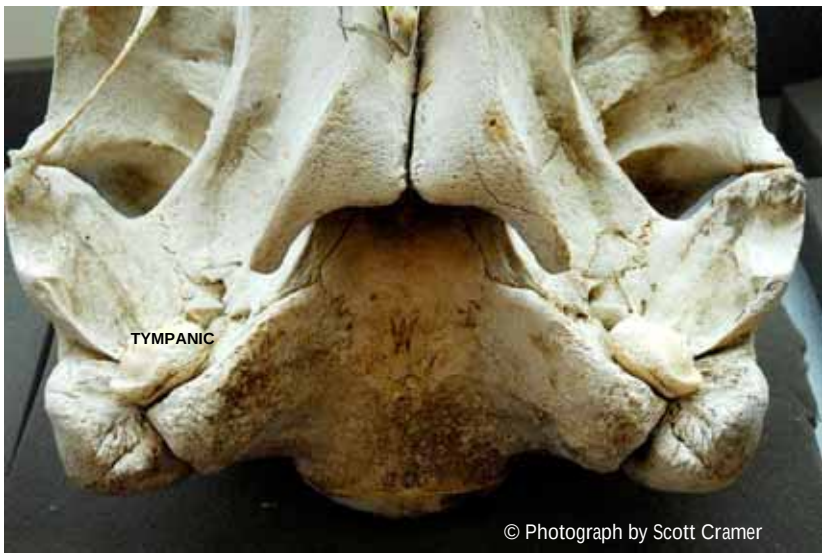

Figure 3.6—Ventral aspect of a Cuvier's beaked whale *(Ziphius cavirostris)* skull. The tympanic bones are ovoid. The periotics are not visible in this photograph and are located dorsal and medial to the tympanic bones.

Figure 3.7—Left ear of a Cuvier's beaked whale *(Ziphius cavirostris)*

The ears are located just behind and deep to the posterior edge of the lower jaw. To extract the ears using a lateral approach, locate by palpation the posterior edge of the jaw. Make an ×-shaped incision about mid-way between the eye and the pectoral fin, with the midpoint of the × in line with the jaw (Figure 3.8)[2].



Figure 3.8—Incision location for a lateral ear extraction (Photo by S. Cramer)

Bend the tissue flaps back and down. Probe straight in from the center of your incision until you feel a hard surface. That is the tympanic bone of the ear.

There is considerable soft tissue filling the cavity around the ear bones. Gently cut away the tissue with a scalpel or knife until you expose the tympanic. In a typical ziphiid, the tympanic will

be approximately 40–50 mm long and 30 mm wide. It resembles a conch shell, with a hollow interior that contains the middle ear bones (ossicles), a spongy soft tissue (corpus cavernosum), and the eardrum. The periotic bone, which contains the inner ear, is slightly smaller and is dorsal and medial to the tympanic. One of the hyoid bones generally attaches to the posterior/lateral edge of the tympanic by a cartilaginous cap. Cut this juncture with bone shears or a scalpel. On beaked whales, there is also a thick slice of bone loosely attached to the anterior margin of the tympanic.

The tympanic and periotic are partly fused to each other at the rear edge by a semifused (synosteotic) joint and at the lateral edge by a curved or sigmoid process, but the joints may be weak. Try to extract tympanic and periotic as a unit. If the tympanic separates from the periotic during removal or is loose, please be sure to extract both bones and be certain to get any ossicles that may have fallen from the middle ear.

Having cleared enough tissue to identify the two bones, you will need to free them by cutting or levering a posterior flange attached to the skull. Try to move the ear bones, looking for motion in the sutures of the skull posterior to the ear. It may help to scrape the soft tissue from the skull in this area. Place a chisel or flat-bladed screwdriver in these sutures and gently pound the wedge in with a hammer or mallet until you can lever the periotic and tympanic out of their cavity with an approximately 2 cm chunk of softer skull material attached at the posterior edge. You will now cut five to eight suspensory ligaments and the facial and auditory nerves located on the medial surface of the ear. Gently, rock the ear while cutting the attached soft tissue on the medial, anterior, and posterior surfaces with a narrow, sharp knife or scalpel. This is the most difficult part because it is not easy to cut the tissues blindly. A narrow or curved scalpel helps. Any attachments that are resisting removal should be cut with bone shears or pried loose with a small chisel, screwdriver, or flat-bladed instrument. Do not use a scalpel blade for this procedure; it will snap. Leave any soft tissue attached to the ear.

Fixation and Preservation

After removal, place the ears in fixative immediately. The best fixative is 10% buffered formalin. If concentrated formaldehyde

liquid or formaldehyde powder is used, mixing it with sea water in lieu of distilled water or a chemical buffer provides sufficient buffering. If formalin is not available, 70% ethanol may be used. If the specimen is very fresh, and if you are comfortable with the anatomy, it is best to inject formalin through the round window with a 22–25 gauge needle. The round window is located at the posterior/medial edge of the periotic, ventral to the stapes (Figure 3.2a). *If you are not familiar with the anatomy, please do not attempt this injection.* Also, please do *not* inject if only large bore needles are available. **If trauma is suspected, do not inject** at the round window; instead, insert the needle into the center of the VIIIth nerve and slowly inject formalin. If you are injecting at the round window, insert the needle in the middle of the membrane approximately 3 mm and **slowly** inject a small quantity of formalin. Be certain to record the location, needle size, and fluid quantity injected in all cases and send with the other data for the animal's ears to the examiner.

In the field, getting the tissues into any quantity of formalin that surrounds them is acceptable; ideally, however, place the ears in a fixative volume five times that of the specimen as soon as possible. After one week, move them to half that volume changing to fresh formalin once or twice weekly until they are well-fixed. Once fixed, the soft tissues will be moderately stiff and brown and the formalin clear or light tan in color. The ears can be held for several months as they are, moved to another preservative, or shipped at this point.

Freezing is acceptable only if fluid fixation is not possible. If possible, try to obtain fixative later, and place the frozen specimens in the fixative to thaw. Do not thaw in water or in air. If the ears are frozen, do not thaw before shipping. Hold them without thawing, and contact the receiving lab to discuss shipping methods.

SHIPPING

Once the specimen appears well-fixed, call the lab receiving the specimen to confirm that you are ready to ship and the day for shipment. If shipping to this lab (Woods Hole Oceanographic Institute), contact us by phone first at the numbers listed below.

On the day of shipping, wrap the specimen in several layers of formalin-soaked gauze and place in three or more sealed plastic bags with an absorbent material such as diapers inside each bag

to prevent leakage. If you use a jar, seal the jar with wax or waterproof tape, and place it in a sealed plastic bag. Do not use glass containers. The important point is to preserve moisture around the ears without a large fluid volume and to have several leak-proof seals. Place the packaged samples inside a cooler or reinforced box. The shipping container should be capable of withstanding a drop of at least three feet without damage.

Within the United States, ship by Federal Express or other expedited service for one- or two-day delivery. If sending from overseas, please use a method that will deliver within seven days. You will also need to confirm with us any permit numbers that are required for domestic or international shipping for some species. Check with your shipper that formalin fixed, nonliquid samples are allowable and considered nonhazardous. If so, mark the container: Scientific Specimen—No Medical Hazard—Deliver Immediately.

COMMENTS OR QUESTIONS ON EXTRACTION PROCEDURES

We welcome your comments on this manual and will be happy to answer additional questions.

Contacts—For further questions please contact the following:	
Dr. Darlene Ketten or Scott Cramer Laboratory: 508-289-3582 Office: 508-289-2731 or 508-289-2832 Mobile: 774-836-5012 Fax: 508-457-2041 Email: dketten@whoi.edu scramer@whoi.edu	Biology Department Woods Hole Oceanographic Institution 266 Woods Hole Road MS #50 Woods Hole, MA 02543 USA

Chapter 4—
Imaging Procedure for Stranded Marine Mammals

Eric W. Montie[1]
Darlene R. Ketten[1, 2]

[1]Biology Department
Woods Hole Oceanographic Institution
Woods Hole, Massachusetts

[2]Department of Otology and Laryngology
Harvard Medical School

June 2007

INTRODUCTION

This section provides an introduction to biomedical imaging techniques and guidelines for diagnostic imaging of marine mammals to assist with both live examination and necropsy procedures. The procedures described are based on imaging equipment and techniques relatively common in human and veterinary facilities; thus, the procedures will provide the majority of stranding-response groups with the most likely options to assist their efforts. The imaging techniques described include basic radiography, computed tomography (CT), and magnetic resonance imaging (MRI); these techniques are applicable to both live and postmortem cases.

Special emphasis has been placed on whole-body–, airway-, head-, and ear-imaging procedures. Subsections cover basic information on the following:

- Basic principles and appropriate applications for radiography versus CT versus MRI;
- Handling and preparation of live and dead animals in clinical settings; and
- Image and data formats that may be encountered.

The protocols are also listed in outline form to provide a rapid overview. The introductory discussion of principles behind techniques is not required to employ the protocols, but does provide additional information that can aid in deciding which techniques are most efficacious as well as the limitations for interpretation of imaging data. Examples of some pathologies imaged with these procedures are also provided.

BIOMEDICAL IMAGING—AN INTRODUCTION TO TECHNIQUES

RADIOGRAPHY

Plain-film radiographs, commonly called ×-rays, are the most common noninvasive imaging method used by physicians and veterinarians. Most veterinary clinics and some stranding networks will have ×-ray machines. The equipment for plain films is relatively inexpensive and broadly available, and the exams are relatively rapid. Depending on the size of the animal

versus the tissue type and pathology present, plain-film ×-rays may be sufficient for diagnosing some conditions, including fractures, hemorrhages, tumors, and foreign object. They are particularly useful for determining the presence of any metallic objects; thus, they may be an important rapid-screening device to use prior to attempting MRI on any animal.

Radiographs are essentially a shadow picture obtained by exposing a photosensitive film with ×-ray energy that has passed through an object or animal. Differences in the density of the tissues or objects in the animal being imaged determine how much of the ×-ray beam will be attenuated or passed through to the film. The denser a structure is, the fewer ×-rays that pass through it. These differences are encoded as grades of exposure ranging from black (e.g., air and therefore full pass of ×-ray energy, fully exposed film) to white (fully attenuated or absorbed ×-rays). Areas of very low density such as normal, air-filled lungs will be dark gray to black with mottlings of dark to light gray where there are thicker alveolar walls, bronchioles, etc. The cartilage and soft tissue areas of the trachea will be a lighter gray, and all of it will be overshadowed by the brighter, white bone of the ribs. Very dense objects such as bones, teeth, calcium deposits in tumors, and plastic or metallic foreign bodies absorb or reflect the ×-ray beam and appear bright white. Muscles and organs (heart, liver, and spleen) are shades of grey.

In a plain film or radiograph, we are actually looking at a two-dimensional (2-D) composite of all the overlying tissue. Therefore, ×-rays can be difficult to interpret because of the multiple layers of tissues, especially if the animal is very large or if the tissues to be visualized are surrounded by several denser or complex structures. In most cases, on simple radiographs, pathologies are observed as inappropriate darker areas if there is a collection of fluid (henatoma), an air pocket (pneumothorax or emphysema), or bone separation (fractures); they may also appear as denser and whiter areas, sometimes called “clouding,” as in the case of advanced pneumonia, consolidated lungs, fibrous tissues, or inflammatory regions. Resolution of a plain film depends on balancing many factors. The most important are voltages used and length of exposure which determines radiation received. These may be increased or decreased depending on the mass of the animal, the depth and type of tissue that must be imaged, the density of tissues overlying the

target areas, and other technical factors such as screens used, film cassette types, and emulsion quality. The latter can help reduce ×-ray beam scatter and improve definition. All of these factors should be discussed with the technician or radiologist conducting the exam in order to determine how to obtain the best images in the shortest time for the animal and the pathology being investigated.

COMPUTED TOMOGRAPHY

Computed tomography refers to the production of sectional images of an animal or specimen. Tomography derives from the Greek *tomos* meaning slice as opposed to *topos* meaning surface (Figure 4.1). Computerized refers, of course, to the use of computers rather than film to acquire the data and reconstruct it as images of sections of the body.

Sectional imaging is analogous to slicing a loaf of bread and acquiring an image of whatever is in each slice. In standard ×-rays, the entire loaf would be visible with all internal structures as overlapping shadows. In one sense, a CT image is a tomogram, and a plain film or standard ×-ray is a topogram. In comparison to plain film ×-rays, tomograms provide far greater detail but they are more time-consuming and generally more expensive. Sectional CT images amount to a digital dissection, allowing us to view internal structures within individual sections in far greater detail because we do not have the interference of the surrounding tissues. However, sectional CT images require somewhat longer examination times and may involve more exposure to ×-rays or use of tranquilizers than do plain films. Most hospitals and an increasing number of veterinary facilities have one or more tomographic machines.

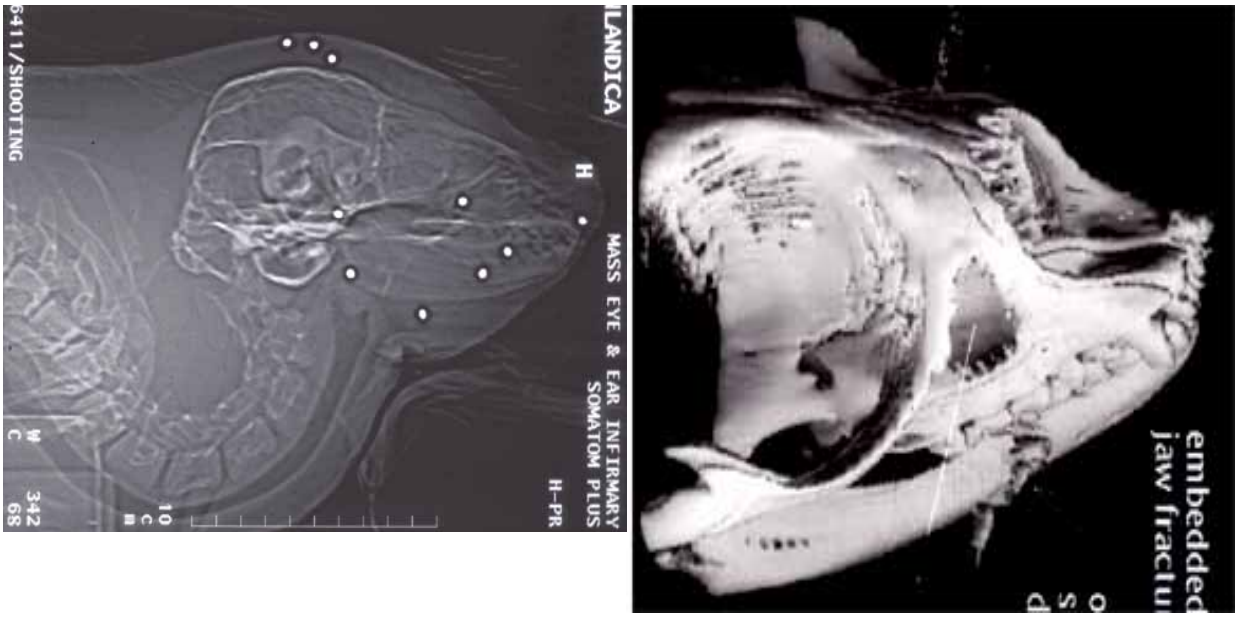

Figure 4.1. A CT topogram or scout image (left), which is similar to a plain film, of a live seal that had been shot in the head, showing multiple metal fragments. On the right is a three-dimensional (3-D) reconstruction from the CT images of the animal demonstrating the extent and pattern of the fractures that resulted in relation to the fragments.

The two most common forms of sectional imaging are based on ×-ray and on magnetic resonance techniques. Technically, the term "computed tomography" applies to both, but the phrase and its abbreviation, CT, are most often used to mean sectional imaging from ×-rays; magnetic resonance or nuclear magnetic resonance imaging is called MRI or NMR. These two techniques are complementary. CT can image soft and hard tissues, but is especially well-suited for any exams requiring information on bones, foreign objects, or air filled spaces. MRI provides superior images for soft tissues; however, because the technique depends upon having hydrated tissues, it cannot accurately represent bony or heavily aerated tissues, and because it employs shifting magnetic fields, it is precluded from use in any animal that may have any metal fragments.

CT: ×-RAY COMPUTERIZED TOMOGRAPHY

Particular indications for CT imaging include pathologies that involve any form of bone lesion, aerated tissues, and mixed bone and soft tissue evaluations(e.g., trauma cases; intracranial hemorrhage; fracture evaluation; dislocations of any bony structures; foreign bodies; and diagnosis of primary and secondary neoplasms of the liver, kidney, brain, lung, bone; and tumor staging).

As noted previously, as with plain films, CT images are based on ×-ray attenuation, but the image data is acquired by means of an array of detectors linked to a computer rather than by film. A computer-controlled table (gurney) moves the patient through a doughnut-shaped opening in the housing (gantry) that contains the ×-ray tube. As the tube rotates along the arch of the housing and the table moves through the gantry, pulses of ×-rays are emitted at multiple positions and recorded at the detectors beneath the patient.

A grid or collimator overlying the detectors assists in reducing the recoding of scattered beams. Analogous to the process in plain films, the resolution of the digital images produced is based on a complex combination of the kilovoltage (kV), exposure time, number of pulses, collimators, detectors, and table speed. In addition, modern scanners have two basic modes: single slice and spiral. In the former, the table moves in increments from 1 mm to 10 mm, and images are produced at matching thicknesses with one travers of the tube per slice. In the spiral mode, the table moves at rates of 0.5 mm to 10 mm per second, with the tube moving and the data being collected continuously. This method is far more rapid and allows slice reconstruction at thicknesses from 0.1 mm to 10 mm from one data set.

Both forms of acquisition can also be used for imaging soft or hard tissues. “Acquisition kernel” is the term used to refer to the reconstruction algorithm that is used to transform the attenuation values into gray-scale values. The kernel used will provide an optimal gray-scale distribution for detail of different tissue types. Thus, there are many components that go into the exact protocol used for any exam: spiral or single slice exposures, table speed, kV, level of detail needed, tissue type to be imaged, time the animal can be on the table, body area to be examined (e.g., head or whole chest or abdomen). For example, for CT imaging of the thorax and abdomen, a protocol using a 10-mm slice thickness and soft tissue kernels is common because these structures are large. Lung scans use a 3 mm and specialized protocol to emphasize fine differences in the aerated passages; exams of the middle and inner ear use an even smaller slice protocol of 0.5 mm acquisitions with 0.1 mm image reconstruction and high-resolution bone kernels. Some of these numbers will vary according to manufacturer of the scanner; in most facilities, however, at least some spiral imaging will be available, and in all CT facilities, bone and soft tissue kernels for

most organ types are available. In addition, CT images can now be reconstructed at virtually any angle required even though they are acquired in all cases in a standard transaxial plane.

As in a standard radiograph, the CT images are shown as grades of gray that relate to the amount of ×-ray beam that was attenuated by tissues of the specimen. Attenuation is affected by many factors, but is largely determined by density of the exposed tissues. In the images, the higher the attenuation, the denser the object, and the whiter the appearance of the structure. In addition to the 256 gray scale used to tint each pixel, a second value—the Hounsfield units (HU)—is also available from the CT data. Hounsfield, named after one of the inventors of CT methodology, is a measure of attenuation standardized to water. Air is therefore –1000 HU; water is 0. Higher numbers indicate increasing density. Mammalian tissues typically range between –100 (fats) to +3100 (very dense bone), but even metals can be measured up to approximately 41000 HU on an extended scale. Hounsfield units therefore offer a far greater range of information about the density of and physical characteristics on a per-pixel basis than does the 256 gray scale used for imaging alone. Hounsfield units are especially useful in diagnosing hypermineralization, the quality or age of a blood deposit (clots are denser and have higher HU values than fresh, fluid blood), etc.

This brings us to a rather technical area about how images are formed using kernels and look-up tables. It is not necessary to understand these fully, but it is important to be aware of them. The attenuation values or coefficients are the raw data of the CT scan. These values are processed into image files by applying a convolution algorithm, which briefly amounts to combining multiple values that are obtained from each ×-ray projection, weighting them according to the tissue characteristics that are of interest, and then providing a third output that results after this "filtering" has been applied. At the user interface, this operation amounts to choosing first a protocol that weights the data for better definition of bone compared to soft tissues and then adding a second weighting that emphasizes a range of Hounsfield values, commonly called "windows" and "centers."

Therefore, for any scan session, you must indicate to the technician whether you need primarily images of the soft tissue or of the bony structures or of both. Applying the proper kernel

is particularly important if you are planning to make measurements of tissue dimensions. Reformats of any CT data set must be done from the raw data set for accurate information. Reformats should not be from the image files, because these are already set by the kernel previously chosen; although the appearance may change, the representation of the anatomy may be distorted. In most facilities, only the image files are archived because the raw data files are large and time-consuming to copy. It is important, however, to archive both raw data and the basic image files whenever possible, especially if the animal is rare, has an unusual condition, is a legal case, or the reformats for other tissue types may be needed later.

Contrast agents may be employed in live cases by injecting an agent that is radio-opaque and that assists with tracking fluid accumulations or flow rates. These are most commonly used to determine presence of tumors or for cardiac assessments. Contrast agents require veterinary oversight; although reactions are rare in nonhumans, precautions to treat a reaction should be in place before the agents are administered.

CT Summary

In general, CT provides very high-resolution imaging in a relatively short time frame. It is the primary choice for live animals that require quick exams, and it provides the best images for diagnoses of bone, airway, or foreign-body pathologies.

Tranquilization may be required, but for very short spiral CT exams, it may be sufficient to simply restrain the animal or in, the case of a captive animal, to train it to hold a position for five minutes or less. The procedure requires exposure to ×-rays, but, for most exams, this does not represent a significant increase over plain film procedures. CT exams are limited to animals weighing less than 250 kg, less than 1.7 m long, and less than 70 cm in diameter. Some larger gantry machines that accommodate greater weights are available but are rare.

Because CT scanners are generally located in clinical settings, proper precautions for both live and postmortem specimens are required to prevent contamination, as described in the subsequent outlines. The first scan will be a “topogram” or “scout” of the whole animal or specimen (Figure 4.1). This image resembles a regular ×-ray and is used to determine the regions of the animal that will be examined. Following the scout

and the designation of scan sequences, the raw data for generating section images are acquired by either spiral or single section scan sets. The typical whole-body exam will require approximately 20 minutes of table time to acquire the data, at which point the animal can be removed from the scanner. Image reconstruction typically may require 30 minutes to two hours to obtain complete sets of all image sets depending on the number of types of tissues and reconstructions required. Both 2-D and 3-D images are possible, as are multi-tissue displays and measurements of significant features. Bone- or soft-tissue kernels or both should be used as appropriate for each case rather than attempting to convert one series to the other by re-windowing from just the image files. Contrast agents may assist with diagnosis of hemorrhage, tumors, or heart conditions, but they require careful administration under veterinary supervision. Images are generally exportable as hard-copy films or digital DICOM (digital imaging and communications in medicine) format images (described in subsequent text) on CD or other electronic medium.

MRI: Magnetic Resonance Imaging

Magnetic resonance imaging (MRI) is another increasingly available method for sectional anatomy imaging and is extremely valuable for many soft-tissue exams. The strength of MRI is the ability to detect differences in soft tissue; radiography and CT, which provide excellent examinations of bone and air-filled spaces, provides less resolution than MRI for most soft tissues. For example, MRI is an excellent tool to view the brain and gastro-intestinal or reproductive systems, because it provides good resolution of subtle differences in soft-tissue hydration such as between white matter and grey matter. On the other hand, magnetic resonance cannot be used to image most bony structures or highly pneumatized areas. It also is precluded for subjects that have any metal in or on them; plus, because of longer imaging times, generally MRI will require tranquilizers or anesthesia for most veterinary cases.

Magnetic resonance (MR) images are acquired by generating a magnetic field across the subject. Hydrogen nuclei (protons) present in the tissue align with this field. Pulses of radio waves are then broadcast into the sample, energizing the hydrogen protons, causing them to resonate and deflect away from the magnetic field. Once the radio pulse stops, the protons decay (i.e., return, or “relax”) to their original alignment. A receiver

coil detects the number of resonating protons and the changes in their spin, which is then translated into a signal-intensity value. Tissues with high levels of fluids (e.g., blood, cerebrospinal fluid) have high proton content and produce high signal intensities; those with low fluid content (e.g., lungs or dense bone) produce low signal intensities.

Analogous to the process of converting ×-ray attenuations in CT, the MR signal intensities are transformed by a convolution process also into gray scales for imaging. High-intensity, high-fluid content areas are generally imaged as bright white while lower fluid-content structures are in graded shades of gray. Bone and air have virtually no fluid content; therefore they produce little or no signal and are both black. These parameters can be adjusted, however, to preferentially enhance imaging of some tissue types. Typically, two types of images can be produced, depending on what stage of decay is being measured (i.e., how long after the radio pulse transmission is stopped): T1-weighted images are taken early in the decay process, while T2-weighted images are taken later (shorter and longer relaxation times). T1 images, which have greater resolution, are most useful for examining anatomic detail. By comparison, T2-weighted images have greater contrast and are most useful in diagnosing gross pathologies such as cysts or some tumors because these pathologies typically contain relatively large amounts of water, which results in high signal intensities that appear bright white.

As with CT, MR images are usually provided in sections in coronal, sagittal and axial planes, and at 1–10 mm thicknesses. The absolute level of resolution depends partly on the number of signal sequences that are employed and, therefore, on the total time required for the exam. The more pulse sequences measured and compared, the higher the resolution and the longer the exam for each case study. The average head or abdominal MRI exam will usually require about 30–45 minutes of table time and have a resolution of 2–8 mm per pixel. Resolutions of less than 2 mm will normally require upwards of one hour of signal acquisitions and are therefore practical generally for postmortem cases.

As with the kernels in CT, most MRI units have multiple sequence modes that can be employed, and this should be discussed with the technician prior to the start of the exam. In addition to the T1 and T2 sequences described previously, some

of the more commonly available protocols include Constructive Imaging via Steady State (CISS) and fat-suppressions as well as some newer techniques for viewing lungs or cardiac functions.

Contrast agents are also available for use in MRI; as with CT agents, they should be employed only with veterinary approval and oversight, and precautions to treat a reaction should be in place before the agents are administered.

MRI Summary

MRI provides exceptional soft-tissue imaging but requires longer table time for most exams than does CT. It is the primary choice for animals or specimens that requires good soft-tissue differentiation; MRI provides the best images for diagnoses of brain and abdominal soft-tissue pathologies.

Tranquilization is likely to be required in all live cases. Size limitations depend on the unit and on whether a body, head, or surface coil will be used. In general, animals must weigh less than 200 kg, and the exam area must be less than 1 m long and less than 55 cm in diameter.

Because these units are generally located in clinical settings, proper precautions for both live and postmortem specimens are required to prevent contamination, as described in the outlines that follow. As with CT, MRI requires a scout acquisition to determine orientation and regions to be imaged. Following this process, the full MR sequences are applied. The typical whole body exam will require approximately 40 minutes of table time for each sequence or mode chosen and 30 minutes to two hours for obtaining complete sets of images, depending on the number of types of tissues and reconstructions required. Both 2-D and 3-D images are possible. Contrast agents may assist with diagnosis of hemorrhage, tumors, or heart conditions, but require careful administration under veterinary supervision. Images are generally exportable as hard-copy films or digital DICOM format images (described subsequently) on compact disc (CD) or other electronic medium.

PRACTICAL GUIDELINES

CHOOSING THE RIGHT IMAGING MODALITY

There are numerous factors to consider when determining which imaging technique(s) to use for a stranded marine mammal. These include equipment availability, amount of time available, size of the animal, specimen condition, and suspected pathology type. Following are guidelines for each modality and procedures for preparing the animal or specimen. It should be noted that the times listed do not include specimen preparation or positioning prior to scanning. Dimension and weight tolerances vary by scanner manufacturer; those listed are typical for most recent units. For postmortem material, limits include all containers, packaging, and fluids surrounding the specimen when scanned.

Procedural Outlines and Size Limits

Species size categories employed in the protocols below assume the following limits:

- Small

  Weight < 250 kg
  Maximum diameter < 58 cm
  Maximum girth < 80
- Medium

  Weight < 400 lb
  Maximum height < 70 cm
  Maximum girth > 80 cm
- Large
  - Weight >400 lb
  - Maximum height >70 cm
  - Maximum girth >80 cm

Plain Film x-rays

- Time required: Seconds per exposure for each x-ray
- Size restriction: NONE
- Weight: No weight limits; resolution decreases with body mass in the field of view
- Specimen condition

  - Live
  - Fresh dead
  - Moderate to advanced decomposition
- Particular applications
  - Fractures
  - Hemorrhages
  - Pneumothorax
  - Tumors
  - Foreign bodies, especially metallic objects
  - Prescreening for MRI

CT

- Time required: 0.5 to 10 minutes, depending on body region examined
- Size restrictions: small to medium species for whole animals or parts of small, medium, and large species that fit within the following limits
  - Weight: <250 kg
  - Maximum dimension: <70 cm (diameter)
  - Maximum length: 1.7 m
- Specimen condition
  - Live
  - Fresh dead
  - Moderate to advanced decomposition
- Particular applications
  - Trauma
  - Gunshot wound
  - Fractures
  - Middle and inner ear pathology
  - Skull and spinal column pathology
  - Osteolytic disease
  - Joint pathology
  - Air emboli
  - Foreign bodies
  - Abdominal organ injury
  - Hemorrhage
  - Tumors

MRI

- Time required: 15–45 minutes per scan
- Size restrictions: small species for whole animals or parts of small, medium, and large species that fit within the following limits
  - Weight: <200 kg
  - Maximum dimensions
  - Head coil: 80 cm circumference (girth) or ~20 cm diameter
  - Tunnel opening: 58 cm diameter
  - Maximum length: 1 m
- Specimen condition
  - Live
  - Fresh dead
- Particular applications
  - Trauma
  - Neurological symptoms (aberrant behavior, seizures, tremors, circling)
  - Soft tissue damage
  - Brain lesions
  - Hemorrhage
  - Tumors
  - Circulatory system function
  - Cysts

BIOMEDICAL IMAGING PROCEDURES FOR STRANDED ANIMALS

Applicable imaging approaches differ depending on many factors, including whether the animal is alive or dead, whether sedation is feasible, the specimen size and weight, and the available imaging options. As outlined previously, both CT and MRI have weight and aperture limits that may vary by manufacturer but, in general, limit the exams to small to mid-sized cetaceans and pinnipeds or to postmortem exams of parts of larger animals

If all imaging options are available and there is time, the optimal scenario would be to perform a screening radiograph of the head and body of most specimens and then pursue CT or MRI scans

of the body and head for high-resolution imaging of any areas of interest. The following recommendations therefore provide procedures for screening with plain films followed by CT and MRI. If CT is available, the plain films may be eliminated. If MRI is available, either plain films or CT should be used first to screen the specimen or animal to be certain no metallic components are present in the gut or embedded in any tissues.

We recommend employing CT rather than MRI for full-body scanning because MR imaging of the whole body requires extensive table time and has imaging length limits that make it impractical for all but the smallest postmortem specimens. It also will not provide adequate resolution of many structures in the head, thorax, or abdomen (e.g., ears, lungs or other bony or gas-filled regions) that are important for assessing strandings. When possible, we do recommend performing MRI of the head, because this modality provides the best resolution of the brain.

Prior to the examination, it is advised that you contact the facility, inform them of the species, size category, and exact gross condition of the animal. Basic details they will require are live or dead, intact or with external trauma, and, if dead, the state of decomposition. Handling for each of the stages in postmortems is discussed in following text.

ANIMAL OR SPECIMEN PREPARATION:

All Live Animals

Transport Preparations

a. Document the condition of the animal with photographs and notes.

b. Clean animal to the extent feasible to remove superficial sand and mud because the minerals in these particles create image artifacts and may cause injury in MRI exams. It is advisable to photograph again after cleaning and prior to transport.

c. Transport to radiography facility.

NOTE: Photography, in the radiography facility, of the procedure is also recommended however, ***it is imperative to get permission from any clinical facility, particularly a human radiology unit, before any photography is done.*** *Although most facilities will allow photographs, they may be understandably limited or forbidden for reasons of protecting patient privacy.*

Any carrier normally used for animal transport is acceptable, but care should be taken to consider the animal's health and that of other patients in the facility. It is recommended that an arrival time be agreed upon; and, if it is a clinical facility, that entrance location and access to a transport gurney or cart be arranged in advance. It may also be advisable to alert the security services in larger hospitals in order to arrange parking for any large transport vehicles.

d. Prepare the animal for placement on the imaging table and for examination.

Anesthetize or tranquilize the animal based on best veterinary practice, anticipating up to 10 minutes of sedation needed for handling for plain films and 30 minutes minimum for one CT or MRI procedure. During the exam, an attendant or veterinarian should be in the room and wearing proper shielding for CT or MRI during the exam in order to observe the condition of the sedated animal and to notify the scanner technician of any movement by the animal while scanning is in progress.

All Postmortem Animals and Extracted Tissue Preparation:

Most of the preparation of postmortem material is the same as for live animals described previously, with the exception, of course, of sedation and the added need for proper sealed containers for any decomposing material.

Chilling, Freezing, Fixation

Preparation and scanning of the animal or tissues should be done as soon as possible postmortem or postextraction, preferably without the need to hold for more than a few hours.

In most cases, there will not be a preparation area connected to the scanner facility; therefore, preparation will need to be done on the beach or in the necropsy facility.

All bodies should be cooled as soon as possible. If several hours' holding are required, it is reasonable to consider placing dry ice, if available, in the mouth cavity and blowhole to cool the brain and in the rectum to chill the abdominal area. The body may also have ice packs or cold packs applied to the abdomen and head regions.

If the animal or tissues must be held longer, they should be packaged (described in the next section) in a container with as little air surrounding the specimen as possible and placed in a chiller at approximately +4 degrees C. If a chiller is not available, the bagged animal can be placed in a vat of ice or in a second bag with ice between the layers. To prevent artifactual water deposits or bloating and dilution by osmotic processes, the unpackaged animal should not be immersed directly into water or an ice bath. Animals may be held in a chiller for several days if necessary. If chilling is not possible, freezing is a reasonable alternative but can create artifacts. As with chilling, the animal should be sealed in a bag with little air surrounding it and placed in the freezer by suspending or on cushioning to avoid compression of major organs during the chilling and freezing process. If frozen, the animal may be ×-rayed or CT-scanned without thawing. However, because MRI depends upon fluid molecular mobility, all material must be fully thawed before MRI scanning.

Formalin or other fixative materials should be handled with the usual procedures for fixation and then packaged with the same precautions against leakage or contamination as outlined subsequently. The imaging facilities should also be contacted to ascertain if they have any regulations related to fixatives. Above all, care should be taken to prevent leaks or fumes. Small specimens can generally be scanned in their fixative in all modalities and may not require removal from containers.

Packaging and Transport Preparations

a. Photo-document and clean the animal (see live in earlier text) to the extent feasible to remove superficial sand, sediments, and mud

b. Package the animal or specimen and transport to the imaging facility

Proper packaging to prevent odor or fluid leaks during transport and imaging is the most important step in this process. Fortunately, most animals can be placed in plastic bags or body bags that may be used in a scanner and therefore can be prepared and sealed prior to entering the clinic or scanner area.

The basic rule is transport in one or more bags and examine in a triple bag. The following is an ideal situation, modify as needed:

Place the clean animal in a clear or translucent, thick plastic bag with disposable diapers or other absorbent material and seal the bag securely with nonmetallic tape or ties. Then place it in a second sealed bag for transport, again placing some absorbent material between the bags. If available, place the double-bagged animal in a body bag or other sturdy container, with sealed icepacks surrounding the animal, for transport. The main idea is to keep the animal cool and to avoid leaks from the inner or outer bags. Loose ice should be avoided so that pooling does not occur that will interfere with MRI and make the specimen harder to handle. Tear-resistant paper bags, sometimes called Grainger bags, are also available from some industrial suppliers and may be used for MRI. Be sure to check, however, that they do not contain any ferrous staples or other metallic elements.

As noted previously, it is recommended that an arrival time be agreed upon, and, if it is a clinical facility, that entrance location and access to a transport gurney or cart be arranged in advance. It may also be advisable to alert the security services in larger hospitals to arrange parking for any large transport vehicles. It is also helpful to assure the facility that you are aware of the need for proper containment of the specimen and for consideration of their patients.

c. Prepare the animal for placement on the imaging table and for examination.

In general, the animal can be examined inside the double bagging. Some body bags have nonmetal zippers that do not interfere with either CT or MRI and therefore will not have to be removed. In most cases, however, the animal will have to be removed from the outer packaging, but can be left in the two plastic bags. It is advisable to have clean bags to use at the scanner if needed. If performing MRI, the absorbent materials

may need to be removed to reduce artifact; therefore, come prepared also with gloves and trash bags to handle waste removal and to minimize odor.

Scanning and Imaging Protocols:

The following procedural outlines apply to imaging both live and postmortem material for most odontocetes, pinnipeds, and extracted mysticete and sirenian tissues. Longer sequences and higher ×-ray dosages are, of course, possible in postmortem or extracted tissues. Whenever time and costs allow, multiple sequences for different tissue types should be employed for optimizing images, particularly of the head areas or ears.

Plain-Film Radiography

Exposures depend heavily on the thickness of the area being imaged and the relative densities of material within the image field. In the absence of prior experience with marine mammals, it is recommended that, for small to medium animals, an initial image be obtained using parameters for human abdomen or for large dogs if imaging is being done in a veterinary facility. For large marine mammals, substantially greater voltages and times will be required for the head and lower abdominal regions. Projections to employ are as follows:

- Head—dorsal-ventral and oblique, orbit to occiput; lateral for skull base trauma
- Thorax—dorsal-ventral
- Abdomen—dorsal-ventral and lateral for genitourinary track and for any suspicious areas.

CT

Scouts should be obtained to cover the regions of interest in as few sequences as possible. Transaxial scans should be obtained using a spiral-scan protocol, particularly for live animals, and images should be formatted in both soft and bone windows. Rapid reconstruction images obtained during scanning can be used to determine whether the proper areas and detail were obtained; the animal can then be removed from the scan area while full resolution 2-D and 3-D images are produced and reviewed.

The following values should be considered as general suggestions and modified as necessary to provide best image

quality. More than one spiral set may be required to cover the entire body. Overlap sequential spiral sets by one full section. The following are suggested values for image slice thickness for proper diagnostic surveys of each region:

- Head:
  - 3 mm increments through the entire head
  - 3 mm feed (pitch of 1)
  - 1 to 1.5 sec rotation time
  - 180 mAs, 120 kV
  - Bone reconstruction: 1 to 3 mm U90s, w4000 c1000
  - Soft-tissue reconstruction: 1 to 3 mm H30 or H40, w500 c50
- Brain: 1 mm increments, reconstructed as for soft tissue
- Ears:
  - 0.5 mm slice increments
  - 0.5 mm feed (pitch of 1)
  - 1.0 sec rotation time
  - 180 mAs, 120 kV
  - Bone reconstruction: 0.1 to 0.3 mm U90s, w4000 c1000, smallest FOV (field of view) possible
- Thorax and abdomen:
  - 3–5 mm increments through the entire head
  - 5 mm feed
  - 1 to 1.5 sec rotation time
  - 180 mAs, 120 kV
  - Bone reconstruction: 1 to 3 mm U90s, w4000 c1000
- Soft-tissue reconstruction: 1 to 3 mm H30 or H40, w500 c50
- Lung image reconstruction:

If available, use specialized lung kernel or reconstruct with windows near +1200 and centers near –200.

If 180 eff mAs is not available, request exposures to produce ~160 mAs. Lower voltages may decrease image quality, particularly in odontocetes, and increase artifacts in the images, especially in sections with dense bony elements. In addition to the image parameters noted previously, which are typical for

odontocetes, the following values should be tried to optimize imaging of any animal:

- Bone window reconstructions:
  - High-resolution 80-95 kernel, w 2800 to 4000; c 600 to 1000
- Soft-tissue reconstructions:
  - Mid to soft tissue 30–40 kernel, w 200 to 500; c 50 to 150
- Lung reconstruction:
  - Mid tissue 50 kernel, w 1000 to 1500; c –100 to –500

Note: If any tissues are extracted and fixed for further examination it is recommended that they be rescanned as isolated tissues prior to further dissection or histologic processing in order to optimize imaging of the substructure of the tissues of interest. The same parameters as listed previously apply, but the field smallest FOV possible (generally one-tenth the maximum image field) that will encompass the specimen should be used.

MRI

MRI is recommended for the head if brain lesions or hemorrhage are suspected and for suspected abdominal lesions. If there is suspicion of metallic fragments or contaminants present in the animal, MRI should not be attempted, regardless of whether the exam is on live or dead tissue. Injury to a live animal or attending personnel or to the equipment can occur if ferrous material is present in the magnetic field. Any specimen larger than 80 cm in circumference cannot be imaged in most MRI units. To optimize imaging of the brain, head coils if available should be used. In some cases, larger coils may be available by special order from the scanner manufacturer but may require a special purchase.

Before scanning the head, particularly if it is large and the brain images are the focus of the exam, the blubber, nuchal fat, and semispinalis muscle may need to be removed to decrease the circumference to fit into the head coil. If possible, scan the head outside the plastic bag and in a Grainger bag as noted previously, but be certain to provide a waterproof table cover and to avoid contamination of the head coil. Excess fluid inside the bag and/or pooling around the head can cause signal artifacts, so it is

important to remove standing liquid prior to scanning. Rapid reconstruction images obtained just after the acquisitions are complete can be used to determine whether the proper areas and detail were obtained; the animal or specimen can then be removed from the scan area while full resolution 2-D and 3-D images are produced and reviewed.

The following values should be considered as general suggestions and modified as necessary to provide best image quality. A scout should be completed to ensure that the entire region of interest—e.g., the brain or lungs—will be captured in the planned MRI scan sequence. Initial images should be acquired, at a minimum, in the sagittal and coronal planes. The following are suggested values for image-slice thickness for proper diagnostic surveys of the brain:

- Two-dimensional proton density (PD) and T2-weighted images acquired using a fast spin-echo sequence
- Parameters:
  - TE = 15/106 ms for PD and T2, respectively
  - TR = 8000 to 9000 ms
  - slice thickness = 2 mm
  - flip angle = 180°
  - FOV = 240 × 240 mm
  - matrix = 256 × 256
  - voxel size = 0.9 × 0.9 × 2.0 mm

For thorax and abdomen, similar acquisitions may be used, but slice thickness may be increased to 5–8 mm, and the field of view (FOV) and voxel size increased as necessary.

Viewing, Copying, Exporting, and Archiving Images and Exam Data

Plain film radiographs may be printed on ×-ray film; in larger facilities, they are now available as on-screen, digital images in the same formats as MRI and CT images. The digital-image form most commonly encountered is a DICOM format. DICOM stands for digital imaging and communications in medicine, and is a standard developed by the American College of Radiology Manufacturers Association to define the connectivity and communication protocols of medical imaging devices. It is the current, open architecture standard for

biomedical images. CT and MR images in both 2-D and 3-D reconstructions are now generally exportable directly from the scanner as DICOM copies on CD or magneto-optical disks and as hard-copies on film. In some cases, TIFF or JPG formats may also be available for export or available through post-processing at the facility or through third-party software now available for both Mac and Windows computer platforms. Some of these programs will work to a limited degree with the standard RAM in most computers; in general. however, 1 GB or more is recommended for full functionality of these programs.

It is strongly recommended that, at a minimum, all images produced during an exam be archived in DICOM formats by the facility onto CDs, external hard drive, and magneto-optical disks at the imaging facility. At present, there is no common archive for marine mammal images, but several have been proposed and may become available in the near future. Raw-scan data are not usually retained or archived by the original scan facility, but it is highly recommended that raw data copies be requested in addition to the image files for all significant cases and particularly for all research or legal cases. The raw-scan data are critical for any reformats, data-based magnifications, or accurate HU analyses that may be required at a future date. Some facilities may be unable to archive raw data or may charge additional costs for this archiving.

Interpretation of Images

Radiographic, CT, and MR images should be interpreted by a veterinary radiologist or other professional who specializes in specific anatomical structures (e.g., head and neck trauma, ears, brain, airways, lungs, abdomen, extremities, genitor-urinary). We advise avoiding any interpretation without specific training or consultation because many conditions will produce similar grayscale appearances, and the proper interpretation depends heavily on a comprehensive, integrated analysis of multiple features, including shape, position, attenuation characteristics, and HU values. In addition, marine mammal anatomy is sufficiently different from that of humans and most common veterinary cases that even well-trained conventional radiologists may find these images challenging.

In following text, we provide contact information for a list of individuals who have extensive experience in interpreting marine mammal radiographs. The listings of these individuals is an

unsolicited recommendation by the authors of this manual and does not indicate an agreement for consultation by any of the listed individuals.

- Dr. Darlene Ketten, Woods Hole Oceanographic Institution, Woods Hole, MA, (508) 289-2731, dketten@whoi.edu

  Head and ear structures, lungs
  Blast trauma, fractures, bone lesions
  Image processing, 3-D reconstructions

- Dr. Eric Montie, Woods Hole Oceanographic Institution, Woods Hole, MA, (508) 289-3501, emontie@whoi.edu

  Brain, volume analyses
  Anthropogenic chemicals, biotoxins, parasites
  Image processing, 3-D reconstructions, measurements of brain regions

- Dr. Lori Marino, Neuroscience and Behavioral Biology Program, Emory University, Atlanta, GA, (404) 727-7582, lmarino@emory.edu

  Brain, volume analyses

- Dr. Sam Ridgway, Department of Pathology, University of California, San Diego, CA, (858) 534-0455, ridgway@spawar.navy.mil

  Brain Pathologies

- Dr. Ted Cranford, Department of Biology, San Diego State University, San Diego, CA, tcranfor@mail.sdsu.edu

  Airways and Melon

- Dr. Joy Reidenberg, Mount Sinai School of Medicine, New York City, NY, (212) 241-7563, joy.reidenberg@mssm.edu

  Larynx, airways

- Dr. Frank Fish, Department of Biology, West Chester University, West Chester, PA, (610) 436-2460, ffish@wcupa.edu

  Limb and propulsive structures

Data Analysis

Sectional anatomy imaging (CT and MRI) offers many advantages. It creates a permanent archive of images of anatomical structures, without the disruption of dissection, and allows us to view rapidly the anatomy of freshly dead, stranded specimens at a much finer scale. CT and MR images also allow us to produce three-dimensional models of anatomical structures to examine spatial relationships and provide accurate volumetric details. Furthermore, the images can be used to guide dissections for sampling smaller pathologies that may have been missed in conventional necropsy.

CT and MRI Scans Completed in Cetaceans

Appendices 4-1 and 4-2 list species for which CT or MRI scans have been completed at WHOI and for which images are available for review by researchers or veterinarians. Access to these images can be obtained via the WHOI CSI website (http://www.whoi.edu/csi). Numbers in the tables reflect tissue scan sets, not numbers of individual animals. In some cases, multiple tissues from one animal or multiple protocol scan sets were obtained from one tissue. Many other examples may be available through other laboratories or other facilities, and we encourage the formation of a centralized data base and the exchange of cross-listings of available image data sets.

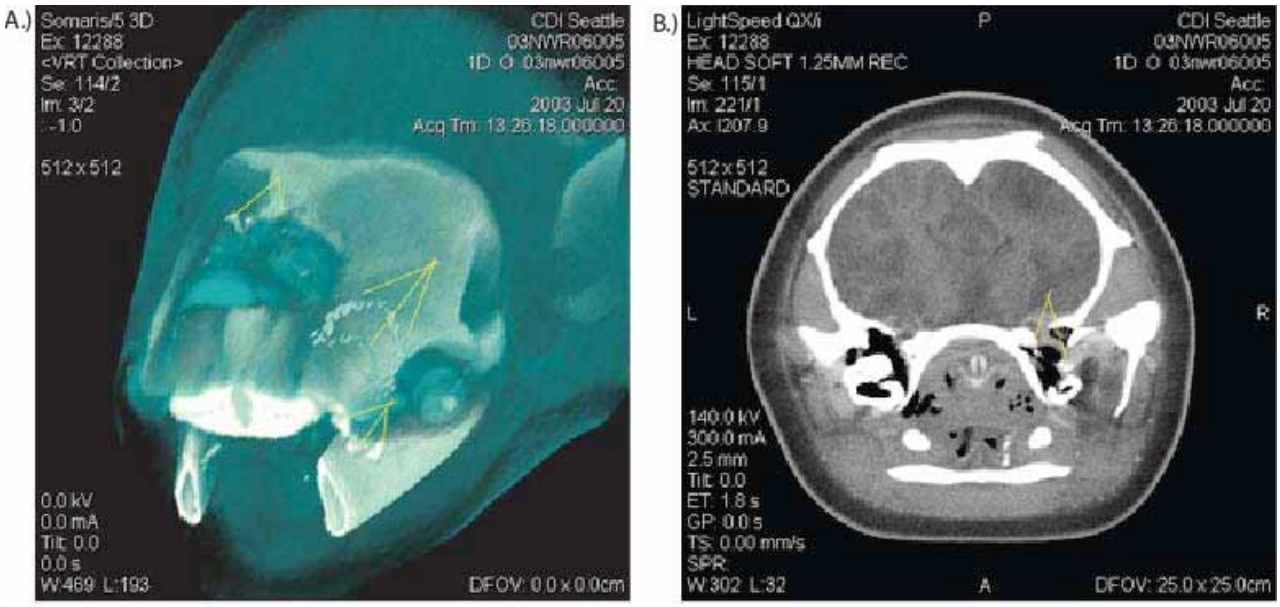

Figure 4.3. CT scans of a harbor porpoise with calcified parasites. Left: A 3-D reconstruction of the midregion of the head shows multiple extensive calcified parasites (white tracks, yellow arrows) that were located near the right eye and extended over the melon. Right: A 2-D transaxial image at the level of the ears shows a peribullar soft tissue mass with small calcified inclusions that represent a group of nematodes and calcified cysts,(yellow arrows). Additional cysts are evident as bright white inclusions in the tissues on the right of the esophagus. Parasites are a common finding in this species in the middle ear and retrobullar sinuses, but the extensive calcified tracks are an unusual finding. (Images copyright D. Ketten, 2005)

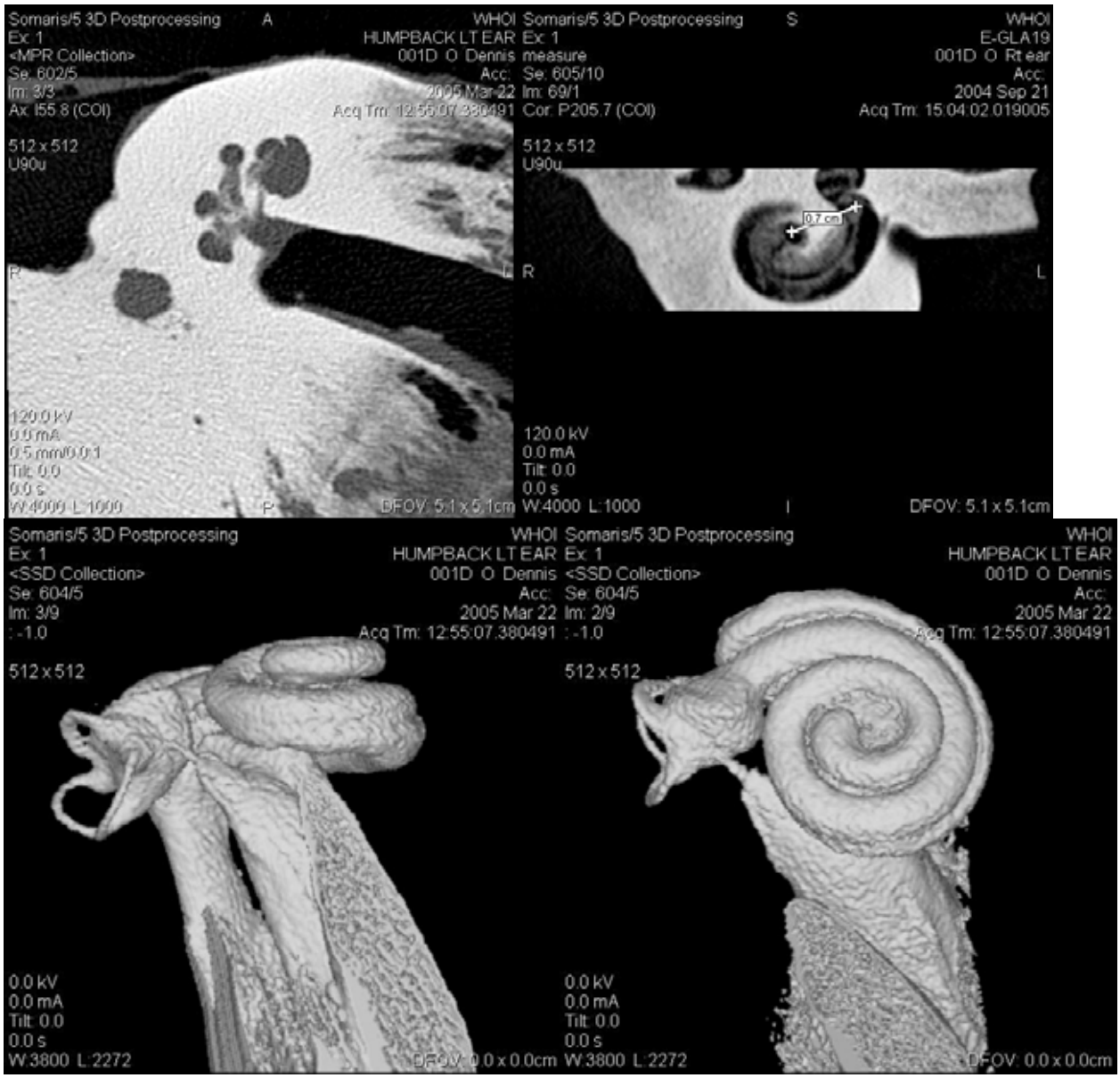

Figure 4.3. Mysticete Inner Ears. 2-D CT images (top) show mid-modiolar and coronal views of the inner ear of a right whale *(Eubalaena glacialis)* that illustrate the number of turns (left) as well as soft tissue neural tracts (right). 3-D images of a humpback whale ear *(Megaptera novaengliae)* in similar orientations show the dimensions and angular relationship of the vestibular canals and the cochlear canal. (Images copyright D. Ketten, 2004)

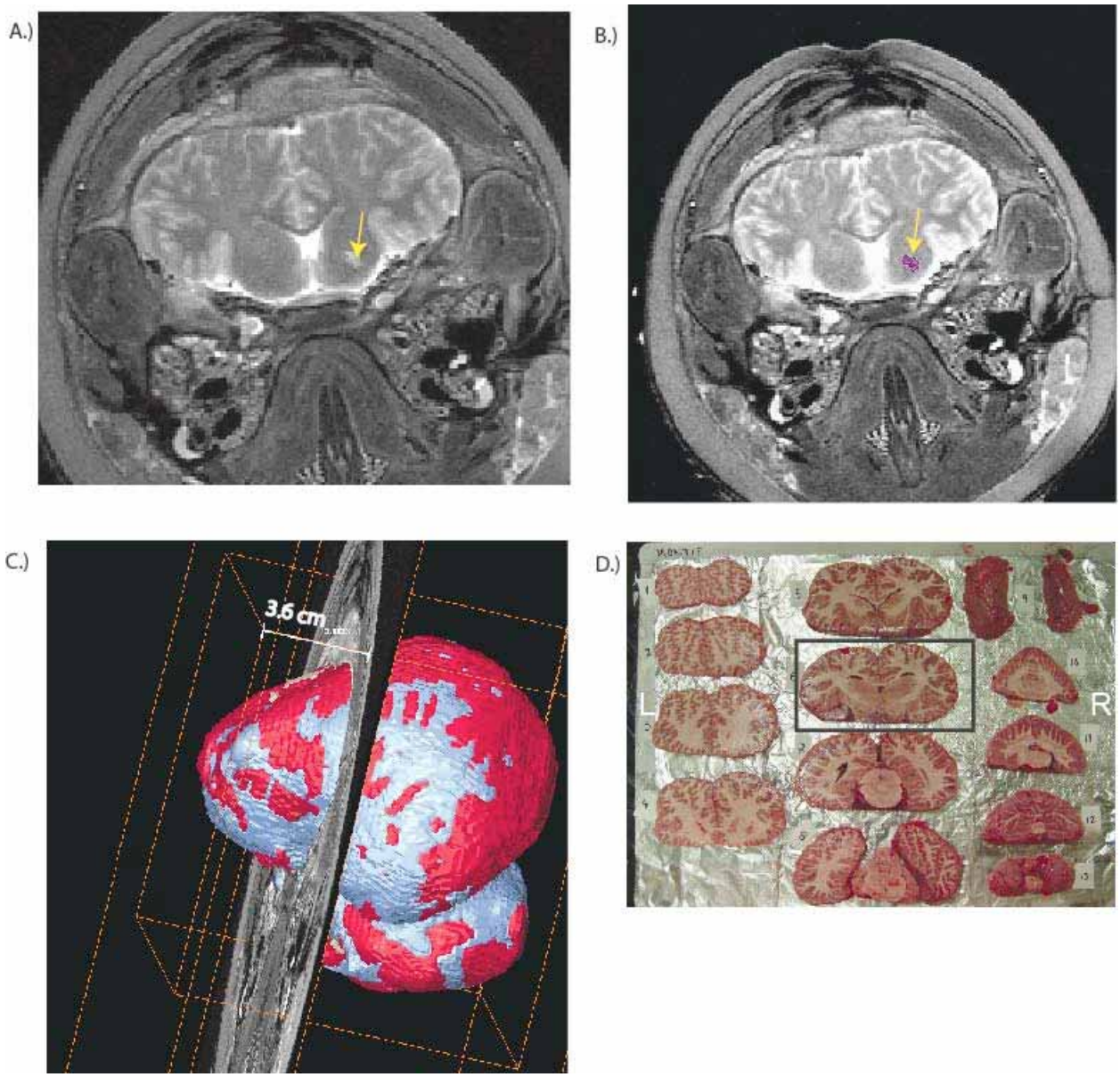

Figure 4.4. 3-D models of the brain in conjunction with virtual reconstructions of lesions as a guide to small lesions. A.) The brain lesion in this Atlantic white-sided dolphin (indicated by the yellow arrow) was identified by MR imaging. B.) A 3-D model of the brain was constructed to measure the distance of the lesion (purple) from the anterior boundary of the frontal lobe (3.6 cm). C.) Red = gray matter; blue = cerebrospinal fluid. This distance was measured on the gross brain to find the lesion. D.) The black rectangle indicates the brain section that contained the lesion. (Images copyright E. Montie, 2006)

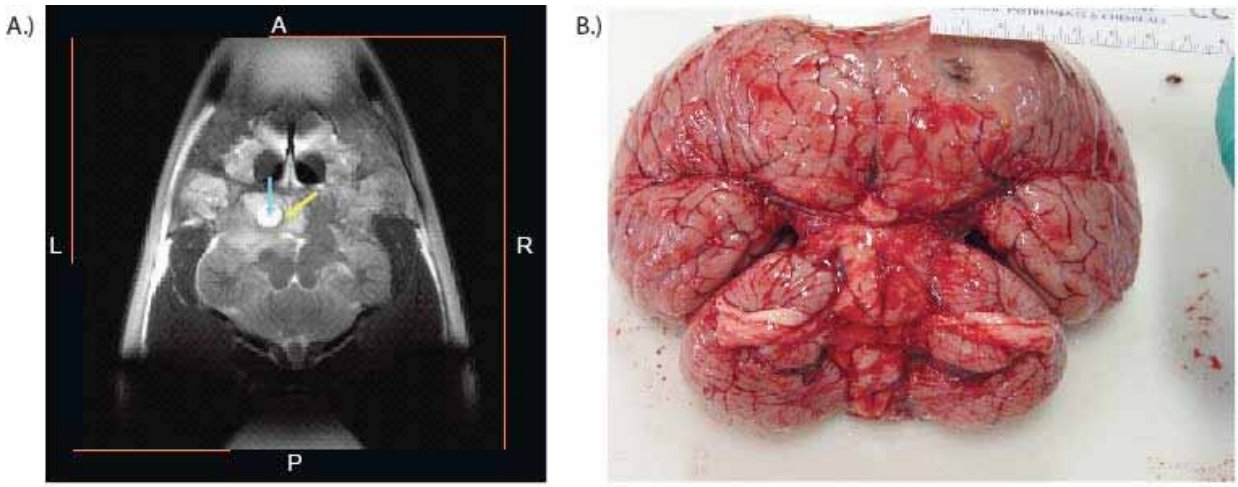

Figure 4.5. Brain lesion in CCSN04-177-Dd common dolphin. A.) The MR image indicated a 2 cm spherical abscess identified in the left frontal lobe. A halo of damaged tissue is noted by the yellow arrow. A fluid-filled necrotic core is indicated by the turquoise arrow. B) The lesion was revealed during the dissection. Brain removal revealed pus in the left frontal lobe. (Images copyright E. Montie, 2006).

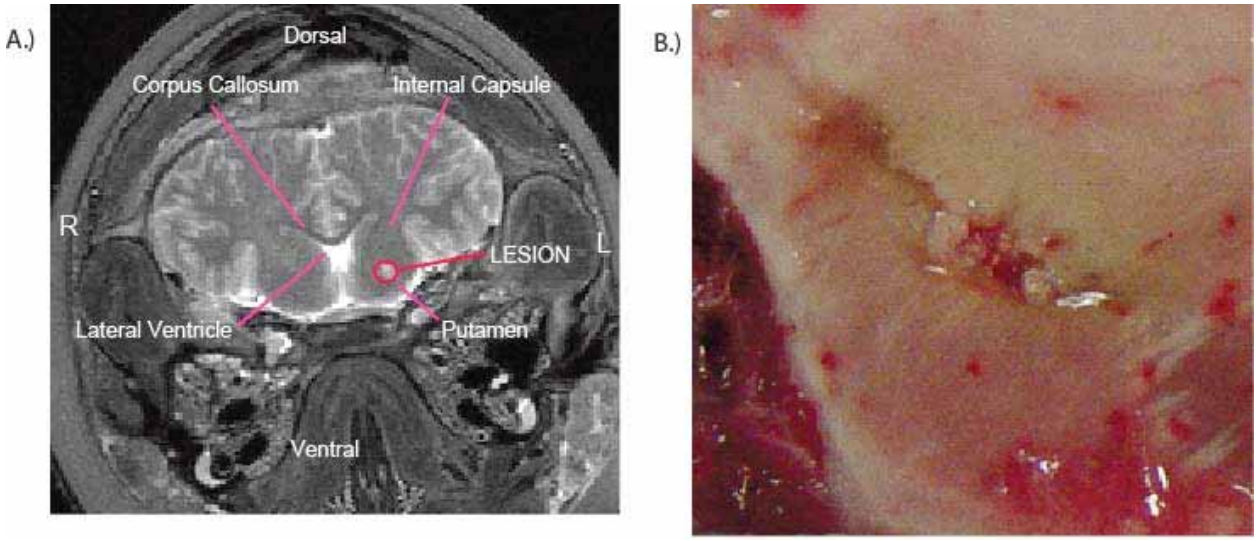

Figure 4.6. Brain lesion in CCSN04-191-Dd common dolphin. A.) The MR image indicated a small lesion in the region of the putamen and globus pallidus or, collectively termed, the lentiform nucleus. B.) The lesion was revealed during the dissection. (Images copyright E. Montie, 2006.)

Appendix 4.1
CT Scans and Archived Images of Cetaceans

WHOI COMPUTERIZED SCANNING AND IMAGING CENTER (WWW.WHOI.EDU/CSI)

Classification	Scientific Name	Common Name	Scan Sets
Fissipedia	*Enhydra lutris*	sea otter	8
Mysteceti	*Balaenoptera acutorostrata*	Minke whale	9
Mysteceti	*Balaenoptera musculus*	blue whale	2
Mysteceti	*Balaenoptera physalus*	fin whale	1
Mysteceti	*Eubalaena glacialis*	right whale	24
Mysticeti	*Eschrichtius robustus*	gray whale	4
Mysticeti	*Megaptera novaeanglia*	humpback whale	9
Odontoceti	*Cephalorhynchus hectori*	Hector's dolphin	1
Odontoceti	*Delphinus delphis*	common dolphin	34
Odontoceti	*Tursiops truncatus*	bottlenose dolphin	65
Odontoceti	*Phocoena phocoena*	harbor porpoise	75
Odontoceti	*Delphinapterus leucas*	beluga whale	4
Odontoceti	*Feresa attenuata*	pygmy killer whale	1
Odontoceti	*Grampus griseus*	Risso's dolphin	18
Odontoceti	*Globicephela macrorhyncus*	short-finned pilot whale	34
Odontoceti	*Globicephala malaena*	long-finned pilot whale	12
Odontoceti	*Kogia breviceps*	pygmy sperm whale	22
Odontoceti	*Kogia simus*	dwarf sperm whale	6
Odontoceti	*Lagenorhynchus acutus*	Atlantic white-sided dolphin	39
Odontoceti	*Lagenorhynchus albirostris*	White-beaked dolphin	3
Odontoceti	*Mesoplodon bidens*	Sowerby's beaked whale	13
Odontoceti	*Mesoplodon densirostris*	Blainville's beaked whale	6
Odontoceti	*Mesoplodon europaeus*	Gervais' beaked whale	9
Odontoceti	*Mesoplodon mirus*	True's beaked whale	1
Odontoceti	*Mesoplodon sp.*	beaked whale	3
Odontoceti	*Monodon monoceros*	narwhal	4

Classification	Scientific Name	Common Name	Scan Sets
Odontoceti	*Physeter catadon*	sperm whale	15
Odontoceti	*Peponocephala electra*	melon-headed whale	1
Odontoceti	*Stenella attenuata*	pantropical spotted dolphin	4
Odontoceti	*Steno bredanensis*	rough-toothed dolphin	3
Odontoceti	*Stenella clymene*	Clymene dolphin	1
Odontoceti	*Stenella coeruleoalba*	striped dolphin	6
Odontoceti	*Stenella frontalis*	Atlantic spotted dolphin	1
Odontoceti	*Stenella longirostris*	spinner dolphin	1
Odontoceti	*Ziphius cavirostris*	Cuvier's beaked whale	9

Appendix 4.2
Cetacean Brain MRIs (for access contact E. Montie)

Field ID	Species	Common Name	Sex	Length
CCSN04-177-Dd	*Delphinus delphis*	common dolphin	m	209
CCSN04-195-La	*Lagenorhynchus acutus*	Atlantic white-sided dolphin	m	192
CCSN04-217-Dd	*Delphinus delphis*	common dolphin	f	210
CCSN04-218-Dd	*Delphinus delphis*	common dolphin	m	139
CCSN04-219-Dd	*Delphinus delphis*	common dolphin	f	169
CCSN05-014-Dd	*Delphinus delphis*	common dolphin	f	205
CCSN05-014-Fetus-Dd	*Delphinus delphis*	common dolphin	m	41
CCSN05-037-La	*Lagenorhynchus acutus*	Atlantic white-sided dolphin	f	206
CCSN05-038-La	*Lagenorhynchus acutus*	Atlantic white-sided dolphin	f	208
CCSN05-039-La	*Lagenorhynchus acutus*	Atlantic white-sided dolphin	f	211
CCSN05-039-Fetus-La	*Lagenorhynchus acutus*	Atlantic white-sided dolphin	m	44
CCSN05-040-La	*Lagenorhynchus acutus*	Atlantic white-sided dolphin	f	204
CCSN05-040-Fetus-La	*Lagenorhynchus acutus*	Atlantic white-sided dolphin	m	54
CCSN05-084-La	*Lagenorhynchus acutus*	Atlantic white-sided dolphin	m	156
CCSN05-231-La	*Lagenorhynchus acutus*	Atlantic white-sided dolphin	f	137
CCSN05-232-La	*Lagenorhynchus acutus*	Atlantic white-sided dolphin	f	185.5
CCSN05-236-Dd	*Delphinus delphis*	common dolphin	m	179
CCSN05-237-Dd	*Delphinus delphis*	common dolphin	m	166